

Case Report

Direct percutaneous endoscopic jejunostomy performed with gastroscop

Ajay P. Choksi, Keyur C. Shah¹, Harshad K. Parekh²

Departments of Gastroenterology, ¹Neurology and ²Neurosurgery, Dr. Balabhai Nanavati Hospital, Mumbai, Maharashtra, India

Abstract

While percutaneous endoscopic gastrostomy (PEG) is a well-known approach for achieving enteral feeding, direct percutaneous endoscopic jejunostomy (DPEJ) is a technique that allows endoscopic placement of percutaneous/transabdominal feeding tube directly into the jejunum. It offers a non-surgical alternative for postpyloric enteral feeding for long-term nutritional support when gastric feeding is not technically possible or is inappropriate. Conventionally DPEJ is done with pediatric colonoscope or small bowel enteroscope. Here, we report a case where DPEJ was accomplished with gastroscop.

Key words

Direct percutaneous endoscopic jejunostomy, gastroscopic jejunal intubation, jejunostomy, percutaneous endoscopic gastrostomy alternative, percutaneous endoscopic gastrostomy failure

Introduction

Percutaneous endoscopic gastrostomy (PEG) has evolved as a safe, effective, and reliable method for achieving enteral feeding. However, it may not be feasible for patients with severe gastroparesis, gastric outlet obstruction, gastric resection, or who cannot tolerate gastric feeding. For these patients, postpyloric enteral feeding can be accomplished by direct percutaneous endoscopic jejunostomy (DPEJ). It involves the insertion of a feeding tube directly into the jejunum. It has emerged as a non-surgical method for postpyloric enteral nutrition for long-term management of nutrition. It was first described by Shike *et al.*, in 1985, and thereafter, a number of centers have shown it to be a safe, reliable, and feasible approach to gain access to the jejunum for feeding.^[1-3]

Conventionally DPEJ is performed using a pediatric colonoscope or enteroscope. We report a case where DPEJ was performed in a patient with conventional gastroscop.

Case Report

A 32-year-old, 180-cm tall [Figure 1] male who was in coma was referred for placement of PEG. He had suffered from intracerebral bleed, for which he underwent ventriculoperitoneal shunt and was receiving feeding via a nasogastric tube for 3 months before referral. Patient had no other comorbidity and was otherwise healthy.

At our hospital, we initially attempted to insert PEG with Olympus GIF H180 gastroscop, but it failed because optimal transillumination and finger indentation could not be obtained

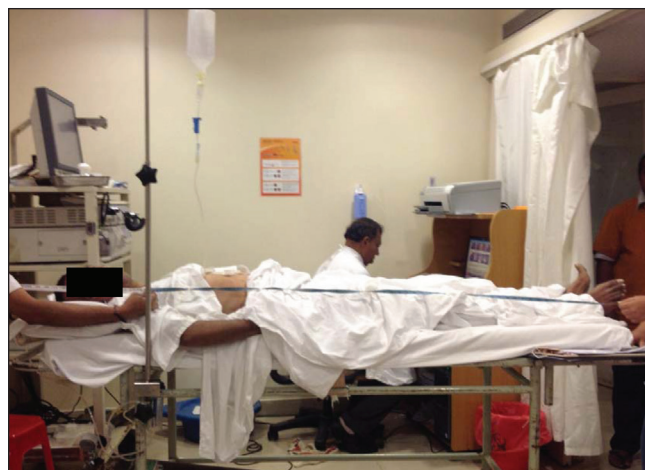

Figure 1: A 6-ft tall patient

Access this article online

Website:

www.jdeonline.in

DOI:

10.4103/0976-5042.129986

Quick Response Code



Address for correspondence:

Dr. Ajay P. Choksi, C-1, Hira Manek, 48/D, Baptista Road, Vile Parle (W), Mumbai- 400 056, Maharashtra, India. E-mail: drajaychoksi@gmail.com

in stomach on repeated attempts. Hence, during the same procedure, the gastroscope tip was advanced beyond the duodeno-jejunal (D-J) flexure (without fluoroscopy guidance). After confirming good transillumination and finger indentation in the jejunum, DPEJ was performed with conventional “pull technique”^[3] using a 24 Fr PEG set available with Boston Scientific Corporation, USA [Figure 2].

After 20 months, the DPEJ tube was pulled out accidentally, and after about 24 h, the patient was brought to the hospital. Stoma had closed by the time the patient was brought to the hospital. Similar problems were encountered while attempting PEG with Olympus GIF H180 gastroscope on the following day as in the initial attempt, i.e. failure to obtain optimum transillumination and finger indentation in the stomach. During the same procedure with Olympus GIF H180 gastroscope, DPEJ was accomplished again by the conventional pull technique and a new cutaneous puncture [Figure 3].

Discussion

Conventionally, DPEJ is done with pediatric colonoscope or enteroscope.^[1-3] Pediatric colonoscope and enteroscope may not be available in majority of endoscopy centers. Conventional gastroscope can most often be advanced beyond the D-J flexure.^[4,5] The present case demonstrates that DPEJ could be accomplished with conventional gastroscope in a 6-ft tall individual without surgically altered upper gastrointestinal (GI) anatomy (viz. esophagectomy, gastrectomy, gastrojejunostomy, etc.) or spinal deformity. Feeding port insertion could be accomplished during the same intubation. DPEJ can be done even if pediatric colonoscope or enteroscope is not available with the endoscopist. However, the most important prerequisite for PEG and DPEJ insertion is demonstration of clear-cut transillumination and finger

indentation for safe placement of the feeding tube.

For deeper intubation of the small intestine, endoscopes with longer insertion tubes, viz. colonoscope and enteroscope, appear to have obvious advantages. However, distensibility of the stomach, especially fundus and greater curvature, necessitates “short-scope-position” along the lesser curvature, as has been well described and emphasized for achieving deeper intubation into the second part of duodenum during endoscopic retrograde cholangiopancreatography (ERCP). In short-scope-position, the ampulla of Vater is seen at a scope length of 60–70 cm from the incisors. Thus, 100 cm length of the gastroscope should be enough to reach the proximal jejunum, provided short-scope-position in the stomach is maintained. So, to advance the gastroscope beyond the D-J flexure, one needs to shorten the gastroscope in proximal D₂, whereby, most often, its tip plunges into distal D₂ (not unlike shortening “N” loop or alpha-loop of colonoscope at the descending–sigmoid colon junction or as shortening of the duodenoscope during ERCP with the tip just beyond the superior duodenal angle). During further advancement beyond distal D₂, tip of the gastroscope should be deflected mainly left +/- slightly down or sometimes down with clockwise torque on the shaft. Up or right deflection of the tip works against (exactly opposite of the preferred tip deflection of colonoscope at sigmoid–descending colon junction or tip deflection at superior duodenal angle for duodenoscope or gastroscope). Initial experience did suggest that endoscope with down angulation up to 180° may have inherent advantages for deeper intubation.^[5] Over the years, it has been observed that even if the down angulation of the gastroscope is up to 120°, it can be easily advanced beyond the D-J flexure. Colonoscope with an outer diameter of 12.4 mm or more is certainly a bit too bulky and cumbersome to negotiate from patient’s oral cavity, while gastroscope with an outer diameter of 9.8 mm or less can do the same job.

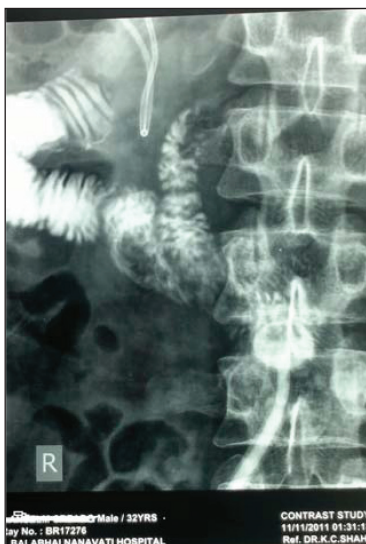

Figure 2: Contrast study of DPEJ done on 11/11/2011

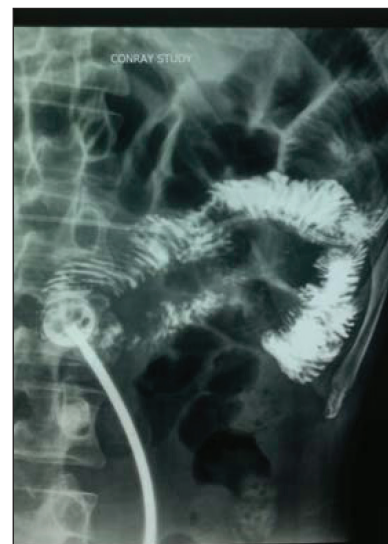

Figure 3: Contrast study of repeat DPEJ done on 14/06/2013

Conclusion

To conclude, DPEJ can be performed with gastroscop even in tall individuals without surgically altered upper GI anatomy.

References

1. Zhu Y, Shi L, Tang H, Tao G. Current considerations in direct percutaneous endoscopic jejunostomy. *Can J Gastroenterol* 2012;26:92-6.
2. Del Piano M, Bellare M, Carmagnola S, Orsello M, Garello E, Pagliarulo M, *et al.* DPEJ placement in cases of PEG insertion failure. *Dig Liv Dis* 2008;40:140-3.
3. Jonnalagadda S, Edmundowicz SA. Percutaneous endoscopic

gastrostomy & jejunostomy. In: Classen M, Lightdale CJ, Tytgat GN, editors. *Gastroenterological endoscopy*. New York: Thieme Stuttgart; 2010. p. 466-71.

4. Choksi AP. One more new technique of jejunal feeding tube insertion. *Indian J Gastroenterol* 2003;22 Suppl 1:A123.
5. Choksi AP. Do esophagogastroduodenojejunoscopy instead of esophagogastroduodenoscopy. *Indian J Gastroenterol* 2003;22 Suppl 1:A118.

How to cite this article: Choksi AP, Shah KC, Parekh HK. Direct percutaneous endoscopic jejunostomy performed with gastroscop. *J Dig Endosc* 2013;4:90-2.

Source of Support: Nil, **Conflict of Interest:** None declared.

New features on the journal's website

Optimized content for mobile and hand-held devices

HTML pages have been optimized of mobile and other hand-held devices (such as iPad, Kindle, iPod) for faster browsing speed.

Click on [**Mobile Full text**] from Table of Contents page.

This is simple HTML version for faster download on mobiles (if viewed on desktop, it will be automatically redirected to full HTML version)

E-Pub for hand-held devices

EPUB is an open e-book standard recommended by The International Digital Publishing Forum which is designed for reflowable content i.e. the text display can be optimized for a particular display device.


Click on [**EPub**] from Table of Contents page.

There are various e-Pub readers such as for Windows: Digital Editions, OS X: Calibre/Bookworm, iPhone/iPod Touch/iPad: Stanza, and Linux: Calibre/Bookworm.

E-Book for desktop

One can also see the entire issue as printed here in a 'flip book' version on desktops.

Links are available from Current Issue as well as Archives pages.

Click on  View as eBook