

Herpetic esophagitis: An uncommon cause of dysphagia

Rinkesh K. Bansal, Piyush Ranjan

Department of Gastroenterology, Sir Ganga Ram Hospital, New Delhi, India

Abstract

Herpes simplex esophagitis usually occurs in immune-compromised patients. We report a case of 44 year-old lady without any immune deficient state, who presented with dysphagia and retrosternal pain. Upper GI endoscopy revealed multiple punched out ulcers in esophagus. Biopsy from these ulcers revealed intranuclear eosinophilic inclusion bodies and multinucleated epithelial giant cells suggestive of herpetic esophagitis. Serum HSV-1 IgM antibodies was positive. Dysphagia improved on treatment with acyclovir.

Key words

Esophageal ulcers, herpes esophagitis, infectious esophagitis

Introduction

Infectious esophagitis like *Candida*, herpes simplex virus type 1 (HSV-1) and cytomegalovirus (CMV) can cause dysphagia. Out of these, *Candida* esophagitis is most common. Herpetic esophagitis is very rare and has been reported in immunocompromised patients.^[1] We report a case of dysphagia in middle-aged immunocompetent female.

Case Report

A 44-year-old lady presented with dysphagia for both solids and liquids for 10 days. She also complained of retrosternal pain. There was no history of antecedent reflux. She was nondiabetic, and there was no history of any analgesic or antibiotic intake recently. She had undergone colectomy 2 years back for ulcerative colitis and was not on any immunosuppressive therapy since then. Her physical examination was normal except mild pallor.

She underwent upper gastrointestinal endoscopy which showed multiple punched out ulcers in esophagus starting from

25 cm from incisors and extending up to gastro-esophageal junction [Figure 1]. Biopsy from these ulcers revealed intranuclear eosinophilic inclusion bodies and multinucleated epithelial giant cells [Figure 2]. Subsequently, serum HSV-1 IgM and IgG were sent and were positive. She was treated with intravenous acyclovir initially for 5 days and was switched to oral acyclovir that was given for 7 days. Her symptoms started improving after 5 days, and she started complete oral intake by then. Repeat endoscopy after 2 weeks was normal.


Discussion

Herpetic esophagitis is uncommon and occurs predominantly in immunocompromised individuals such as those on chemotherapy, organ transplant recipients (solid organ and bone marrow) and patients with human immunodeficiency virus infection. HSV esophagitis rarely affects immunocompetent patients.^[1] Our patient was not on any immunosuppressive therapy and had no secondary immunodeficiency.

Esophageal involvement occurs by contact of HSV in saliva.^[2] Common clinical manifestations of HSV esophagitis are odynophagia (60.7%), fever (51.8%), and retrosternal chest pain (46.4%).^[1] The duration of symptoms is usually <2 weeks.

Characteristic endoscopic findings of HSV esophagitis are small, oval, punched out ulcers with shallow geographic coverage.^[3] Malignancy, radiation therapy, steroid intake, CMV infection, Tuberculosis and acquired immune deficiency syndrome can present with similar endoscopic appearance. CMV esophagitis is the closest endoscopic differential

Access this article online

Website: www.jdeonline.in	Quick Response Code 
DOI: 10.4103/0976-5042.147505	

Address for correspondence:

Dr. Piyush Ranjan, Department of Gastroenterology, Sir Ganga Ram Hospital, New Delhi, India. E-mail: piyushranjan70@gmail.com

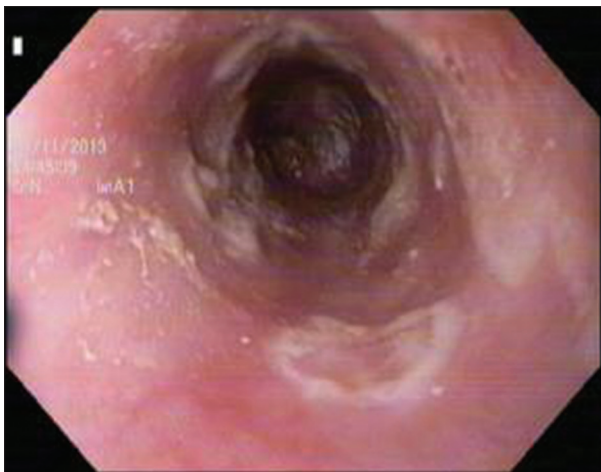

Figure 1: Endoscopic view of multiple punched out ulcers in esophagus starting from 25 cm from incisors

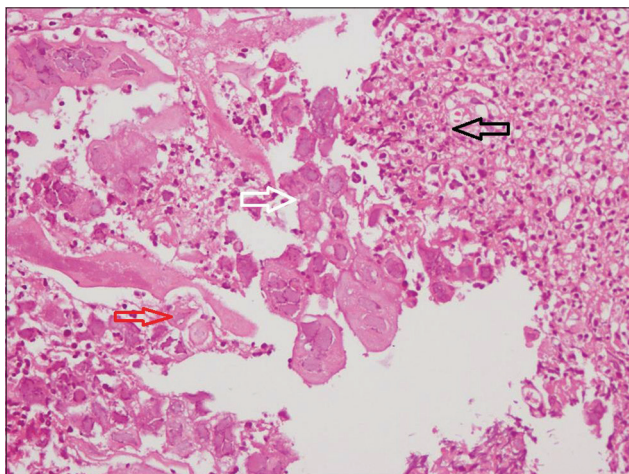


Figure 2: Biopsy from esophageal ulcer (H and E, ×40), showing intranuclear eosinophilic inclusion with perinuclear halo (white arrow) – Large multinucleated epithelial cells (red arrow) and – Ulcerated mucosa full of mixed inflammatory cells (black arrow)

diagnosis. In CMV esophagitis, large, solitary ulcers are seen especially in the distal esophagus.^[4] In this patient, the

endoscopic features were consistent with herpetic esophagitis. However given the rarity of the disease the histopathological correlation is required for diagnosis.

The pathognomonic histopathological findings are multinucleated cells with intranuclear eosinophilic inclusion bodies.^[5] Inclusions are surrounded by inflammatory cell infiltrate. Virus isolation in tissue culture and nucleic acid amplification technique is sensitive but may give false positive results from HSV colonizing oral mucosal surface. Positive serum IgM anti-HSV antibody supports the diagnosis.^[6] Acyclovir is the drug of choice, and it is to be given in the dosage of 5 mg/kg for 7–14 days.^[7]

In a patient with short duration of clinical history of dysphagia and characteristic endoscopic finding, CMV esophagitis should be suspected irrespective of immune status.

References

1. Canalejo Castrillero E, García Durán F, Cabello N, García Martínez J. Herpes esophagitis in healthy adults and adolescents: Report of 3 cases and review of the literature. *Medicine (Baltimore)* 2010;89:204-10.
2. Takeuchi N, Maeda T, Aoki R, Tanaka S, Nishida Y, Nomura Y, *et al.* A case of herpes simplex virus esophagitis. *Intern Med* 2014;S1:003.
3. Bando T, Matsushita M, Kitano M, Okazaki K. Herpes simplex esophagitis in the elderly. *Dig Endosc* 2009;21:205-7.
4. Harada N, Shimada M, Suehiro T, Soejima Y, Ninomiya M, Shiotani S, *et al.* Unusual endoscopic findings of CMV esophagitis after liver transplantation. *Hepatogastroenterology* 2005;52:1236-9.
5. Nash G, Ross JS. Herpetic esophagitis. A common cause of esophageal ulceration. *Hum Pathol* 1974;5:339-45.
6. Kato S, Yamamoto R, Yoshimitsu S, Shimazaki K, Ogawa S, Itoh K, *et al.* Herpes simplex esophagitis in the immunocompetent host. *Dis Esophagus* 2005;18:340-4.
7. Jetté-Côté I, Ouellette D, Béliveau C, Mitchell A. Total dysphagia after short course of systemic corticotherapy: Herpes simplex virus esophagitis. *World J Gastroenterol* 2013;19:5178-81.

How to cite this article: Bansal RK, Ranjan P. Herpetic esophagitis: An uncommon cause of dysphagia. *J Dig Endosc* 2014;5:119-20.

Source of Support: Nil, **Conflict of Interest:** None declared.