

# Air embolism: A rare complication of esophagogastroduodenoscopy!

Ajay B. Jhaveri, Sharad C. Shah, Prasanna S. Shah

Department of Gastroenterology, Jaslok Hospital and Research Centre, Mumbai, Maharashtra, India

## Abstract

Neurological complications of gastrointestinal endoscopy are extremely rare; cerebral air embolism has been described and can be severe and fatal. A high index of suspicion for an air embolism is a must in case of procedural or periprocedural cardiopulmonary instability and neurologic symptoms, particularly in patients with recognized risk factors. The diagnosis of an air embolism is often difficult and is complicated by the fact that air may be rapidly absorbed from the circulation. Simple maneuvers to decrease the impact of a potential air embolism include; stopping the procedure, administering high flow 100% oxygen, placing the patient in Trendelenburg and left lateral decubitus position, and discontinuing nitrous oxide. C T Scan and 2 D ECHO are important diagnostic tests.

## Key words

Air embolism, esophago-gastro-duodenoscopy, neurological complication

## Introduction

We present a case of 55-year-old female, who had a history of undergoing dilatation for distal esophageal peptic stricture approximately 3 cm in length; twice in the past (3 years ago) prior to presentation. She had no other medical and surgical co-morbidities. She presented with recurrence of dysphagia and was posted for esophagogastroduodenoscopy and underwent dilatation under deep sedation with intravenous propofol and midazolam. Patient underwent pneumatic dilatation with controlled radial expansion wire-guided balloon dilatation catheter 10-11-12 mm and dilated till a diameter of 10 mm, under fluoroscopy guidance, using room air for insufflations. Post procedure patient did not wake up after the stipulated time to come out of anesthesia. She did not respond to the painful stimulus either. She was taken for plain computed tomography (CT) scan of the brain which revealed air emboli in the right middle temporal gyrus [Figure 1].

Post procedure trans-thoracic echocardiography revealed a normal heart structure and ejection fraction. X-ray chest also was normal.

Neurological complications of gastrointestinal endoscopy are extremely rare; cerebral air embolism has been described and can be severe and fatal.<sup>[1]</sup> Risk factors for an air embolism, reported are previous interventions or surgeries of the bile duct system, trans hepatic portosystemic shunt, blunt or penetrating trauma to the liver, inflammation of the digestive system, postsurgical gastrointestinal fistula, and interventional techniques such as cholangioscopy, biliary sphincterotomy, metal stent placement, liver biopsy, insufflation of air with high pressure, excessive amount and/or increased rate of air infusion, procedural site located higher than the level of the heart, and the use of nitrous oxide.<sup>[2]</sup> Other conditions associated with an increased risk for an air embolism include inflammation of the bile duct or surrounding veins (pylephlebitis), hepatic abscesses, inflammatory bowel diseases, necrotizing enterocolitis, mesenteric ischemia, gastrointestinal tumors, and biliary atresia.<sup>[2]</sup>

A number of potential mechanisms for air entry into the venous system has been described such as intramural dissection of insufflated air into the portal vein, transection of duodenal vein radicles, biliary-venous fistulas/shunts, portocaval collaterals, air flow directly into the hepatic veins or inferior vena cava,

### Access this article online

#### Website:

www.jdeonline.in

#### DOI:

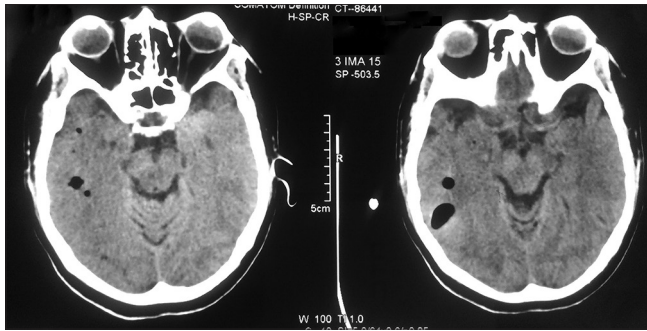
10.4103/0976-5042.147507

#### Quick Response Code



### Address for correspondence:

Dr. Ajay B. Jhaveri, Department of Endoscopy, Jaslok Hospital and Research Centre, 17<sup>th</sup> Floor, 15, Dr. G. Deshmukh Marg, Peddar Road, Mumbai - 400 026, Maharashtra, India. E-mail: drajajhaveri@gmail.com



**Figure 1:** Presence of air emboli in the right middle temporal gyrus.

retrograde flow into cerebral veins via superior vena cava, inability of the pulmonary circulation to filter out gas emboli or entry into the vertebral venous plexus.<sup>[2]</sup>

The systemic air embolism can cause cardiovascular, pulmonary, and neurological symptoms. Cardiovascular signs, symptoms, and findings include arrhythmia, hypotension, myocardial ischemia, right heart failure, cardiovascular collapse, and cardiac arrest. Pulmonary signs, symptoms, and findings include acute dyspnea, tachypnea, breathlessness, rales, wheezing, decrease in end-tidal carbon dioxide concentration, hypoxia, cyanosis, and respiratory failure. Neurological signs, symptoms, and findings include eye deviation, dilated pupil(s), failure to regain consciousness after anesthesia, hypertonicity, altered mental status, loss of consciousness, hemiparesis, cerebral hypoperfusion, cerebral edema, and coma.

The diagnosis of an air embolism is often difficult and is complicated by the fact that air may be rapidly absorbed from the circulation while diagnostic tests are being arranged. Exclusion of other life-threatening processes is generally required.<sup>[2]</sup>

Transthoracic and transesophageal echocardiography help to document the presence of air and also aid in the diagnosis of cardiac anomalies, assessment of volume status, and cardiac contractility. A high index of suspicion for an air embolism is a must in case of procedural or periprocedural cardiopulmonary instability and neurologic symptoms, particularly in patients with recognized risk factors.<sup>[2]</sup>

Since the clinical presentation of an air embolism can significantly overlap with sedation-related problems and

ischemic or hemorrhagic cerebrovascular events, some simple maneuvers to decrease the impact of a potential air embolism should be promptly initiated. These maneuvers include: Stopping the procedure if possible, administering high-flow 100% oxygen, initiating high volume normal saline infusion, placing the patient in Trendelenburg and left lateral decubitus position in order to minimize air migration to the brain and to force-out air from the right ventricular outflow tract, thereby increasing venous return, and if nitrous oxide is being used, it must be discontinued because of its ability to rapidly diffuse into the trapped air bubbles, causing an additive effect on the embolism.

Since cerebrovascular accident is most commonly suspected in patients with neurologic symptoms, an urgent head CT scan should be done. Therefore, if an air embolism is suspected, a bedside echocardiogram should be promptly performed to quickly secure the diagnosis with visualization of air within the right heart. This can have immediate therapeutic implications. An air aspiration via a central venous catheter can be done, and arrangements for urgent hyperbaric oxygenation therapy can be carried out. Hyperbaric oxygenation therapy may reduce air bubble size, accelerate nitrogen reabsorption, and increase the oxygen content of arterial blood; this potentially reduces the ischemia.<sup>[2]</sup>

Proposed hypothesis for air embolism is air entry into the vascular system via disrupted mucosa in the setting of the pressure gradient due to insufflations. Our patient succumbed after 5 days. This case report has been put forth to alert the gastroenterologists to such fatal complications, with no fault of the endoscopist!

## References

1. McAree BJ, Gilliland R, Campbell DM, Lucas JW, Dickey W. Cerebral air embolism complicating esophagogastroduodenoscopy (EGD). *Endoscopy* 2008;40 Suppl 2:E191-2.
2. Donepudi S, Chavalitdhamrong D, Pu L, Draganov PV. Air embolism complicating gastrointestinal endoscopy: A systematic review. *World J Gastrointest Endosc* 2013;5:359-65.

**How to cite this article:** Jhaveri AB, Shah SC, Shah PS. Air embolism: A rare complication of esophagogastroduodenoscopy!. *J Dig Endosc* 2014;5:114-5.  
**Source of Support:** Nil, **Conflict of Interest:** None declared.