

## Case Report

# Subacute intestinal obstruction by a giant ileal lipoma treated by endoscopic removal

Sonavane Amey, Rathi Pravin

Department of Gastroenterology, Bombay Hospital and Institute of Medical Sciences, New Marine Lines, Mumbai, Maharashtra, India

## Abstract

With the advancement in endoscopic procedures, lipomas of the terminal ileum can be treated with techniques such as snare polypectomy, endoscopic unroofing, and endoscopic submucosal dissection. A case of successful removal of an ileal lipoma causing repetitive ileocolic intussusceptions through the ileocecal valve using endoscopic snare polypectomy by cap-assisted colonoscopy was recently reported. We report a case of successful colonoscopic polypectomy of a giant (3.0 cm × 3.0 cm × 1.0 cm) ileal lipoma causing recurrent subacute intestinal obstruction. After careful review of literature, this was the first case where polypectomy of a lipoma of this size was successfully attempted.

## Key words

Endoscopic resection, ileal lipoma, subacute intestinal obstruction

## Introduction

With the advancement in endoscopic procedures, lipomas of the terminal ileum can be treated with techniques such as snare polypectomy, endoscopic unroofing, and endoscopic submucosal dissection. A case of successful removal of an ileal lipoma causing repetitive ileocolic intussusceptions through the ileocecal valve using endoscopic snare polypectomy by cap-assisted colonoscopy was recently reported. We report a case of successful colonoscopic polypectomy of a giant (3.0 cm × 3.0 cm × 1.0 cm) ileal lipoma causing recurrent subacute intestinal obstruction. After careful review of literature, this was the first case where polypectomy of a lipoma of this size was successfully attempted.

### Address for correspondence:

Dr. Sonavane Amey, A/101, Shakuntala Krupa C.H.S., Near Mental Hospital Gate, Wagle Estate Post Office, Thane (West) - 400 604, Maharashtra, India.  
E-mail: amey\_max@yahoo.com

Video available on: [www.jdeonline.in](http://www.jdeonline.in)

### Access this article online

#### Website:

[www.jdeonline.in](http://www.jdeonline.in)

#### DOI:

10.4103/0976-5042.159241

#### Quick Response Code



## Case Report

A 56-year-old gentleman presented to us with recurrent hospitalizations for subacute intestinal obstruction. He complained of abdominal pain along with nausea and non-projectile bilious vomiting. He was treated conservatively during the first hospitalization. A month later during the second hospitalization for similar complaints, he was investigated. His laboratory parameters revealed a hemoglobin value of 12.7 g/dl; total leukocyte count of 13,300 cells/μL and a normal platelet count. His liver, renal and thyroid function tests, serum electrolytes, lipid profile, and stool examination were within normal limits. Contrast-enhanced computerized tomography of the whole abdomen revealed a fat density well circumscribed polypoidal lesion in cecum just below ileo-cecal junction measuring approximately 2.5 cm in size and average computerized tomography (CT) density of -54 Hounsfield units (HU) [Figure 1].

He presented to us with complaints of persistent nausea and mild, dull, intermittent, colicky right iliac fossa pain. He

This is an open access article distributed under the terms of the Creative Commons Attribution-NonCommercial-ShareAlike 3.0 License, which allows others to remix, tweak, and build upon the work non-commercially, as long as the author is credited and the new creations are licensed under the identical terms.

For reprints contact: [reprints@medknow.com](mailto:reprints@medknow.com)

**How to cite this article:** Amey S, Pravin R. Subacute intestinal obstruction by a giant ileal lipoma treated by endoscopic removal. *J Dig Endosc* 2015;6:70-2.

denied history of melena, bleeding per rectum, surgeries or trauma in the past. He was diagnosed with hypertension and hypothyroidism for a year and was on treatment. The general physical examination was normal. His abdomen was soft with no palpable mass. There was mild tenderness on palpation in the right iliac fossa.

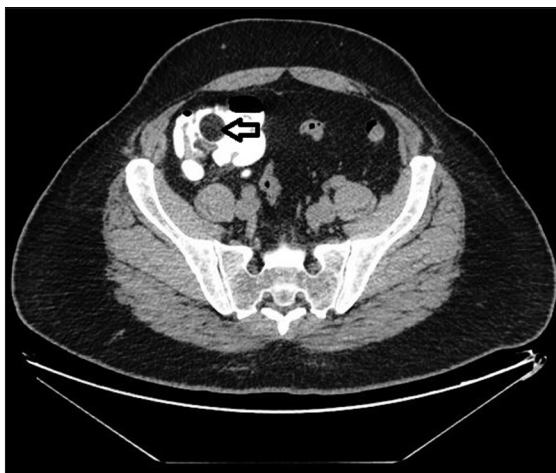He underwent cap assisted colonoscopy and ileal polypectomy. A large lobulated pedunculated lesion was seen in the distal ileum intermittently prolapsing distally into terminal ileum itself [Video 1]. In order to maintain a clear visual field in the narrow ileum, the cap-assisted colonoscopic technique was used. The base of the polyp along with peduncle was caught with a snare. Using alternate cutting and coagulation current (45 Joules coagulation and 10 Joules cutting); polypectomy was performed. Saline-diluted adrenaline injection was instilled around the polyp base. There was no evidence of

bleeding or perforation from the site of polypectomy. The polyp was caught with polyp retrieval basket and sent for histopathological examination [Figures 2 and 3]. The polyp was soft and fleshy, measured 3 cm × 3 cm × 1 cm and appeared yellowish with a yellow base. Histopathological examination was suggestive of lipomatous polyp without evidence of atypia or malignancy [Figure 4].

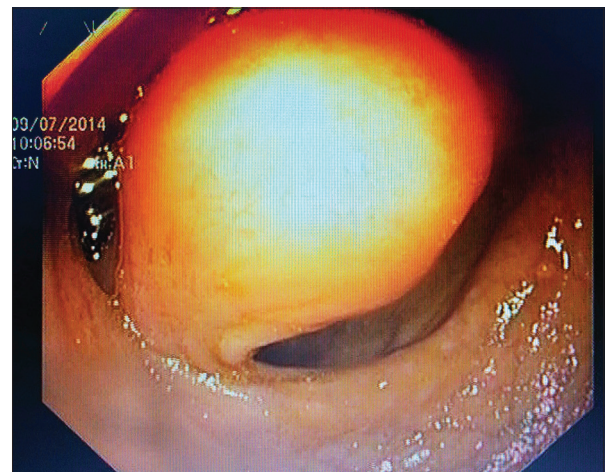
The patient tolerated the procedure well with no immediate complications. Oral feeds were introduced gradually. He opened bowels the following day. There was no melena, bleeding per rectum or abdominal symptoms related to food intake. On follow-up after 7 days, he had no complaints.

## Discussion

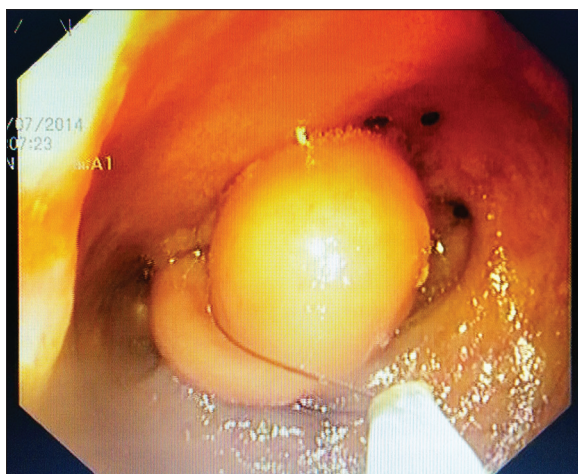
Gastrointestinal lipomas are usually solitary, infrequent, subepithelial tumors. Colon (especially right colon) is the most common site followed by the small intestine (20–25%).<sup>[1-3]</sup>



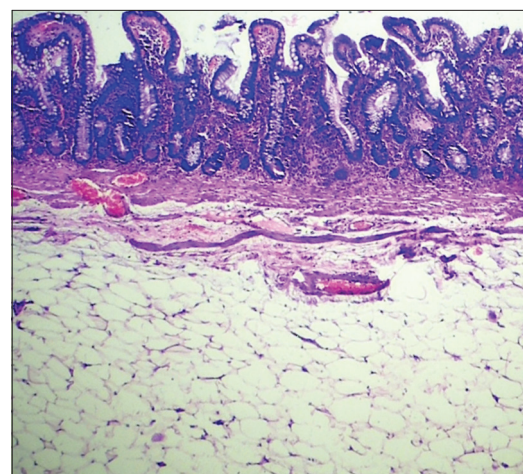
**Figure 1:** Computerized tomography (CT) of the abdomen revealing a fat density well circumscribed polypoidal lesion in cecum just below ileocecal junction measuring approximately 2.5 cm in size and average CT density of -54 Hounsfield units



**Figure 2:** Colonoscopic view of a large lobulated pedunculated lesion seen in the distal ileum intermittently prolapsing distally into terminal ileum itself



**Figure 3:** The base of the polyp along with peduncle was caught with a snare. Using alternate cutting and coagulation current; polypectomy was performed



**Figure 4:** Histopathological examination was suggestive of lipomatous polyp without evidence of atypia or malignancy

They are the second most common benign tumors in the small bowel after gastrointestinal stromal tumors. Akagi *et al.* reported that 83% of the small intestine lipoma cases reviewed were located in the ileum, and 75% of them were found within 60 cm of ileocecal valve.<sup>[4]</sup> Intestinal lipomas are of three pathological types-submucosal (90%), intramuscular, and serosal. As they are sluggishly growing, they become symptomatic beyond the fifth decade of life. A lipoma appears as an orange-yellow, fleshy, smooth, submucosal mass with or without a pedicle. It demonstrates the “cushion sign” (mass recovery instantaneously following compression by a forceps). Repeated biopsy from a certain part exposes the submucosal adipose tissue (“naked fat”).

Gastrointestinal lipomas predispose to intussusception as they can function as a leading point or cause intestinal obstruction by occlusion of the lumen.<sup>[1-3]</sup> Gastrointestinal bleeding can occur secondary to ulceration of the overlying mucosa or intussusception. Other symptoms include abdominal pain, nausea, vomiting, diarrhea, hematochezia, transit disorders, König’s syndrome or rarely an abdominal mass. Clinical signs and symptoms are dictated by the lipoma size; its location and the presence of a pseudopedicle that offers mobility to the lipoma. Lipomas <1 cm are usually asymptomatic and are incidentally found. About three-fourths of large lipomas (>4 cm) produce symptoms.<sup>[1-3]</sup> Malignant degeneration has not been reported.

The diagnostic feature of a lipoma on barium enema is that the tumor can get deformed by peristalsis (squeeze sign). A CT scan of the abdomen (diagnostic modality of choice), usually reveals an inhomogeneous smooth well circumscribed fat density (–50 to –100 HU) soft tissue lesion.

Lipomas smaller than 2 cm are considered safe to be resected by endoscopy. However, endoscopic polypectomy has been considered risky; especially when used to resect lipomas without a pedicle. The school of thought is that since fat is a poor conductor; it does not freely solidify after electric coagulation. Bleeding and deep tissue damage may occur. Accumulation of electric current during coagulation also increases the risk of intestinal perforation. Submucosal location furthermore escalates the likelihood of complications. However, with advancement of endoscopic techniques, increasing number of gastroenterologists are attempting endoscopic polypectomy. In the unroofing technique, an incision made over the upper half of the mucosal surface of the mass causes spontaneous release of the lipoma; thus minimizing the chances of hemorrhage or perforation while performing resection. A detachable endoloop (with or without balloon-assisted enteroscopy) helps in slow mechanical transection. Slow transection of the stalk of the polyp prevents the hazard of bowel perforation. The main limitation is that retrieval of the specimen may not be possible.<sup>[5,6]</sup> Both these techniques are time-consuming. Endoscopic snare polypectomy of a large lesion in the small intestine is more

challenging due to narrower lumen. Hence, cap-assisted colonoscopy<sup>[7]</sup> is performed which helps in keeping a distance suitable to maintain a clear visual field. A novel technique successfully tried by Yoshimura *et al.*<sup>[8]</sup> was to drag the ileal lipoma (2.5 cm × 2.2 cm × 2.0 cm) by aspiration into the colonic lumen followed by resection. Benatta *et al.* recently reported two adjacent ileocecal lipomas (0.5 cm and 1.5 cm) that were successfully removed by electrosurgical snare polypectomy.<sup>[9]</sup> Spontaneous expulsion of a large ileal lipoma (7.0 cm × 4.5 cm × 3.6 cm) has also been lately reported.<sup>[10]</sup>

The patient described above was initially offered surgical excision of the ileal lipoma. However, the patient had refused for surgery and had accepted possible complications of endoscopic treatment. On the other hand, by performing a successful endoscopic resection, the possible surgical complications were avoided. This case portrays that a large ileal lipoma when strategically located, can be successfully resected using endoscopic techniques thus evading a major abdominal surgery.

#### Financial support and sponsorship

Nil.

#### Conflict of interest

There are no conflict of interest.

#### References

1. Manouras A, Lagoudianakis EE, Dardamanis D, Tsekouras DK, Markogiannakis H, Genetzakis M, *et al.* Lipoma induced jejunojunal intussusception. *World J Gastroenterol* 2007;13:3641-4.
2. Thompson WM. Imaging and findings of lipomas of the gastrointestinal tract. *AJR Am J Roentgenol* 2005;184:1163-71.
3. Taylor AJ, Stewart ET, Dodds WJ. Gastrointestinal lipomas: A radiologic and pathologic review. *AJR Am J Roentgenol* 1990;155:1205-10.
4. Akagi I, Miyashita M, Hashimoto M, Makino H, Nomura T, Tajiri T. Adult intussusception caused by an intestinal lipoma: Report of a case. *J Nippon Med Sch* 2008;75:166-70.
5. Veloso R, Pinho R, Rodrigues A, Pais T, Fernandes C, Carvalho J, *et al.* Endoloop ligation (“loop-and-let-go”) of a large ileal lipoma by balloon-assisted enteroscopy. *Endoscopy* 2012;44 Suppl 2 UCTN: E176.
6. Morimoto T, Fu KI, Konuma H, Izumi Y, Matsuyama S, Ogura K, *et al.* Peeling a giant ileal lipoma with endoscopic unroofing and submucosal dissection. *World J Gastroenterol* 2010;16:1676-9.
7. Lee ES, Lee KN, Choi KS, Lee HL, Jun DW, Lee OY, *et al.* Endoscopic treatment of a symptomatic ileal lipoma with recurrent ileocolic intussusceptions by using cap-assisted colonoscopy. *Clin Endosc* 2013;46:414-7.
8. Yoshimura H, Murata K, Takase K, Nakano T, Tameda Y. A case of lipoma of the terminal ileum treated by endoscopic removal. *Gastrointest Endosc* 1997;46:461-3.
9. Benatta MA, Desjeux A, Grimaud JC. Two ileocecal valve lipomas. *Ann Gastroenterol* 2014;27:265.
10. Kang B, Zhang Q, Shang D, Ni Q, Muhammad F, Hou L, *et al.* Resolution of intussusception after spontaneous expulsion of an ileal lipoma per rectum: A case report and literature review. *World J Surg Oncol* 2014;12:143.