

## Case Report

# The “mule” with golden eggs: Retrieval of unusual foreign body

Chhavi Wadhwa, Shibumon Madhavan, Alfred J. Augustine, Suresh Shenoy, Abid Mirza

Department of Surgery, Kasturba Medical College, Manipal University, Mangalore, Karnataka, India

## Abstract

Foreign body ingestions often consist of benign objects that will readily pass through the gastrointestinal (GI) tract without necessitating further intervention. There are various reports in the literature about intentional ingestion of foreign bodies in prisoners and body packers, which required intervention. We present a case of 44-year-old male with a history of intentional ingestion of 30 gold pellets as a carrier from Dubai to India. The pellets were successfully retrieved by upper GI endoscopy after 1-week of observation and unsuccessful attempts of conservative trial. There have been many foreign body extractions but gold retrieval has been a rare case.

## Key words

Dormia basket, endoscopy, foreign body, gold pellets

## Introduction

Foreign body ingestion and its retrieval is a relatively common occurrence in children.<sup>[1,2]</sup> In adults, intentional ingestion may occur in prisoners, and “body packers” or “body stuffers” who have been known to ingest packaged illegal substances such as heroin, cocaine, and gold in order to avoid detection.<sup>[3-5]</sup> Surgical removal of the foreign body will be required very rarely.<sup>[2]</sup> Even though there are enough literature on body packers, there are no descriptions about body packing of gold, which required medical intervention. We present a clinical case report of endoscopic retrieval of 29 golden pellets from the stomach of a 44-year-old man with retroviral disease, who became the mule due to financial constraints.

## Case Report

A 44-year-old male presented to the surgical outpatient

department (OPD) with a history of “intentional” foreign body ingestion before 5 days in Dubai, which he claimed to be 30 gold pellets each weighing about 15 g. He reported to OPD when he developed abdominal pain after 4 days of futile observation for passage of the pellets. He was a known case of retroviral disease on treatment. On examination, his vitals were stable and abdominal examination did not show any positive findings. Abdominal X-ray confirmed the presence of foreign body [Figure 1].

Conservative measures with laxatives and enema presuming that the foreign body has reached the left colon failed and repeat X-ray after 48 h did not show any change in the position of the foreign body. The patient was subjected to colonoscopy but could not find any foreign body in the colon. Upper gastrointestinal endoscopy was done and the gold pellets were found in the stomach and were extracted using a dormia basket. Twenty-nine gold pellets weighing 15 g each were successfully extracted [Figure 2]. One pellet which escaped the retrieval (confirmed in X-ray) came out in stools on the following day. Patient had uneventful recovery and was discharged after completing the legal formalities.

### Address for correspondence:

Dr. Alfred J. Augustine, Department of Surgery, Kasturba Medical College, Manipal University, Mangalore, Karnataka, India.  
E-mail: alfred.augustine@manipal.edu

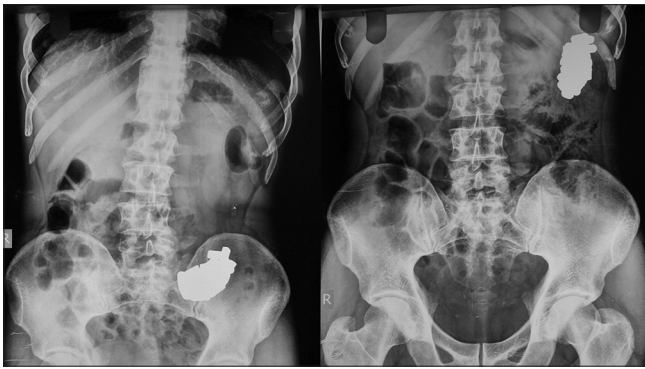### Access this article online

<b>Website:</b> www.jdeonline.in	<b>Quick Response Code</b> 
<b>DOI:</b> 10.4103/0976-5042.159247	

This is an open access article distributed under the terms of the Creative Commons Attribution-NonCommercial-ShareAlike 3.0 License, which allows others to remix, tweak, and build upon the work non-commercially, as long as the author is credited and the new creations are licensed under the identical terms.

For reprints contact: reprints@medknow.com

**How to cite this article:** Wadhwa C, Madhavan S, Augustine AJ, Shenoy S, Mirza A. The “mule” with golden eggs: Retrieval of unusual foreign body. *J Dig Endosc* 2015;6:79-80.




**Figure 1:** Abdominal X-ray confirming the presence of foreign body

## Discussion

Gold smuggling to India especially from the Middle East has increased in the recent years. Body packing is not uncommon in gold smugglers but they rarely seek medical attention as most of the packed stuff is self-retrieved. There are various reports in the literature about intentional ingestion of foreign bodies by prisoners, body packers.<sup>[3-5]</sup> Body packing of cocaine and other illegal substances are well known and there are enough descriptions about various complications and their management guidelines.<sup>[3-5]</sup> Unlike drugs, gold is an inert metal and pass spontaneously without complications, does not necessitate medical attention.

In our patient, the pellets failed to pass the stomach even after 1-week probably due to the clumping together of the pellets and its weight (430 g). Plain radiographs can identify and confirm the location, size, shape, and number of ingested foreign bodies but can be misleading as in our case. Foreign body seen in the left iliac fossa on X-ray was actually in the stomach but was misinterpreted as in the left colon. Stomach reached the lower abdomen probably due to the weight of the gold and this can also explain the failure of passage from the stomach. Management of foreign body ingestion depends on the patient age, clinical condition, the shape, size, content and anatomical location of the object, and time since ingestion. Endoscopy is absolutely indicated when the object is >2.5 cm in diameter or more than 5–7 cm in length, as these are less likely to pass through the pylorus.<sup>[5]</sup> Objects failing to pass the stomach after 1-week duration should be removed endoscopically. Surgical removal is indicated when signs of peritonitis are present and for removal of objects located distal to the duodenum and fail to progress after 1-week. Endoscopic retrieval was delayed in our case because the authors felt that the foreign body has reached the left colon based on the misleading X-ray finding.



**Figure 2:** Extracted gold pellets

Endoscopic retrieval of multiple foreign bodies is time-consuming and tedious job. In our patient, we have retrieved 29 out of 30 gold pellets, which required multiple insertions and removal of the scope. This is probably the largest number of foreign bodies retrieved by endoscopy. Li *et al.* has reported endoscopic retrieval of 28 foreign bodies in a 100-year-old lady of which 26 of them were coins.<sup>[6]</sup> Apart from this, endoscopic retrieval of these many foreign bodies has not been reported. To our knowledge, endoscopic retrieval of smuggled gold has not been reported in the medical literature.

## Financial support and sponsorship

Nil.

## Conflict of interest

There are no conflict of interest.

## References

1. Jayachandra S, Eslick GD. A systematic review of paediatric foreign body ingestion: Presentation, complications, and management. *Int J Pediatr Otorhinolaryngol* 2013;77:311-7.
2. Erbil B, Karaca MA, Aslaner MA, Ibrahimov Z, Kunt MM, Akpinar E, *et al.* Emergency admissions due to swallowed foreign bodies in adults. *World J Gastroenterol* 2013;19:6447-52.
3. Silverberg D, Menes T, Kim U. Surgery for “body packers” – A 15-year experience. *World J Surg* 2006;30:541-6.
4. Losanoff JE, Kjossev KT. Gastrointestinal “crosses”: An indication for surgery. *J Clin Gastroenterol* 2001;33:310-4.
5. Ribas Y, Ruiz-Luna D, Garrido M, Bargalló J, Campillo F. Ingested foreign bodies: Do we need a specific approach when treating inmates? *Am Surg* 2014;80:131-7.
6. Li QP, Ge XX, Ji GZ, Fan ZN, Zhang FM, Wang Y, *et al.* Endoscopic retrieval of 28 foreign bodies in a 100-year-old female after attempted suicide. *World J Gastroenterol* 2013;19:4091-3.