

Case Report

Pancreatic neuroendocrine tumor masquerading as metastasis in a patient with esophageal cancer: Diagnosis by endoscopic ultrasound-guided fine-needle aspiration

Pramoda Koduru, Shruti Khurana¹, Joan B. Gornals², Modesto Varas³, Sinchita Roy-Chowdhuri⁴, Manoop S. Bhutani

Department of Gastroenterology, Hepatology and Nutrition, University of Texas MD Anderson Cancer Center, ¹Department of Gastroenterology, Hepatology and Nutrition, University of Texas Health Science Center, ⁴Department of Pathology, University of Texas MD Anderson Cancer Center, Houston, Texas, USA, ²Department of Digestive Diseases, Endoscopy Unit, Hospital Universitari de Bellvitge-IDIBELL, ³Centro Médico Teknon and Hospital Universitario del Valle Hebrón, Unit of Echoendoscopy, Barcelona, Spain

Abstract

The role of endoscopic ultrasound (EUS) and guided biopsies has been well established for the locoregional staging of esophageal cancers. However, their role in posttreatment surveillance is unclear. Here, we describe a case of a pancreatic mass diagnosed on the follow-up positron emission tomography scan, concerning for a metastatic lesion. EUS-guided fine-needle aspiration (FNA) helped in establishing the diagnosis of neuroendocrine tumor, which tends to have a similar sonographic appearance. Therefore, it is imperative to evaluate a suspicious mass seen on computed tomography/positron emission tomography scan. EUS and EUS-guided FNA can serve as useful modalities to confirm the diagnosis by cytopathology.

Key words

Esophageal cancer, endoscopic ultrasound, fine-needle aspiration, metastasis, neuroendocrine tumor, pancreas, pancreatic neuroendocrine tumor, positron emission tomography scan

Introduction

Endoscopic ultrasound (EUS) with fine-needle aspiration (FNA) has emerged as an important tool for diagnosis and staging of many gastrointestinal cancers along with computed tomography-positron emission tomography (CT-PET) scan.^[1] It has proven to be more sensitive than other imaging studies in the assessment of locoregional lymph node metastases,^[2] but also assists in

visualizing metastases to other organs such as the pancreas, liver, or left adrenal gland. The role of EUS in posttreatment surveillance of esophageal cancer is not well established. Here, we present a case in which EUS not only ruled out a recurrence of esophageal cancer but also reiterated the sensitivity of the test to detect lesions not seen on imaging.

Case Report

We describe the case of a 68-year-old male with a history of aggressive esophageal adenocarcinoma of gastro-esophageal (GE) junction who underwent transhiatal esophagectomy followed by adjuvant chemotherapy. He presented with

Address for correspondence:

Dr. Manoop S. Bhutani, Department of Gastroenterology, Hepatology and Nutrition, Unit 1466, University of Texas MD Anderson Cancer Center, 1515 Holcombe Blvd., Houston, Texas 77030-4009, USA.
E-mail: manoop.bhutani@mdanderson.org

Access this article online

Website:

www.jdeonline.in

DOI:

10.4103/0976-5042.189163

Quick Response Code



This is an open access article distributed under the terms of the Creative Commons Attribution-NonCommercial-ShareAlike 3.0 License, which allows others to remix, tweak, and build upon the work non-commercially, as long as the author is credited and the new creations are licensed under the identical terms.

For reprints contact: reprints@medknow.com

How to cite this article: Koduru P, Khurana S, Gornals JB, Varas M, Roy-Chowdhuri S, Bhutani MS. Pancreatic neuroendocrine tumor masquerading as metastasis in a patient with esophageal cancer: Diagnosis by endoscopic ultrasound-guided fine-needle aspiration. *J Dig Endosc* 2016;7:80-2.

increased activity in the distal margin of gastric pull-through on surveillance CT-PET scan 3 years after remission [Figures 1 and 2].

The EGD was performed at our institution, which revealed intense erythema in the body and antrum, but showed no evidence of recurrence at the site of GE anastomosis. On further evaluation, EUS showed a well-defined, hypoechoic to isoechoic nodule with a homogeneous pattern, measuring 1 cm × 0.5 cm in the mid pancreatic body via transduodenal imaging from duodenal bulb [Figure 3]. EUS-guided FNA of the pancreatic nodule was done [Figure 4] and multiple endoscopic biopsies were taken for surveillance from the anastomosis and the gastric conduit. Histopathologic evaluation of the biopsies from the anastomosis and the gastric conduit did not show any evidence of recurrence. The cytopathology of the nodule showed a low-grade neuroendocrine tumor with immunostains positive for

synaptophysin and chromogranin [Figures 5a, b and 6a, b]. It was classified as low-grade tumor based on immunostains for Ki-67 (proliferative index).

Discussion

Esophageal cancer is the third most common gastrointestinal malignancy with poor prognosis. Despite aggressive treatment with a multi-modality approach, recurrence rates remain high and tend to recur within the 1st year. The role of EUS in posttreatment surveillance is controversial.^[3,4]

Esophageal cancers rarely metastasize to the pancreas.^[5] It can be challenging to differentiate primary neuroendocrine tumor in pancreas from metastases as both may appear as homogenous, hypoechoic solid lesions that have well-demarcated borders.^[6] Compared to other imaging techniques, EUS has many advantages of being able to detect small lesions within the pancreas and duodenal wall as well

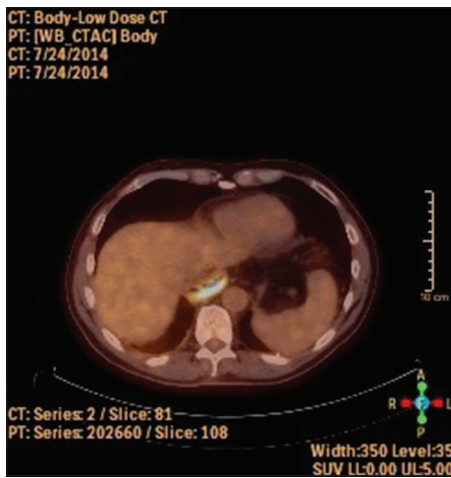


Figure 1: Computed tomography-positron emission tomography image showing linear hypermetabolic activity along the posterior margin of the distal pull through

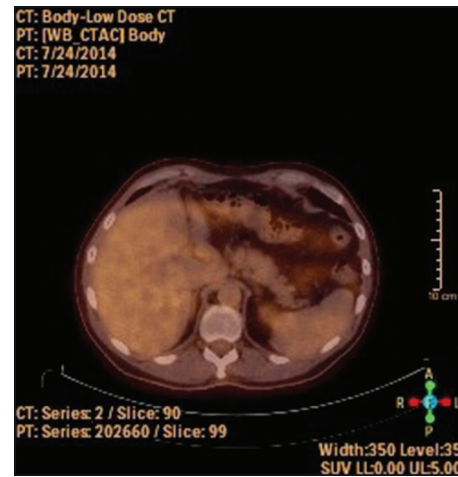


Figure 2: Computed tomography-positron emission tomography image at the level of pancreas did not reveal any increased activity

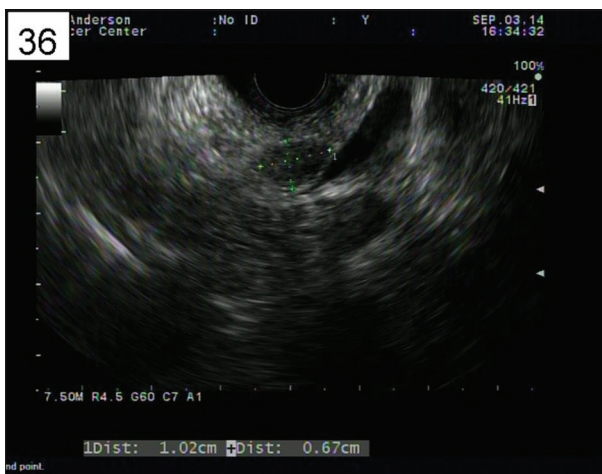

Figure 3: Endoscopic ultrasound image showing oval to rounded, well-defined, hypoechoic nodule measuring 1.02 cm by 0.67 cm size in the mid pancreatic body seen via transduodenal imaging from the duodenal bulb

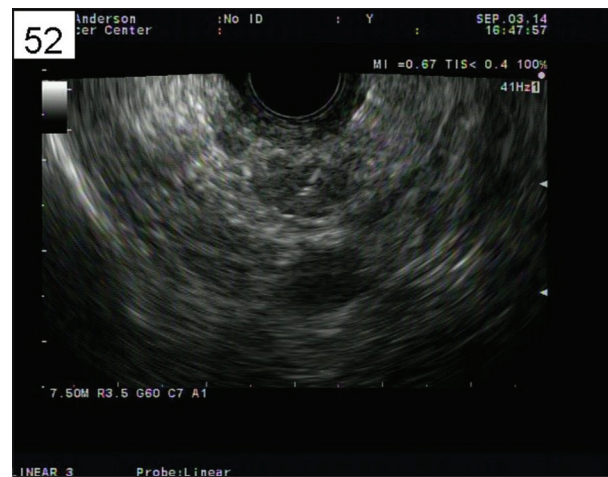


Figure 4: Endoscopic ultrasound image showing transduodenal endoscopic ultrasound fine needle aspiration of the pancreatic nodule with a 25-gauge needle

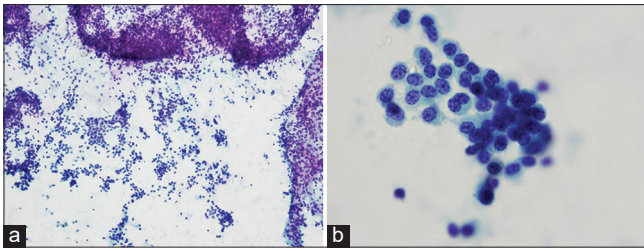


Figure 5: (a) (left panel) - low power view showing a moderately cellular smear stained with Papanicolaou stain, with small loose clusters and singly dispersed small uniform tumor cells. (b) (right panel) - high power view of tumor cells stained with papanicolaou stain, showing clusters of small uniform cells with eccentrically located round to oval nuclei, occasional binucleation and characteristic stippled "salt and pepper" chromatin

as to obtain FNA, which can provide cytological confirmation for diagnosis.^[7]

Pancreatic neuroendocrine tumors (PNETs) are rare tumors, accounting for approximately 2% of primary pancreatic malignancies. The important factors that predict malignant behavior seem to be the TNM stage and histologic grade based on mitosis rate and Ki-67 (proliferative index).^[8] EUS-FNA has proven to be a useful tool in diagnosis, grading, and staging of PNETs.^[9,10]

In our case, EUS played a major role by discovering a lesion that was missed on CT-PET scan done for posttreatment surveillance. This has significant implications in management by avoiding administration of unnecessary chemotherapy with significant toxicities. This case reinforces the importance of EUS imaging of esophageal cancer not only for clarifying the question of recurrence but also in identifying the lesions that may be missed by other cross-sectional imaging modalities. EUS is also useful in the diagnosis of PNETs.

Financial support and sponsorship

Nil.

Conflicts of interest

There are no conflicts of interest.

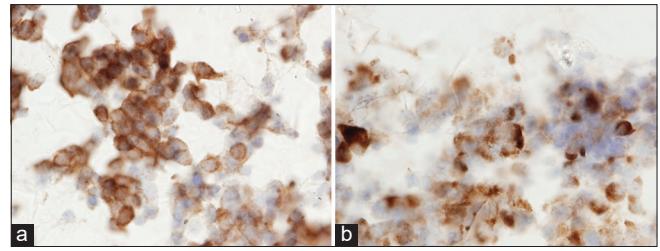


Figure 6: (a) (left panel) - immunoperoxidase stain for synaptophysin is positive in tumor cells. (b) (right panel) - immunoperoxidase stain for chromogranin is positive in tumor cells

References

- van Vliet EP, Heijnenbroek-Kal MH, Hunink MG, Kuipers EJ, Siersema PD. Staging investigations for oesophageal cancer: A meta-analysis. *Br J Cancer* 2008;98:547-57.
- Foley KG, Lewis WG, Fielding P, Karran A, Chan D, Blake P, *et al.* N-staging of oesophageal and junctional carcinoma: Is there still a role for EUS in patients staged N0 at PET/CT? *Clin Radiol* 2014;69:959-64.
- Misra S, Choi M, Livingstone AS, Franceschi D. The role of endoscopic ultrasound in assessing tumor response and staging after neoadjuvant chemotherapy for esophageal cancer. *Surg Endosc* 2012;26:518-22.
- Griffin JM, Reed CE, Denlinger CE. Utility of restaging endoscopic ultrasound after neoadjuvant therapy for esophageal cancer. *Ann Thorac Surg* 2012;93:1855-9.
- Esfehani MH, Mahmoodzadeh H, Alibakhshi A, Safavi F. Esophageal squamous cell carcinoma with pancreatic metastasis: A case report. *Acta Med Iran* 2011;49:760-2.
- Gornals J, Varas M, Catalá I, Maisterra S, Pons C, Bargalló D, *et al.* Definitive diagnosis of neuroendocrine tumors using fine-needle aspiration-puncture guided by endoscopic ultrasonography. *Rev Esp Enferm Dig* 2011;103:123-8.
- Atiq M, Bhutani MS, Ross WA, Raju GS, Gong Y, Tamm EP, *et al.* Role of endoscopic ultrasonography in evaluation of metastatic lesions to the pancreas: A tertiary cancer center experience. *Pancreas* 2013;42:516-23.
- Ekeblad S, Skogseid B, Dunder K, Oberg K, Eriksson B. Prognostic factors and survival in 324 patients with pancreatic endocrine tumor treated at a single institution. *Clin Cancer Res* 2008;14:7798-803.
- Khashab MA, Yong E, Lennon AM, Shin EJ, Amateau S, Hruban RH, *et al.* EUS is still superior to multidetector computerized tomography for detection of pancreatic neuroendocrine tumors. *Gastrointest Endosc* 2011;73:691-6.
- Atiq M, Bhutani MS, Bektas M, Lee JE, Gong Y, Tamm EP, *et al.* EUS-FNA for pancreatic neuroendocrine tumors: A tertiary cancer center experience. *Dig Dis Sci* 2012;57:791-800.