

## Case Report

# A case of abdominal pain and abnormal location of gallstone diagnosed by endoscopic ultrasound

Narendra Singh Choudhary, Rajesh Puri, Rinkesh Kumar Bansal, Mukesh Nasa

Institute of Digestive and Hepatobiliary Sciences, Medanta - The Medicity, Gurgaon, Haryana, India

## Abstract

A 50-year-old male came to us with pain abdomen; endoscopic ultrasound (EUS) made a diagnosis of cholecystoduodenal fistula which was later on confirmed on gastroscopy and surgery. We present interesting images of EUS; a calculus is visualized outside gallbladder with inflammatory changes of duodenal wall.

## Key words

Biliary-enteric fistula, cholecystoduodenal fistula, intestinal obstruction

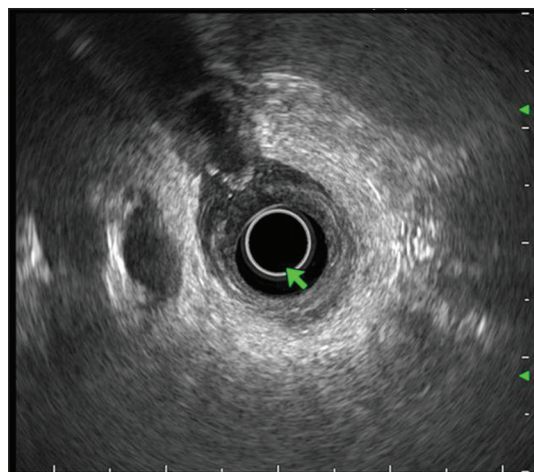
## Introduction

Cholecystoduodenal fistulas is a rare complications of cholelithiasis. The present case represents a gallstone in the process passing from gallbladder to duodenum. EUS helps in correct diagnosis in this present case.

## Case Report

A 50-year-old male presented with intermittent abdominal pain suggestive of biliary colic. An abdominal ultrasound was done which revealed gallstones and prominent bile duct. His liver function tests were normal. An endoscopic ultrasound (EUS) was done to look for common bile duct calculi. The EUS image [Figure 1] shows prominent common bile duct and normal portal vein at 9 o'clock position and a stone with acoustic shadow at 11 o'clock position. This calculus was outside gallbladder; the surrounding duodenal wall was thickened and showed hypoechoic (inflammatory changes). There was no stone in common bile duct.

A diagnosis of cholecystoduodenal fistula was suggested. A gastroduodenoscopy was done after EUS which showed pus and an inflammatory area in first part of duodenum as shown in Figures 2 and 3. The diagnosis was confirmed during surgery, laproscopic surgery was attempted which needed conversion to open surgery.



**Figure 1:** Endoscopic ultrasound image showing calculus outside gallbladder and nearby thickening of duodenal wall

### Address for correspondence:

Dr. Rajesh Puri, Institute of Digestive and Hepatobiliary Sciences, Medanta - The Medicity, Gurgaon, Haryana, India.  
E-mail: purirajesh70@gmail.com

### Access this article online

#### Website:

www.jdeonline.in

#### DOI:

10.4103/0976-5042.202821

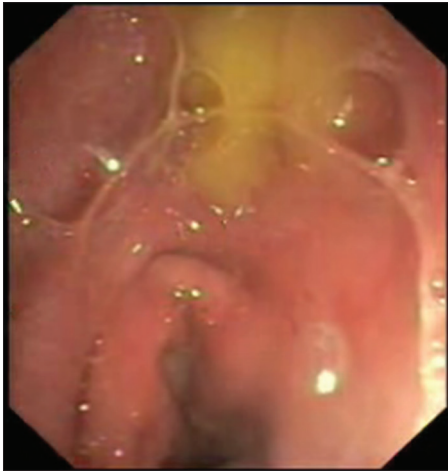#### Quick Response Code



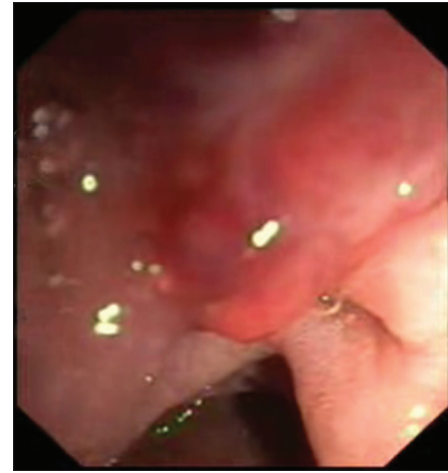This is an open access article distributed under the terms of the Creative Commons Attribution-NonCommercial-ShareAlike 3.0 License, which allows others to remix, tweak, and build upon the work non-commercially, as long as the author is credited and the new creations are licensed under the identical terms.

**For reprints contact:** reprints@medknow.com

**How to cite this article:** Choudhary NS, Puri R, Bansal RK, Nasa M. A case of abdominal pain and abnormal location of gallstone diagnosed by endoscopic ultrasound. *J Dig Endosc* 2017;8:42-3.



**Figure 2:** Endoscopy image showing pus in duodenal bulb



**Figure 3:** Endoscopy image showing inflammatory area in duodenal bulb

## Discussion

Cholecystoduodenal fistulas are a type of biliary-enteric fistula, are rare complications of cholelithiasis. Multiple factors such as size of the gallstone (2–8 cm), long history of biliary disease, repeated episodes of cholecystitis, female sex, and old age (>60 years) favor formation of these fistula.<sup>[1]</sup> The relative frequency of fistula is cholecystoduodenal (60%), cholecystocolic (15%), cholecystogastric (5%), and choledochoduodenal (5%).<sup>[2]</sup> These patients generally diagnosed at the time of surgery and may require conversion of laproscopic to open surgery. In large study of 12,428 patients undergoing laparoscopic cholecystectomy, cholecystoenteric fistula was diagnosed in 63 (45 cholecystoduodenal) at the time of surgery. The surgery could be completed laparoscopically in majority. We concluded that a high degree of suspicion at the time of surgery is mandatory.<sup>[3]</sup> Gallstones may be passed through cholecystoduodenal fistula and may cause intestinal obstruction.<sup>[4]</sup>

The present case represents a gallstone in the process passing from gallbladder to duodenum. Careful observation during

EUS that calculus is outside gallbladder helped us in correct diagnosis in the present case.

## Financial support and sponsorship

Nil.

## Conflicts of interest

There are no conflicts of interest.

## References

1. Katsinelos P, Dimiropoulos S, Tsolkas P, Baltagiannis S, Kapelidis P, Galanis I, *et al.* Successful treatment of duodenal bulb obstruction caused by a gallstone (Bouveret's syndrome) after endoscopic mechanical lithotripsy. *Surg Endosc* 2002;16:1363.
2. Clavien PA, Richon J, Burgan S, Rohner A. Gallstone ileus. *Br J Surg* 1990;77:737-42.
3. Chowbey PK, Bandyopadhyay SK, Sharma A, Khullar R, Soni V, Baijal M. Laparoscopic management of cholecystoenteric fistulas. *J Laparoendosc Adv Surg Tech A* 2006;16:467-72.
4. Schumacher G, Keck H, Neuhaus P. Cholecystoduodenal fistula with subsequent gallstone ileus: Case report of an unusual course. *Zentralbl Chir* 1996;121:408-11.