

Addition of a pontic to all-ceramic Turkom-Cera fixed partial denture restorations

Bulent Uludag¹, Emre Tokar², Serdar Polat³

Correspondence: Dr. Emre Tokar
Email: emretokar@yahoo.com

¹Department of Prosthodontics, Faculty of Dentistry, University of Ankara, Ankara, Turkiye

²Department of Prosthodontics, Faculty of Dentistry, University of Gazi, Ankara, Turkiye

³Department of Prosthodontics, Faculty of Dentistry, University of Mustafa Kemal, Hatay, Turkiye

ABSTRACT

High-strength all-ceramic materials are commonly used in dentistry. When complications occur in an all-ceramic restoration, the restoration is usually replaced. This article describes the time-saving ability and cost-effectiveness of this novel technique for the addition of a pontic in two complicated clinical cases. Turkom-Cera™ [Turkom-Ceramic (M) Sdn. Bhd.] with aluminum oxide (99.98%) is an all-ceramic system that offers the option of addition of a new pontic to the sintered framework. The new pontic was cut off from an alumina blank [Turkom-Ceramic (M) Sdn. Bhd.], moistened, and attached to the framework using alumina gel [Turkom-Ceramic (M) Sdn. Bhd.]. The framework was veneered with veneering porcelain (Vita VM 7; VITA Zahnfabrik). The two cases presented here involving the addition of a pontic to sintered framework were followed up for at least 1 year. No complication was detected or reported by the patients. Alumina- and zirconia-based ceramics are particularly suitable for all-ceramic restorations in high-stress bearing areas. However, replacement of a failed all-ceramic restoration is not the most practical solution, considering both cost and tooth-related factors. This attractive feature of the Turkom-Cera allows the repair of a fractured ceramic coping or the addition of a new pontic to restorations.

Key words: All-ceramic, fixed partial denture, repair technique

INTRODUCTION

All-ceramic full crowns have become very popular with both patients and clinicians because of their highly esthetic results, biocompatibility,^[1] chemical stability, and significant capacity to imitate dental tissues.^[2] High-strength all-ceramic materials, such as alumina, zirconia, and pressed, castable, or machinable glass ceramics, are commonly used in dentistry.^[3] Alumina- and zirconia-based ceramics are attractive as potential materials for all-ceramic restorations (ACRs) in high stress-bearing areas.^[4] The most commonly reported major complication that requires complete refabrication of an ACR is fracture of the veneering porcelain and/or ceramic coping.^[5] However, replacement of a failed ACR is often not the most practical solution, when replacement

cost, compromise of additional tooth structure, and additional trauma to the tooth are considered.^[6] An ACR material, Turkom-Cera™ [Turkom-Ceramic (M) Sdn. Bhd., Kuala Lumpur, Malaysia] with aluminum oxide (99.98%), has been introduced in an attempt to provide high-quality, cost-effective copings and to improve clinical success with ACR.^[7,8] The manufacturers of this system also claim that a new pontic can be added to the sintered framework.

This article describes two clinical case reports of the addition of a pontic to a fabricated Turkom-Cera ACR.

CASE REPORTS

Case 1

A 27-year-old White male was referred to the

How to cite this article: Uludag B, Tokar E, Polat S. Addition of a pontic to all-ceramic Turkom-Cera fixed partial denture restorations. *Eur J Dent* 2013;7:233-8.

Copyright © 2013 Dental Investigations Society.

DOI: 10.4103/1305-7456.110194

Prosthodontics Department of University of Ankara Faculty of Dentistry for an emergency prosthetic evaluation. The patient reported that he had congenitally missing lateral incisors. He had a maxillary all-ceramic fixed partial denture (FPD) constructed by a private dental office for esthetic purposes and the right 3-unit FPD had recently fractured. A 5-unit maxillary left all-ceramic FPD, supported by the central incisors, canine, and second premolar teeth, as well as prepared maxillary right canine and second premolar teeth, was present at the initial clinical examination [Figure 1]. No periapical pathologies were noted in the radiographic examination. Considering the resulting diastema that would jeopardize the esthetic appearance following fabrication of a new 3-unit maxillary right all-ceramic FPD, the patient was offered a treatment plan that included removal of the existing maxillary left 5-unit all-ceramic FPD and construction of a new maxillary 9-unit all-ceramic FPD. The patient declined this treatment plan, indicating he did not favor the removal of the 5-unit maxillary left FPD. A new treatment plan that included fabrication of a maxillary right 3-unit FPD with a mesial diastema was offered and it was accepted by the patient. A maxillary impression was made with polyvinyl-siloxane impression material (Affinis Precious; Coltene/Whaledent, Altstätten, Switzerland) using a putty-wash technique and a stock tray. A mandibular impression was made with an irreversible hydrocolloid (CA 37; Cavex Holland BV, Haarlem, The Netherlands) using a stock tray. The casts were poured with type IV stone. The vertical occlusal dimension and centric relation were obtained and the casts were transferred to a semi-adjustable articulator. A 3-unit all-ceramic FPD framework was fabricated from Turkom-Cera all-ceramic material according to the manufacturer's recommendations [Figure 2]. The fit of the framework was verified intraorally, and at this stage, the patient stated that he did not want a diastema. After considering the properties of the all-ceramic material used, a decision was made to add a maxillary right lateral pontic to the sintered framework. The framework was cleaned with a steam cleaner and ultrasonically cleaned in ethyl acetate solution for 2 min, and then the proposed site for the new pontic was roughened with a grinding stone. The new pontic was cut off from an alumina blank [Turkom-Ceramic (M) Sdn. Bhd.], moistened, and attached to the framework using alumina gel [Turkom-Ceramic (M) Sdn. Bhd.]. The resulting framework was sintered and

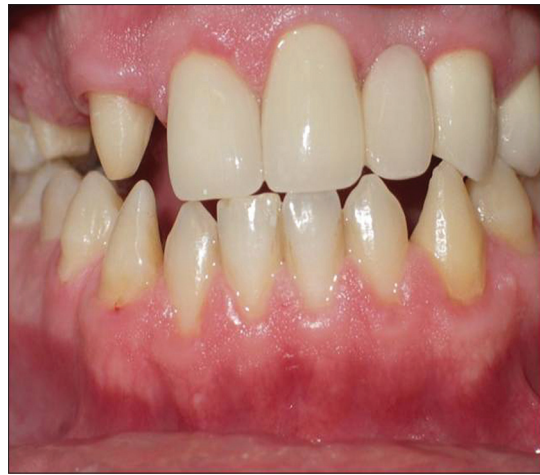

Figure 1: Intraoral view of the first case

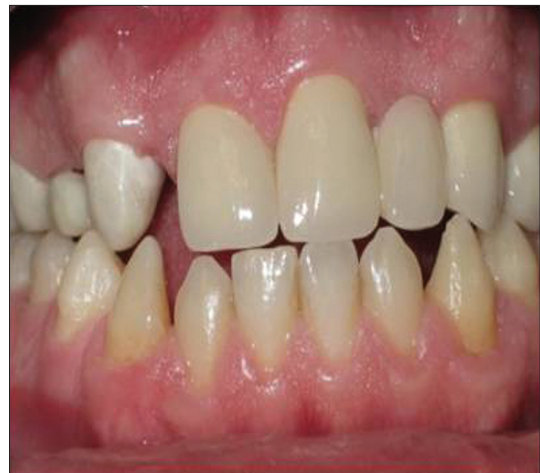

Figure 2: Intraoral view of 3-unit Turkom-Cera fixed partial denture framework

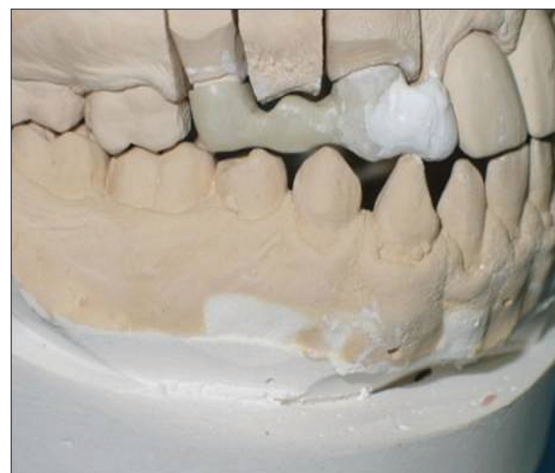

Figure 3: Addition of a new pontic to the Turkom-Cera framework with alumina gel

glass infiltrated according to the manufacturer's instructions [Figure 3]. The fit of the new framework was verified intraorally and veneered with

veneering porcelain. The FPD was cemented with resin cement (Multilink Sprint; Ivoclar Vivadent, The Netherlands) [Figure 4]. The patient has been followed up for 2 years and no complications have been reported.

Case 2

A 36-year-old male presented to the Prosthodontics Department of University of Ankara Faculty of Dentistry with pain from the maxillary anterior region. The patient reported that due to a crown fracture 4 months previously, he had all-ceramic crown restorations constructed for the maxillary right central incisor, left central incisor, and left lateral incisor. The maxillary right central incisor had been treated endodontically and a horizontal root fracture was detected on the maxillary left central incisor following whole radiographic examination [Figure 5]. The left maxillary central incisor was found severely mobile, and the crown

and root segments were extracted atraumatically. The patient did not want a new all-ceramic bridge restoration, and he also did not consent to implant-supported crown restoration for economic reasons. In addition, he wanted a quick, esthetic, and cost-effective solution for his missing tooth. Healing was evaluated 14 days after the extraction and the Turkom-Cera [Turkom-Ceramic (M) Sdn. Bhd.] all-ceramic crown restorations were removed from the right central and left lateral incisors for addition of a pontic [Figure 6]. Crown restorations were inserted again on the prepared tooth and fixed with light-bodied elastomeric impression material [Oranwash L, Zhermack SpA, Badia Polesine (RO), Italy] [Figure 7]. An impression of the maxillary arch was made with irreversible hydrocolloid impression material (CA 37; Cavex Holland BV) using a stock tray [Figure 8]. Casts were

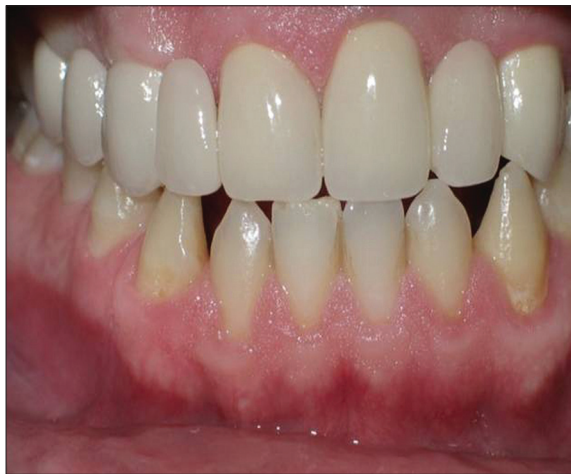

Figure 4: Final restoration of the first case

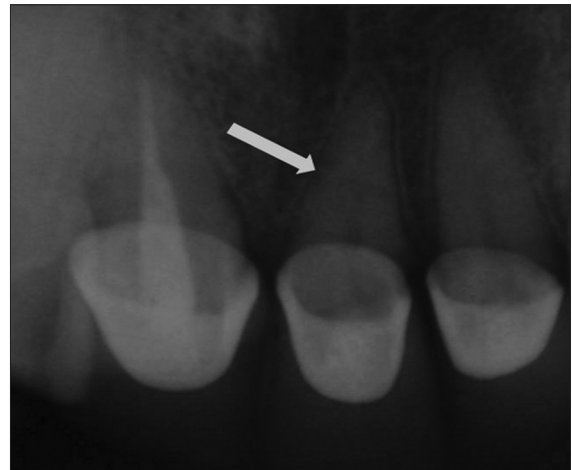

Figure 5: Radiographic view of root fracture of the maxillary left central incisor

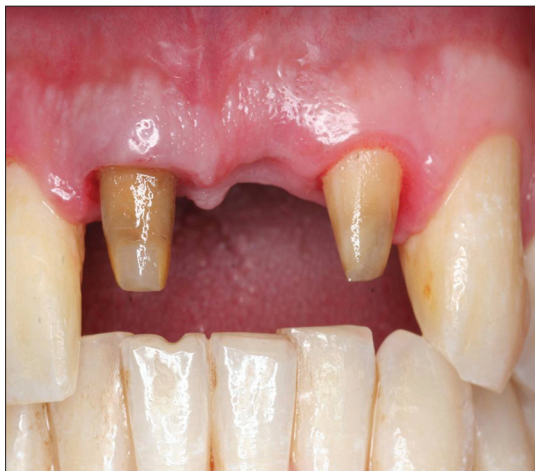

Figure 6: Intraoral view of the second case 2 weeks after extraction of the maxillary central incisor

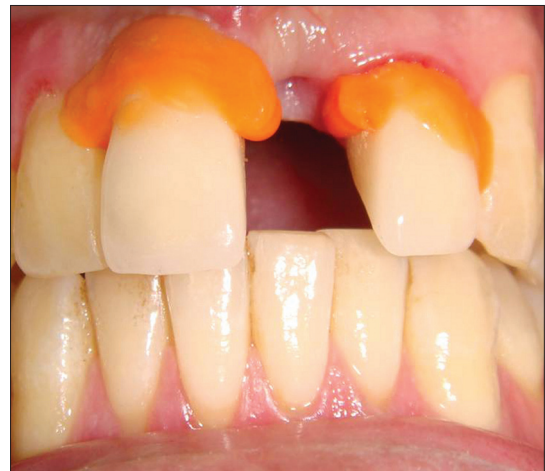

Figure 7: Turkom-Cera crowns were fixed with light-bodied elastomeric impression material

poured with type III stone (BEGO, Bremen, Germany). Veneering porcelains for the crown restorations were cut off from the cores, cleaned with a steam cleaner (Triton SLA; BEGO, Bremen, Germany), and ultrasonically dropped into ethyl acetate solution for 2 min. The proposed site for the new pontic was roughened with a grinding stone (BEGO) [Figure 9]. The new pontic was milled out from an alumina blank [Turkom-Ceramic (M) Sdn. Bhd.] and attached to the cores using alumina gel [Turkom-Ceramic (M) Sdn. Bhd.]. The resulting framework was sintered and glass infiltrated according to the manufacturer's instructions [Figure 10]. The fit of the framework was verified intraorally and veneered with veneering porcelain (Vita VM 7; VITA Zahnfabrik, Bad Säckingen, Germany). The FPD was cemented with a resin cement (Panavia F 2.0, Kuraray Medical Inc., Okayama, Japan) [Figure 11]. The patient has been followed up for a year and no complications have been reported.

DISCUSSION

The high esthetic expectations of patients have resulted in an increase in the use of ACRs in the stress-bearing areas.^[9-11] A clinician's ability to select the appropriate material, manufacturing technique, and cementation procedures to match intraoral conditions and esthetic requirements affects the success of the application of ACR materials.^[5] Alumina- and zirconia-based ceramics are the desirable materials for ACRs, particularly in high stress-bearing areas.^[4] High alumina-based ceramics, such as Turkom-Cera [Turkom-Ceramic (M) Sdn. Bhd.], have shown increased strength, but they are susceptible to fatigue failure that can considerably decrease their strength over time.^[3]

Although advances have been made in the dental materials and there is expanding use of all-ceramic systems, failure of ceramic restorations, especially chippings and fractures, is still a problem that is

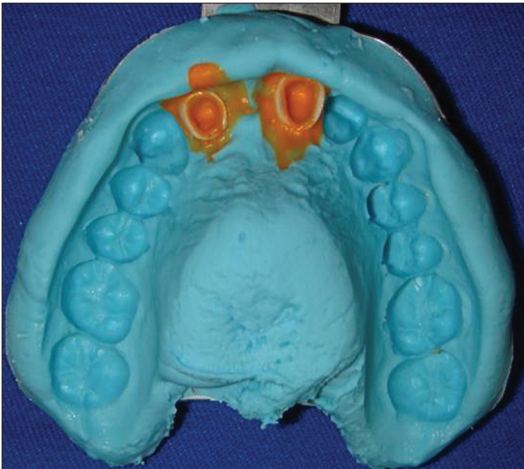


Figure 8: Impression of maxillary arch with crowns

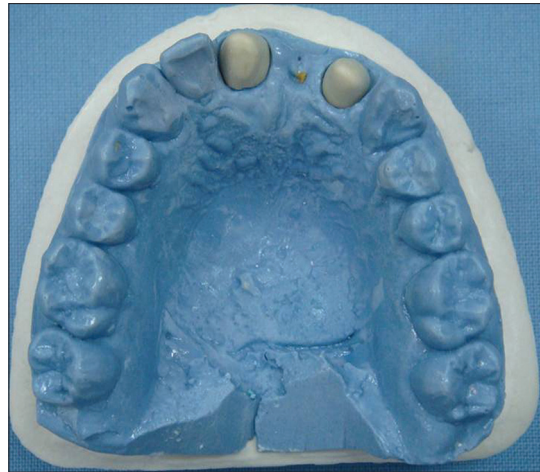

Figure 9: Veneering porcelains of crown restorations were cut off from the cores

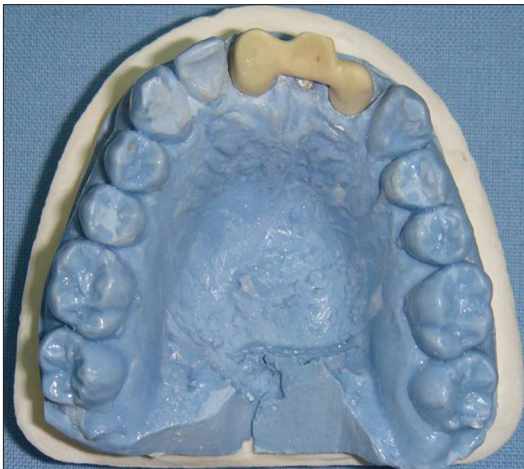

Figure 10: Addition of a new pontic to the Turkom-Cera cores

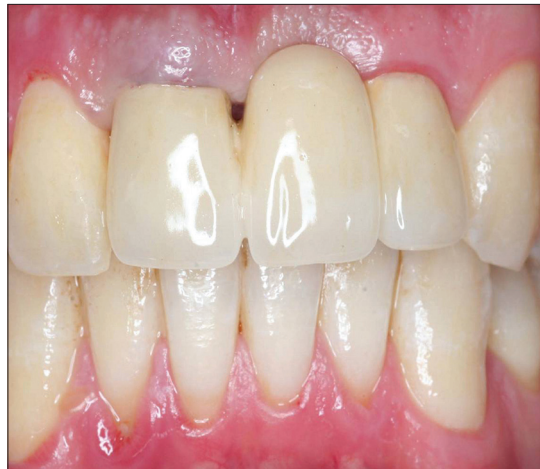

Figure 11: Final restoration of the second case

encountered.^[12-14] Therefore, there is an increased need for ceramic restoration repair for failed ACRs.^[15] Various repair techniques have been introduced instead of the re-constructing the prostheses because of the time-consuming procedure and higher cost.^[16-18] Thus, a myriad of studies have been reported on the repair of feldspathic,^[19-21] alumina-reinforced feldspathic,^[22] lithiumdisilicate glass,^[23,24] alumina,^[24] zirconia^[24] and leucite-reinforced feldspathic ceramics^[25,26] in the literature.

Repair techniques may be classified into two types, i.e. the direct technique and the indirect technique.^[16-18] Direct repair technique includes the use of composites that are applied directly to the fractured restoration,^[27,28] and indirect repair technique includes those that use porcelain that is applied as a laboratory procedure and is bonded to the fractured restoration.^[29,30] Miscellaneous techniques of repairing fractured porcelain with composite have been reported.^[16,27,28,31,32]

An all-ceramic alumina core material, Turkom-Cera [Turkom-Ceramic (M) Sdn. Bhd.], has been introduced in an attempt to provide a high-quality, high-strength, cost-effective coping that will result in improved clinical success,^[7,8] and it now provides new concepts for the repair of failed ACRs. The traditional techniques used to repair small amount of fractured porcelain. In contrast, Turkom-Cera [Turkom-Ceramic (M) Sdn. Bhd.] ACR system is used to repair large amounts of fractured porcelain or addition of a pontic to failed or final restorations. The primary advantages of this novel repair technique of Turkom-Cera [Turkom-Ceramic (M) Sdn. Bhd.] are its high strength and excellent wear qualities compared to direct repair technique with composite. Less chair time and lower cost are the other advantages of this technique. Disadvantages of this technique are technique-sensitive and difficult steps of the procedure.

CONCLUSION

This article describes two cases of the addition of a pontic to crown/bridge restorations. This technique is simple, feasible, time saving, and cost effective. Long-term clinical trials and mechanical studies are necessary to confirm the reliability of this novel technique.

REFERENCES

- Snyder MD, Hogg KD. Load-to-fracture value of different all-ceramic crown systems. *J Contemp Dent Pract* 2005;6:54-63.
- Bona AD, Mecholsky Jr. JJ, Barrett AA, Griggs JA. Characterization of glass-infiltrated alumina-based ceramics. *Dent Mater* 2008;24:1568-74.
- Al-Makramani BM, Razak AA, Abu-Hassan MI. Biaxial flexural strength of Turkom-Cera core compared to two other all-ceramic systems. *J Appl Oral Sci* 2010;18:607-12.
- Seghi RR, Sorensen JA. Relative flexural strength of six new ceramic materials. *Int J Prosthodont* 1995;8:239-46.
- Conrad HJ, Seong WJ, Pesun IJ. Current ceramic materials and systems with clinical recommendations: A systematic review. *J Prosthet Dent* 2007;98:389-404.
- Kim BK, Bae HE, Shim JS, Lee KW. The influence of ceramic surface treatments on the tensile bond strength of composite resin to all-ceramic coping materials. *J Prosthet Dent* 2005;94:357-62.
- Al-Makramani BM, Razak AA, Abu-Hassan MI. Effect of luting cements on the compressive strength of Turkom-Cera™ all-ceramic copings. *J Contemp Dent Pract* 2008;2:33-40.
- Al-Makramani BM, Razak AA, Abu-Hasan MI. Comparison of the load at fracture of Turkom-Cera to Procera AllCeram and In-Ceram all-ceramic restorations. *J Prosthodont* 2009;18:484-8.
- Blatz MB, Sadan A, Kern M. Resin-ceramic bonding: A review of the literature. *J Prosthet Dent* 2003;89:268-74.
- Kumbuloglu O, User A, Toksavul S, Vallittu PK. Intra-oral adhesive systems for ceramic repairs: A comparison. *Acta Odontol Scand* 2003;61:268-72.
- Conrad HJ, Seong WJ, Pesun IJ. Current ceramic materials and systems with clinical recommendations: A systematic review. *J Prosthet Dent* 2007;97:349-56.
- Bonfante EA, Sailer I, Silva NR, Thompson VP, Dianne Rekow E, Coelho PG. Failure modes of Y-TZP crowns at different cusp inclines. *J Dent* 2010;38:707-12.
- Harder S, Wolfart S, Eschbach S, Kern M. Eight-year outcome of posterior inlay-retained all-ceramic fixed dental prostheses. *J Dent* 2010;38:875-81.
- Abou Tar M, Eschbach S, Wolfart S, Kern M. Zirconia ceramic inlay-retained fixed dental prostheses – first clinical results with a new design. *J Dent* 2011;39:208-11.
- Blum IR, Nikolinakos N, Lynch CD, Wilson NH, Millar BJ, Jagger DC. An *in vitro* comparison of four intra-oral ceramic repair systems. *J Dent* 2012;40:906-12.
- Turkaslan S, Tezvergil-Mutluay A. Intraoral repair of all ceramic fixed partial denture utilizing preimpregnated fiber reinforced composite. *Eur J Dent* 2008;2:63-8.
- Appleby DC. Repair of fractured connectors in a provisional fixed partial denture. *J Prosthet Dent* 2001;84:449-50.
- Galiatsatos AA. An indirect repair technique for fractured metal-ceramic restorations: A clinical report. *J Prosthet Dent* 2005;93:321-3.
- Chen JH, Matsumura H, Atsuta M. Effect of different etching periods on the bond strength of a composite resin to a machinable porcelain. *J Dent* 1998;26:53-8.
- Haselton DR, Diaz-Arnold, Dunne JT. Shear bond strengths of 2 intraoral repair systems to porcelain or metal substrates. *J Prosthet Dent* 2001;86:526-31.
- Schmage P, Selcuk S, Nergiz I, Platzer U, Pfeiffer P. Shear bond strengths of five intraoral porcelain repair systems. *J Adhes Sci Technol* 2007;21:409-22.
- Özcan M, Valandro LF, Amaral R, Leite F, Bottino MA. Bond strength durability of a resin composite on a reinforced ceramic using various repair systems. *Dent Mater* 2009;25:1477-83.
- Kumbuloglu O, Lassila LV, User A, Toksavul S, Vallittu PK. Shear bond strength of composite resin cements to lithium disilicate ceramics. *J Oral Rehabil* 2005;32:128-33.
- Kim BK, Bae E, Shim JS, Lee KW. The influence of ceramic surface treatments on the tensile bond strength of composite resin to all-ceramic coping materials. *J Prosthet Dent* 2005;94:357-62.
- De Melo RM, Valandro LF, Bottino MA. Microtensile bond strength of a repair composite to leucite-reinforced feldspathic ceramic. *Braz Dent J* 2007;18:314-9.
- Fabianelli A, Pollington S, Papacchini F, Goracci C, Cantoro A, Ferrari M, *et al.* The effect of different surface treatments on bond strength between leucite reinforced feldspathic ceramic and composite resin. *J Dent* 2010;38:39-43.
- Bertolotti RL, Lacy AM, Watanabe LG. Adhesive monomers for porcelain repair. *Int J Prosthodont* 1989;2:483-9.
- Kupiec KA, Wuertz KM, Barkmeier WW, Wilwerding TM. Evaluation of porcelain surface treatments and agents for composite-to-porcelain repair. *J Prosthet Dent* 1996;76:119-24.

29. Barreto MT, Bottaro BF. A practical approach to porcelain repair. *J Prosthet Dent* 1982;48:349-51.
30. Chung K, Hwang Y. Bonding strengths of porcelain repair system with various surface treatments. *J Prosthet Dent* 1997;78:267-74.
31. Appeldoorn RE, Wilwerding TM, Barkmeier WW. Bond strength of composite resin to porcelain with newer generation porcelain repair systems. *J Prosthet Dent* 1993;70:6-11.
32. Cardoso AC, Spinelli Filho P. Clinical and laboratory techniques for repair of fractured porcelain in fixed prostheses: A case report. *Quintessence Int* 1994;25:835-8.

Access this article online	
Quick Response Code: 	Website: www.eurjdent.com
	Source of Support: Nil. Conflict of Interest: None declared