

Multiple oral ulcers leading to diagnosis of pulmonary tuberculosis

Vezhavendhan Nagaraj¹, Shanthi Sashy Kumar¹, Stalin Viswanathan², Sathish Kumar¹

¹Department of Oral Pathology, Indira Gandhi Institute of Dental Sciences, Mahatma Gandhi Medical College and Research Institute Complex, Pilaiyarkuppam, Pondicherry, India, ²Department of General Medicine, Indira Gandhi Medical College and RI, Kathirkamam, Pondicherry - 605 009, India

Correspondence: Dr. Stalin Viswanathan
Email: stalinviswanathan@gmail.com

ABSTRACT

We report a 47 year old man who presented with painful non-healing tongue ulcers of 3 months duration. Examination revealed an additional buccal ulcer that he was unaware of. Histopathology of the ulcers showed caseation necrosis. Following this report, chest radiography and sputum microscopy performed revealed pulmonary tuberculosis. From this case-study, one should be aware of coexisting pulmonary tuberculosis in patients with chronic non-healing oral ulcers, both for diagnosis as well as prevention of transmission through respiratory droplets.

Key words: Oral cavity tuberculosis, oral ulcers, tongue tuberculosis

INTRODUCTION

Tuberculosis (TB) is a chronic granulomatous infectious disease due to *Mycobacterium tuberculosis* that afflicts increasing number of people every year and has the highest mortality among treatable infectious diseases. [1] Tuberculosis can either be primary or secondary and can involve any part of the body. The oral cavity is an unusual site to be affected in tuberculosis and is generally due to secondary infection. These lesions manifest as non-healing ulcers, nodules, fissures, verrucous proliferation, erythematous patches or plaques, indurated lesions, or as jaw lesions. [2] Among these, ulcers and papillomas are the commonest form and usually present as single lesions. [1] Tuberculous ulcers involving multiple sites in the oral cavity are rare. Herein we report one such case with multiple oral ulcers as initial presenting complaint of tuberculosis.

CASE REPORT

This 47-year-old male presented with a non-healing

tongue ulcer of 3 months' duration and associated pain for 2 months. He had initially noticed the asymptomatic ulcer on the ventral surface of tongue which had been increasing in size for the last 1 month. He had smoked *beedis* for the last 20 years and had consumed alcohol daily for past 15 years. On examination, ulcers were noticed in the tongue and buccal mucosa. A solitary ulcer (3 cm × 4 cm) with undermined edges and minimal induration was seen on right ventral surface of the tongue extending from the midline past the lateral border, up to the dorsal area of the anterior two-thirds of the tongue [Figure 1a]. The area adjacent to the tongue ulcer appeared to be lobulated. Another ulcer (0.5 cm × 0.5 cm), also with an undermined edge was seen on the dorsal surface of tongue. In the left buccal mucosa, a single ulcer (1 × 1 cm²) covered with pseudomembrane was present, extending 3 cm from the angle of the mouth and 5 mm below the occlusal plane [Figure 1b]. The patient was not aware of this ulcer. A single firm, non-tender (<1 cm) sub-mandibular lymph node was present on the right side.

How to cite this article: Nagaraj V, Sashy Kumar S, Viswanathan S, Kumar S. Multiple oral ulcers leading to diagnosis of pulmonary tuberculosis. Eur J Dent 2013;7:243-5.

Copyright © 2013 Dental Investigations Society.

DOI: 10.4103/1305-7456.110197

Provisional diagnoses of squamous cell carcinoma and lichen planus were given for the lesions of the tongue and buccal mucosa, respectively. Incisional biopsy from the edge of tongue ulcer revealed proliferating epithelium with the underlying connective tissue exhibiting chronic inflammatory cell infiltrate without evidence of epithelial dysplasia or malignant invasion. Biopsy was repeated from a different area of the tongue ulcer for further review. On examining serial sections, giant cells with peripherally arranged nucleus resembling Langerhans cells were appreciated along with caseous necrosis [Figure 1c]. Chest radiography revealed bilateral upper lobe infiltrates [Figure 1d], and sputum was positive for acid-fast bacilli. HIV was negative. With anti-tuberculous therapy the lesions began to heal on a follow-up visit a month later. He was referred to local primary health care center for continuation of therapy.

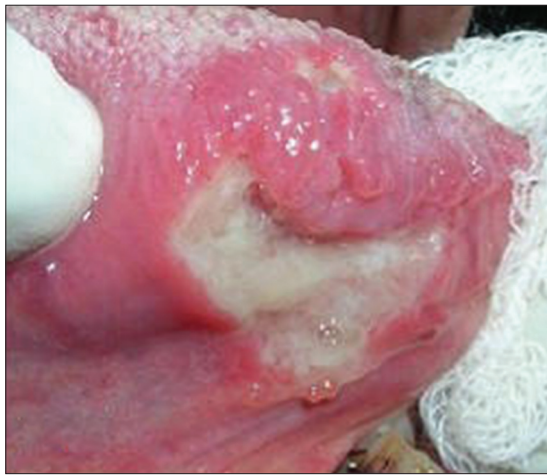

Figure 1a: Tongue ulcers- a larger ventral ulcer and a smaller ulcer superiorly, both with undermined edges

DISCUSSION

The WHO estimates that 80% of fatalities arising from TB occur in developing countries.^[2] The prevalence in India is reported to be 5.05 per 1,000.^[3] Oral tuberculosis on the other hand, accounts for 0.2 to 1.5% of all cases of extra-pulmonary tuberculosis.^[4] Tuberculous infection can either be primary or secondary; the primary form affects the lungs lymph nodes, meninges, kidneys, bones, and skin. The secondary form occurs due to spread of infection from other parts of body.^[5] Two types of presentation are seen in oral TB: Primary lesions occurring as a result of direct inoculation of oral tissues^[6] and secondary infection occurring due to haematogenous or lymphatic spread or from direct extensions from neighboring structures.^[2,6]

Primary tuberculosis presenting as oral lesions are uncommon, since factors like an intact oral mucosa, salivary enzymes, and tissue antibodies act as barriers

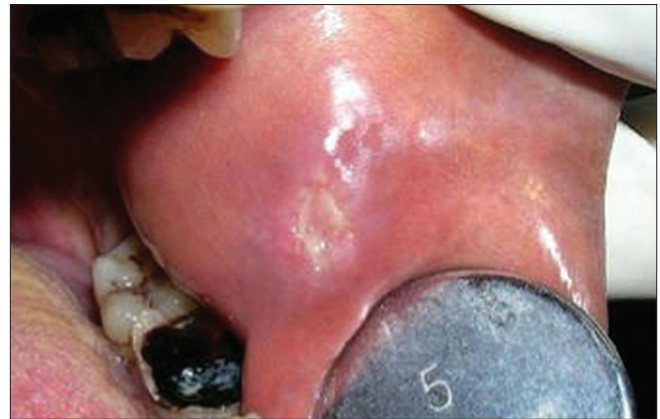

Figure 1b: Left buccal mucosal ulcer covered with pseudomembrane

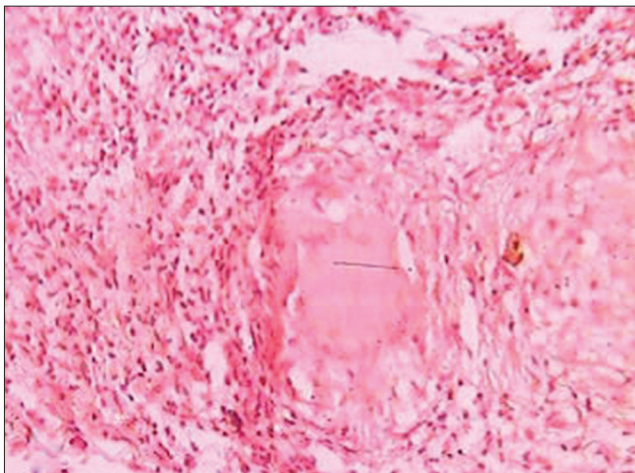


Figure 1c: Histopathology of tongue ulcer showing chronic inflammatory infiltrate surrounding the caseation necrosis

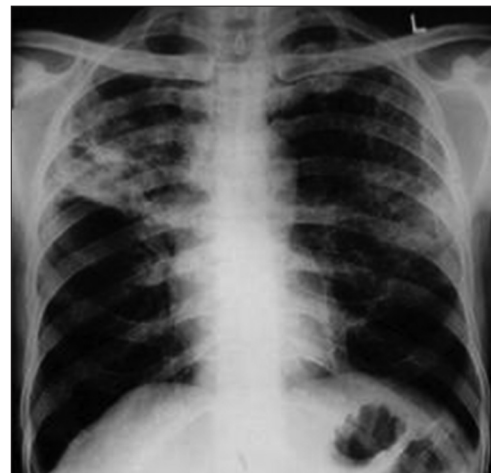

Figure 1d: Chest radiography revealing bilateral upper-lobe infiltrates suggestive of tuberculosis

to infection. Both systemic and local factors play a role in incidence of oral lesions. Systemic factors include lowered host resistance and increased virulence of the organisms.^[4,7] Local factors comprises poor oral hygiene, local trauma, chronic inflammation, tooth eruption, extraction sockets, periodontal disease, carious teeth with pulp exposure^[7] and presence of lesions like leukoplakia, dental cysts, dental abscesses, and jaw fractures. Any breach in the mucosal lining predisposes toward oral involvement.^[5] Oral tuberculosis affect the gingiva, floor of the mouth, palate, lips, buccal folds, tooth sockets, and jaw bones, with the tongue being the commonest site.^[6,8] Sometimes, oral ulcers may follow opalescent vesicles or nodules which may break down as a result of caseation necrosis to form an ulcer. Ulcers apart, tubercular tongue lesions present as tuberculoma, tuberculous fissure, tubercular papilloma, diffuse glossitis, or atubercular cold abscess.^[7] The dorsal surface of the tongue is more commonly involved.^[3]

Oral tuberculosis is to be differentiated from traumatic lesions, granulomatous disease, syphilis, aphthous ulcers, mycotic infections, sarcoidosis, Crohn's disease, deep mycoses, cat-scratch disease, foreign-body reactions, and malignancies.^[5,8,9] Diagnosis of tuberculosis is based on clinical findings, sputum microscopy and radiography.^[5,8] Recent development of DNA probes, polymerase chain reaction assays, and liquid media now allow more sensitive and rapid diagnosis.^[4] Occasionally, the recognition of oral tuberculosis precedes the detection of PTB like in our patient. Our patient did not have respiratory or constitutional symptoms to consider tuberculosis initially. Histopathological diagnosis was complemented by chest radiography and sputum microbiology in our case.

CONCLUSION

Multiple oral ulcers are a rare presenting complaint of tuberculosis in a patient with simultaneous pulmonary TB but without clinical symptoms. In our case, diagnosis of pulmonary TB was considered only after reviewing multiple histopathology sections of the tongue ulcer. In a dental outpatient setup, caution is needed while dealing with such ulcers not only to miss an important medical entity but in also to prevent transmission of infection to dental staff through respiratory droplets.

REFERENCES

1. Challacombe S, Chidzonga M, Glick M, Hodgson T, Magalhães M, Shiboski C, *et al.* Global oral health inequalities: Oral infections-challenges and approaches. *Adv Dent Res* 2011;23:227-36.
2. Baghirath PV, Krishna AB, Ashalata, Reddy PS. Primary tuberculous osteomyelitis of the mandible- a rare case report. *Oral Maxillofac Pathol J* 2011;2:117-22.
3. Gupta PP, Fotedar S, Agarwal D, Sansanwal P. Primary tuberculous glossitis in an immunocompetent patient. *Hong Kong Med J* 2007;13:330-1.
4. Ebenezer J, Samuel R, Mathew GC, Koshy S, Chacko RK, Jesudason MV. Primary oral tuberculosis: Report of two cases. *Ind J Dent Res* 2006;17:41-4.
5. Kataria SP, Singh S, Parul T, Kumar S, Singh G. Primary tuberculosis of the tongue in an immunocompetent patient: A case report *Asian Pacific J Trop Dis* 2012;2:78-9.
6. Mahajan S, Srikant N, George T. Atypical Presentation of Oral Tuberculosis Ulcer. *New York State Dent J* 2007;73:48-50.
7. Kumar S, Sen R, Rawal A, Dahiya RS, Dalal N, Kaushik S. Primary Lingual Tuberculosis in Immunocompetent Patient: A Case Report. *Head Neck Pathol* 2010;4:178-80.
8. Von Arx DP, Husain A. Oral tuberculosis. *Br Dent J* 2001;190:420-2.
9. Bhat P, Mehndiratta A, D'Costa L, Mesquita AM, Nadkarni N. Tuberculosis of tongue: A case report. *Ind J Tub* 1997;44:31-3.

Access this article online	
Quick Response Code: 	Website: www.eurjdent.com
Source of Support: Nil. Conflict of Interest: None declared	