

The total occlusal convergence of the abutment of a partial fixed dental prosthesis: A definition and a clinical technique for its assessment

John S. Mamoun¹

Correspondence: Dr. John S. Mamoun
Email: mamounjo@gmail.com

¹Private Practice, General Dentistry,
Manalapan, NJ, USA

ABSTRACT

The abutment(s) of a partial fixed dental prosthesis (PFDP) should have a minimal total occlusal convergence (TOC), also called a taper, in order to ensure adequate retention of a PFDP that will be made for the abutment(s), given the height of the abutment(s). This article reviews the concept of PFDP abutment TOC and presents an alternative definition of what TOC is, defining it as the extent to which the shape of an abutment differs from an ideal cylinder shape of an abutment. This article also reviews experimental results concerning what is the ideal TOC in degrees and explores clinical techniques of estimating the TOC of a crown abutment. The author suggests that Dentists use high magnification loupes ($\times 6-8$ magnification or greater) or a surgical operating microscope when preparing crown abutments, to facilitate creating a minimum abutment TOC.

Key words: Convergence, dentistry, microscopes, occlusal, taper, total

INTRODUCTION

The total occlusal convergence (TOC) of a partial fixed dental prosthesis (PFDP) abutment has been defined as “the convergence of two opposing external walls of a tooth preparation as viewed in a given plane”^[1-4] and also “the angle between a single preparation wall and the long axis of the preparation.”^[2] TOC defined by the first definition would be double the angle defined in the second.^[2]

PFDP retention is optimal when abutment TOC does not exceed $6-8^\circ$ along the abutment perimeter.^[5-12] Abutment retention decreases asymptotically as the TOC increases.^[5] Modifying an over-converged abutment by reducing the TOC at the cervical 1/3 of the abutment improves abutment retention significantly more compared with incorporating auxiliary retentive grooves or boxes into an abutment.^[13,14] This article provides an alternative definition and concept of TOC^[1-4] and explores clinical techniques of estimating TOC.

DEFINITION OF TOC

TOC may alternatively be defined as the extent to which the axial aspect of the abutment differs in angle from an imaginary, ideal cylinder shape, where the axial aspect of the abutment is prepared as a cylinder and the base perimeter of this cylinder is the perimeter of the most apical aspect of the axial aspect of the abutment.

There are several types of cylinders: with a “right, circular” cylinder, the axis of the cylinder is at a right angle to a circular cylinder base; with an “oblique, circular” cylinder, the base of the cylinder is a circle, but the cylinder axis is not at a right angle to the base; with an “oblique, generalized” cylinder, the base is a circumscribed shape, but not a circle and the cylinder axis is not at a right angle to the base.

If an abutment can be shaped into a cylinder, it is generally shaped into an oblique, generalized cylinder, since a tooth is usually inclined at a non-right angle and

How to cite this article: Mamoun JS. The total occlusal convergence of the abutment of a partial fixed dental prosthesis: A definition and a clinical technique for its assessment. *Eur J Dent* 2013;7:509-13.

Copyright © 2013 Dental Investigations Society.

DOI: 10.4103/1305-7456.120665

its perimeter at the cemento-enamel junction is usually not circular. However, it is generally impossible, even when using microscopes, for a dentist to shape the axial aspect of the PFDP abutment into a cylinder.^[9,10,15] Some teeth have a naturally converging emergence profile or feature a supra-coronal concavity or require two-plane reduction. The gingival aspect of such teeth could perhaps be shaped into a cylinder, while the occlusal aspect perhaps cannot.

Hence, the axial aspect of a real-life abutment is typically prepared into a conical shape that converges in a gingival to occlusal direction. Geometrically, this shape is a frustum or a “three-dimensional trapezoid,” with the top part truncated and planed instead of pointy. The abutment frustum would be compared to and fit inside, an imaginary, ideal, zero TOC cylinder abutment.

If an uncut tooth flares outwardly all around, its entire axial aspect can be prepared into a one-plane reduction abutment. The minimum amount of reduction that can result in a cylinder abutment is a single plane reduction, with a feather edge finish line, where essentially only the heights of contour of a tooth are reduced. Of course, the dentist as is needed further prepares axially into this minimum cylindrical form to create shoulder or chamfer margins or to create space on the facial aspect for placement of porcelain for the type of PFDP required.

DIVIDING THE ABUTMENT PERIMETER INTO INFINITE IMAGINARY LINE SEGMENTS

Instead of describing the TOC of an abutment as the angle of an ambiguous entity, the “wall” of an abutment, one can divide up the axial aspect of the abutment into infinite vertical line segments. This way, one can describe TOC as the average angle of an infinite number of line segments emanating from specific points along the perimeter of the most apical extent of the axial aspect of the abutment (the “abutment axial perimeter”).

A dentist can imagine an ideal, cylinder abutment, where the perimeter of the cylinder base is the same as the abutment apical perimeter. If an imaginary plane is produced that is tangent to this imaginary, ideal cylinder abutment and intersects a point along the cylinder base perimeter, the intersection of the tangent plane and the cylinder forms a tangential line segment. This tangential line segment originates at

that point along the cylinder perimeter and continues vertically to the top of the cylinder. An infinite number of such tangent line segments can be produced, one for each point along the cylinder base perimeter. Since these infinite tangent line segments collectively form a cylinder, the angles of all of the tangent line segments produced from these tangent planes are the same, such that all of these individual tangent line segments are parallel with one another.

Furthermore, with the actual abutment that has a frustum shape, if the axial aspect consists of a single plane reduction around the entire perimeter of the abutment, an imaginary tangent plane can be created that intersects the axial aspect of the abutment at a single point on the abutment apical perimeter. This intersection forms a tangential line segment that continually contacts the surface of the abutment from that perimeter point to the occlusal aspect of the abutment.

This tangential line segment formed on the actual abutment axial aspect forms an angle with the imaginary tangential line segment formed on the imaginary ideal cylinder form of the axial aspect of the abutment, where the apex of the two line segments is the point on the perimeter that they both originate from. The angle of these two line segments is the value of the convergence angle of the axial aspect of abutment at that point along the abutment apical perimeter. The average angle of all of the tangential line segment pairs that can be formed for each point along the abutment apical perimeter is essentially the TOC angle of the axial aspect of the abutment and is a measure of the extent to which the axial aspect of the actual abutment differs from an ideal, cylindrical abutment [Figure 1]. If the axial aspect of the abutment has a two-plane reduction, a tangential plane can be imagined that is tangent to an imaginary “best fit approximation” line that “averages” the angle formed by the two planes of reduction at that perimeter point [Figure 2].

GEOMETRICAL “ANATOMY” OF AN ABUTMENT

There is a certain “anatomy” to a PFDP abutment that is relevant to determining the TOC of an abutment. The axial aspect of the abutment is the longitudinal aspect of the abutment, excluding any finish line components such as a chamfer or a shoulder. The axial aspect of an abutment with a single plane reduction extends occlusally until an occlusal bevel begins,

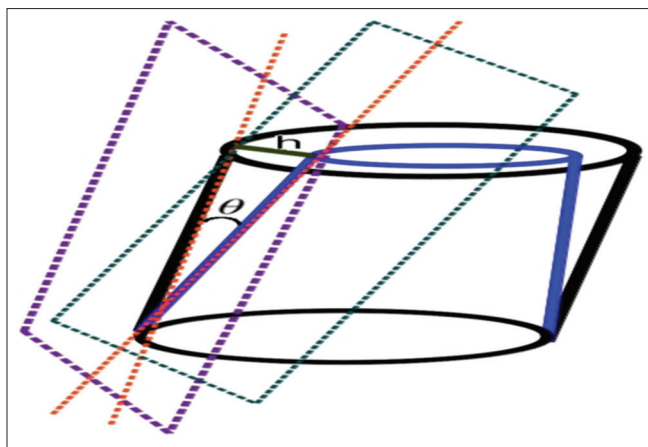


Figure 1: Two planes, one tangentially intersecting an imaginary ideal cylinder abutment, the other tangentially intersecting an actual abutment, form two tangent line segments emanating from one point along the abutment perimeter, the angle between them quantifying the convergence angle at that point. “h” is the visually apparent horizontal distance between the two line segments when abutment is viewed using an apically directed viewing perspective

that begins the transition from the axial aspect of the abutment to the occlusal surface of the abutment. If an abutment has a two plane reduction, the gingival plane reduction extends occlusally until the axial aspect of the abutment transitions into a second, occlusal plane of reduction. In addition, two perimeters are relevant to determining the TOC of the abutment. One is the perimeter of the axial aspect of the abutment at its most apical extent, excluding any finish line components such as a chamfer or shoulder. The second perimeter is the perimeter of the axial aspect of the abutment at its most occlusal extent and is located just apical to an occlusal bevel of the axial aspect of an abutment that has a single plane reduction abutment (the “abutment occlusal perimeter”). If the abutment has a two plane reduction, the perimeter of the axial aspect of the abutment is located just apical to an occlusal bevel of the second, occlusal plane of reduction [Figure 3].

CLINICAL METHOD OF ASSESSING ABUTMENT TOC

If a dentist views a non-undercut, one-plane reduction abutment with one eye closed, using an apically-directed viewing axis, such that the dentist can see all points along the abutment apical perimeter, the dentist is essentially observing the abutment using a visual axis that is parallel with the axes of the path of placement that the abutment provides.^[1,16]

The dentist can also observe, in this viewing perspective, the complete abutment occlusal perimeter and also what appears to be a horizontal distance separating the apical

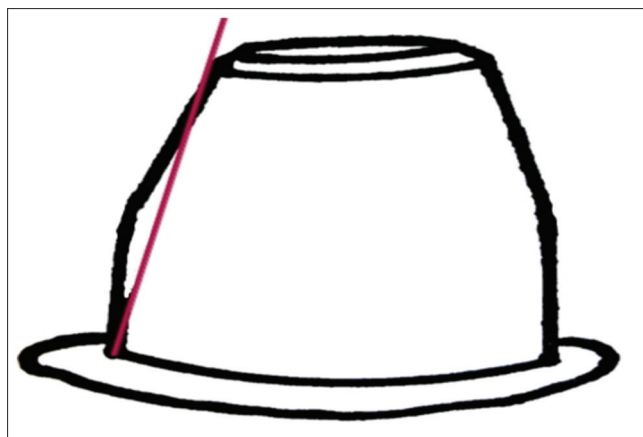


Figure 2: Imaginary “best fit” line averaging the angle of two planes of reduction at a specific point along the apical perimeter of the axial aspect of abutment

and occlusal perimeters [Figure 4]. If the horizontal distance separating these two perimeters is in general zero, then the abutment axial aspect is prepared with an ideal TOC or a 0° convergence characteristic of a cylinder abutment. If the horizontal distance observed is more than zero, then the abutment has a convergence. The average width of this observed horizontal distance, as observed for all points around the perimeter of the axial aspect of the abutment, is essentially equivalent to the TOC of the axial aspect of the abutment. Observing this horizontal distance is perhaps the most efficient and accurate way for a Dentist to assess the average TOC of the axial aspect of an abutment, since this allows a dentist to visually estimate the convergence angle of all of the points along the apical perimeter of the axial aspect of the abutment simultaneously.

Microscope-level magnification, combined with shadow-free, co-axial illumination, facilitates observing tiny, close to zero, visually apparent horizontal distances between the abutment apical perimeter and the abutment occlusal perimeter. Microscopes facilitate verifying that there are no undercuts along the abutment apical perimeter of an abutment that has a minimum TOC, even if the abutment appears foreshortened in the viewing perspective used to view the abutment.

ONE SINGLE, VERSUS MULTIPLE PARALLEL, VIEWING PERSPECTIVES WHEN ASSESSING TOC

A dentist may, using microscopes, be able to prepare a narrow tooth, such as a mandibular incisor or thin premolar, to a near-cylindrical abutment TOC and yet be able to observe all abutment apical perimeter

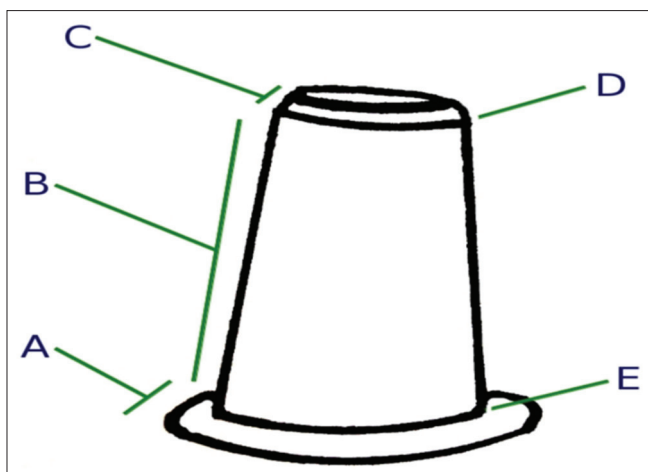


Figure 3: Abutment “anatomy” relevant to analyzing total occlusal convergence includes (A) horizontal aspect of the abutment margin; (B) axial aspect of the abutment; (C) occlusal bevel of the abutment axial aspect; (D) occlusal perimeter of the axial aspect of the abutment; (E) and apical perimeter of the axial aspect of the abutment

points using only a single visual axis, to verify that the preparation is not undercut.

However, if the tooth is wide, such as a large molar, or if the dentist is preparing multiple abutments for a PFDP, the Dentist cannot prepare the abutment(s) such that only a single visual axis allows viewing of all abutment apical perimeter points, unless the Dentist severely over-converges the abutment(s). An extreme example of an over-converged abutment is the so-called “teepee” abutment, where the abutment converges to a point, resulting in a large visually perceived horizontal width between the occlusal “margin” (which is just a point) and points along the abutment apical perimeter [Figure 4].

Theoretically, only 1 point along the abutment apical perimeter of a cylinder abutment(s) can be seen per viewing axis that the Dentist uses to view the abutment(s), since the axial aspect of the cylinder would block a view of other perimeter points. The Dentist must therefore use multiple viewing axes to see all points along the abutment(s) apical perimeter and view the abutment(s) with such precision that each viewing axis is the same angle in 3D space as the other viewing axes.^[16] Microscopes facilitate this viewing precision, allowing a Dentist to prepare wide or multiple abutments with minimal TOC.

MISLEADING TO TRY TO ASSESS TOC USING BUCCAL OR LINGUAL VIEWING PERSPECTIVES

Assessing abutment TOC by viewing an abutment using an occlusal viewing perspective is arguably

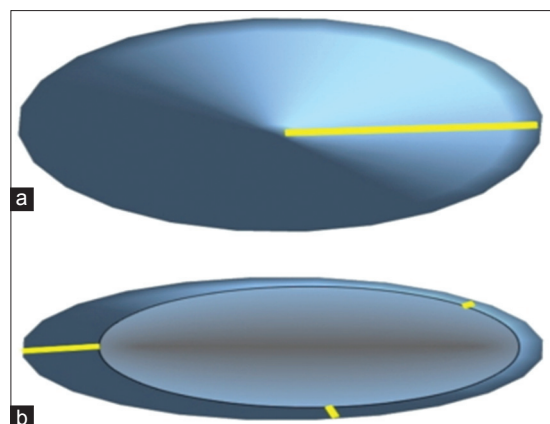


Figure 4: Pointy cone “teepee” abutment (a) shows a long visually apparent horizontal distance (yellow line) between the abutment apical perimeter and the abutment occlusal “perimeter” (which is just a point), when compared to a less tapered frustum abutment (b), when the abutments are viewed using an apically directed viewing axis in which all points along the abutment apical perimeters are visible. Abutment examples drawn as single-plane reduction abutments with no occlusal bevels

more accurate than attempting to estimate the TOC of an abutment by viewing the abutment from the buccal or the lingual, or by comparing the TOC of the abutment to a thin, straight reference,^[17] like a periodontal probe held next to the abutment and perpendicular to the occlusal plane.

First, for any one single buccal viewing perspective, only two converging line angles of the abutment axial aspect appear visible. Therefore, the dentist cannot easily assess the overall TOC of the abutment and cannot compare the convergence angle of one point with the convergence angles of all of the other points.

Second, it is possible for the abutments of a multi-unit PFDP to be optimally tapered and yet, on an individual abutment of this PFDP, there may be a point that appears excessively tapered when the abutment is viewed from a buccal or lingual perspective. This can occur if one abutment was naturally tilted, such that this abutment would interfere with the path of placement of the PFDP if this abutment was prepared into a cylinder. When the abutments are viewed from the side, the Dentist may think that the abutment(s) are over-converged based on viewing a few perimeter points that appear heavily converged. Yet, if the abutments are viewed using apically-directed viewing axes that are parallel to the axes of the path of placement that the abutments provide, the observed horizontal distance between the abutment apical and occlusal perimeters may appear to be close to zero, implying an optimal TOC of the abutments.

CONCLUSION

This paper defines TOC as the extent to which an abutment differs in angle from an imaginary, ideal cylinder abutment form. The convergence angle at a specific point along the abutment apical perimeter is determined by the angle between imaginary tangent lines formed by imaginary planes tangentially intersecting, respectively, the abutment and an imaginary ideal cylinder abutment shape, at that point along the abutment apical perimeter. A suggested clinical method of assessing abutment(s) TOC is to view the abutment(s) using apically-directed viewing axes that are parallel with the axes of the path of placement provided by the abutment(s) and then to assess the average horizontal distance between the abutment apical and occlusal perimeters that becomes visually apparent in these viewing perspectives.

REFERENCES

1. Shillingburg HT, Jacobi R, Brackett S, Hobo S, Whitsett LD. Fundamentals of fixed prosthodontics. 3rd ed. Chicago: Quintessence Publishing; 1997. p. 124-6, 338-40.
2. Blair FM, Wassell RW, Steele JG. Crowns and other extra-coronal restorations: Preparations for full veneer crowns. Br Dent J 2002;192:561-4, 567.
3. The glossary of prosthodontic terms. J Prosthet Dent 1999;81:39-110.
4. Rosenstiel SF, Land MF, Fujimoto J. Contemporary fixed prosthodontics. 4th ed. St. Louis: Mosby; 2006.
5. Jørgensen KD. The relationship between retention and convergence angle in cemented veneer crowns. Acta Odontol Scand 1955;13:35-40.
6. Shillingburg HT, Hobo S, Fisher DW. Preparations for cast gold restorations. 1st ed. Chicago: Quintessence Publishing Co., 1987.
7. Kaufman EG, Coehlo DH, Colin L. Factors influencing the retention of cemented gold castings. J Prosthet Dent 1961;11:487-502.
8. Parker MH, Calverley MJ, Gardner FM, Gunderson RB. New guidelines for preparation taper. J Prosthodont 1993;2:61-6.
9. Ohm E, Silness J. The convergence angle in teeth prepared for artificial crowns. J Oral Rehabil 1978;5:371-5.
10. Mack PJ. A theoretical and clinical investigation into the taper achieved on crown and inlay preparations. J Oral Rehabil 1980;7:255-65.
11. Noonan JE Jr, Goldfogel MH. Convergence of the axial walls of full veneer crown preparations in a dental school environment. J Prosthet Dent 1991;66:706-8.
12. Nordlander J, Weir D, Stoffer W, Ochi S. The taper of clinical preparations for fixed prosthodontics. J Prosthet Dent 1988;60:148-51.
13. Roudsari RV, Satterthwaite JD. The influence of auxiliary features on the resistance form of short molars prepared for complete cast crowns. J Prosthet Dent 2011;106:305-9.
14. Proussaefs P, Campagni W, Bernal G, Goodacre C, Kim J. The effectiveness of auxiliary features on a tooth preparation with inadequate resistance form. J Prosthet Dent 2004;91:33-41.
15. Ayad MF, Maghrabi AA, Rosenstiel SF. Assessment of convergence angles of tooth preparations for complete crowns among dental students. J Dent 2005;33:633-8.
16. Mamoun J. Preparing fixed partial denture abutments such that they provide a path of placement free of undercuts. Gen Dent 2012;60:519-25.
17. Patil PG. Modified measuring compass as an intraoral paralleling device. Indian J Dent Res 2010;21:452-3.

Access this article online

Quick Response Code:



Website:
www.eurjdent.com

Source of Support: Nil.
Conflict of Interest: None declared

Announcement

iPhone App



A free application to browse and search the journal's content is now available for iPhone/iPad. The application provides "Table of Contents" of the latest issues, which are stored on the device for future offline browsing. Internet connection is required to access the back issues and search facility. The application is Compatible with iPhone, iPod touch, and iPad and Requires iOS 3.1 or later. The application can be downloaded from <http://itunes.apple.com/us/app/medknow-journals/id458064375?ls=1&mt=8>. For suggestions and comments do write back to us.