

# A different wax sculpture technique for implant-retained auricular prosthesis

Necla Demir<sup>1</sup>, Pınar Cevik<sup>2</sup>, Yener Okutan<sup>1</sup>, A. Nilgun Ozturk<sup>1</sup>, Bahar Colpan<sup>3</sup>

**Correspondence:** Dr. Necla Demir  
Email: necladt@gmail.com

<sup>1</sup>Department of Prosthodontics, Selcuk University, Konya, Turkiye,

<sup>2</sup>Department of Prosthodontics, Gazi University, Ankara, Turkiye,

<sup>3</sup>Department of Autorhinolaryngology, Selcuk University, Konya, Turkiye

## ABSTRACT

Replacement of missing ears is a challenging task in which extensive array of materials and techniques have been employed. This article describes a different and simplified procedure for fabricating auricular prostheses very similar to the intact left ear of the patient. A 65-year-old male patient was referred to the Department of Prosthodontics with the loss of the right ear. In this case, the impression was made using hydrocolloid material (alginate) from the both defected and the opposite side. After hardening of the stone casts, a custom-made transparent splint plate was designed for the left auricular side. The splint was reversed and a cast model of the right auricular side was obtained as pouring the dental stone into transparent orthodontic splint. After getting the impression from cast model, conventional wax pattern and try on process was done. Finally, silicone elastomer was polymerized and the retention of the prosthesis acquired with the magnetic attachments. The technique described is economical, conventional, and time-saving. Furthermore, the prosthesis imitates the patient's intact auricular tissue.

**Key words:** Auricular prosthesis, implant retained prosthesis, magnet attachment, osseointegrated auricular implants

## INTRODUCTION

Malignant tumors of the auricula and periauricular area represent 7% of all cutaneous tumors. They appear mostly in the sixth and seventh decade. According to histological type, they are basocellular and planocellular carcinomas. These tumors recur and develop metastases more often than tumors in other sites. Because of this and because of surrounding vital structures, these tumors have a poor prognosis. Surgical therapy, that is, wide excision, is better than radiotherapy.<sup>[1,2]</sup> Basocellular carcinoma surgical defects can be emotionally traumatizing considering the societal emphasis on physical appearance.<sup>[1,2]</sup> The aim of maxillofacial rehabilitation should provide a suitable prosthesis for patients with facial defects, so that they are rehabilitated back to the society to face and accept the challenges of life.<sup>[3,4]</sup>

The use of implants can eliminate or minimize the need for adhesive and allows for proper orientation and seating of auricular prosthesis by the patient.<sup>[5-10]</sup> The implants can vastly improve the retention and

stability of a facial prosthesis. However, a satisfactory outcome may be only achieved by careful planning in terms of the number, position, and orientation of the implants, and the proper connection of the auricular prosthesis. Many retention options have been used to retain ear prosthesis such as bar/clip attachments, magnets, composite bar and magnets and ball and socket attachments.<sup>[3,11-13]</sup> An implant-retained auricular prosthesis provides multiple advantages for the patient: Convenience, security, consistent retention and positioning, elimination of the need for adhesives, and maintenance of marginal integrity.<sup>[14-17]</sup> Specifically,

This is an open access article distributed under the terms of the Creative Commons Attribution-NonCommercial-ShareAlike 3.0 License, which allows others to remix, tweak, and build upon the work non-commercially, as long as the author is credited and the new creations are licensed under the identical terms.

**For reprints contact:** reprints@medknow.com

**How to cite this article:** Demir N, Cevik P, Okutan Y, Ozturk AN, Colpan B. A different wax sculpture technique for implant-retained auricular prosthesis. *Eur J Dent* 2015;9:433-7.

**DOI:** 10.4103/1305-7456.163231

they eliminate disengagement caused by surrounding soft tissue movement or perspiration, which can result in loss of contact of silicone prosthesis margins.<sup>[15]</sup>

Literature is replete with various techniques describing the impression technique of the natural and the defective ear. In addition, the impression of the normal ear is equally important as it serves as a guide to construct a pattern. Making of impression of a normal ear is difficult as the helix may get distorted under the weight of the impression material.<sup>[18]</sup> This technique duplicates the defect side as that of normal ear and its relationship to the surrounding ear. This article describes a novel method in the case of losing only one ear, a replica of the existing ear is duplicated in wax and used to fabricate the auricular prosthesis more esthetic and in a shorter time. However, it takes time for fabrication of a wax sculpture and consequently increase the treatment time. This proposed technique includes flipping the orthodontic transparent splint to the opposite side and relating the wax sculpture to the fixed anatomical features on the face of patient.

## CASE REPORT

A 65-year-old man whose right ear was totally resected due to the basal cell carcinoma diagnosis of the tumoral lesion. After the healing process, he was referred by his plastic surgeon to the Prosthodontic Clinic at the University of Selcuk.

Three magnet attachments (3.3/5.5 SLA, 4 mm EO implant, Straumann, AG, Switzerland) were placed on the temporal bone by plastic surgeon. After soft tissue healing and osseointegration is confirmed, 5.5 mm abutments were inserted [Figure 1].

Hair adjacent to the ear was coated with petroleum jelly (Vaseline; Chesebrough-Pond's USA Co, Greenwich, CT), and placed cotton in the ear canal. Three materials (magnet attachment, impression cap, and implant analog) were used in the construction procedure of the auricular prosthesis. After the three impression, caps (Straumann AG) were connected to abutment replicas; impression of the auricular defect was made with condensation reaction silicone impression material (Zetaplus, Zhermack, Badia Polesine, Italy) [Figure 2]. The impression is boxed and die stone is poured into the impression.

The ear pattern was created by a different and original technique compared with "donor" technique. The

impression of the healthy left ear was made with alginate impression material and the cast model was prepared. The soft retainer orthodontic plate (UMG, UMG Uysal Medical, Istanbul, Turkey) was adapted

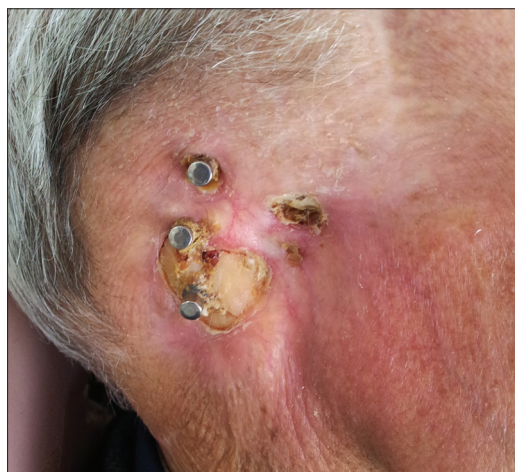

Figure 1: Right auricular defect with extraoral implants

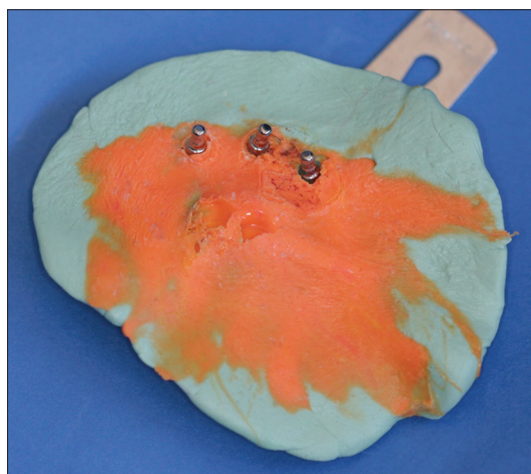


Figure 2: Impression of the defect

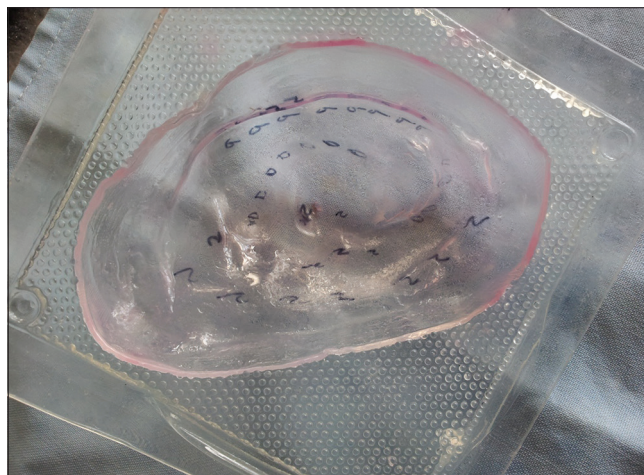


Figure 3: Wax sculpture splint of the left intact ear



on this cast model [Figure 3]. This plate was turned inside out to obtain the cast model of the left healthy ear. Alginate impression was again made from this model for the wax pattern procedure. This alginate impression was filled with wax. The pattern was removed from the impression for try-in procedure. The prepared wax pattern was then adapted to the first right ear's stone cast and was modified by controlling the shape and form [Figure 4]. This wax pattern's adaptation is also controlled on the second call of the patient. The wax pattern was verified for accuracy of fit, orientation, and esthetics with the patient in the physiologic rest position. This procedure took a very short time compared with donor technique. The wax pattern was polished before the wax elimination procedure. The wax pattern was placed into a flask and conventional procedures for wax elimination of the mold were followed. After the complete removal of wax, magnets [Figure 5] were placed in their analog place and stabilized by the help of self-cure acrylic (Meliodent Cold, Heraeus Kulzer, Germany) A RTV A 2,000 silicon elastomer, (Factor 2, Technovent, UK) which was colored intrinsically (Factor 2 Functional Intrinsic, Technovent, UK) was then bulk filled, and the material was processed according to the manufacturer's directions. The material waited half an hour at 135°C at room temperature. The final corrections were made, and the silicon prostheses were colored extrinsically (Extrinsic Coloring Kit P702) according to patients' skin color then adapted to the patient [Figure 6].

## DISCUSSION

Magnet and bar-and-clip retentions are the two primary forms of retention used in the auricular region. In this case report, magnet attachment was used for retention.<sup>[19,20]</sup>

The bar-clip system provides good retention for the prostheses. However, bars may limit access for performing hygiene procedures and make it difficult to insert and remove the prosthesis. The most common problem encountered with the bar and clip system is loosening of the clip after 3–4 months. Magnetic retention can be preferred because of hygiene, mechanical, and esthetic considerations. However, when magnets are used as retaining component they tend to corrode over a period of time.<sup>[21]</sup> According to a study, at the end of the wear test, the magnetic systems showed very little loss of retention, but were still less retentive than the bar clip systems, suggesting higher durability under clinical simulation despite

the lower retention initially provided.<sup>[13]</sup> According to Del Valle *et al.*, magnet systems are best used where only tensile forces are anticipated or where horizontal forces on the implants are to be avoided.<sup>[19]</sup> New-generation magnets and associated abutment magnetic caps now provide for free standing magnetic retention that is

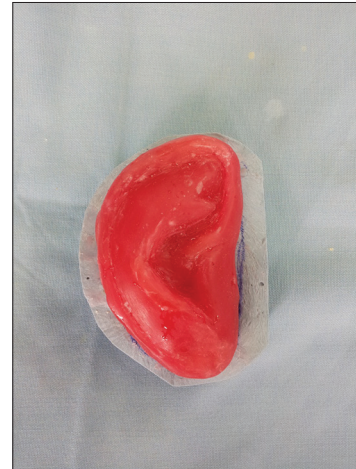


Figure 4: Completed wax pattern on stone cast

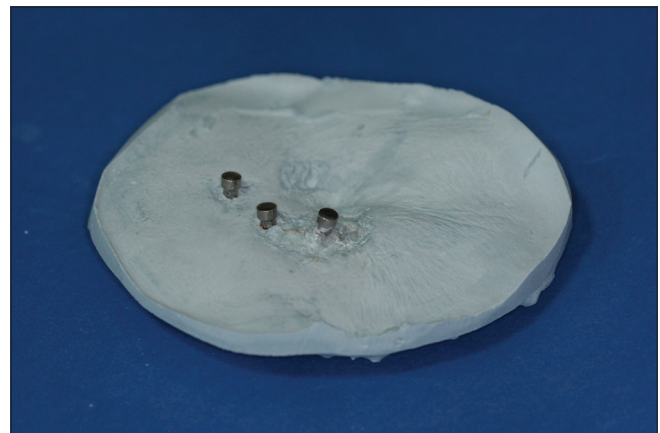


Figure 5: Magnet retention element

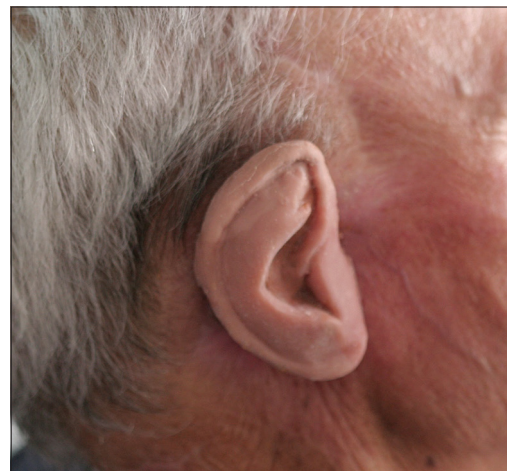

Figure 6: Finished implant-retained auricular prosthesis

secure and provides improved abutment access for the patient because the bar is absent.<sup>[22]</sup>

The impression of the defect side should be accurate, as the fit of the prosthesis depends on this factor. In addition, the impression of the normal ear is equally important as it serves as a guide to construct a pattern. The transparent orthodontic splint, by this way provides a simple and easy way to duplicate and transfer the exact size and position of the intact ear to the defect side and provide a simple template that orients the implants to the confines of the definitive prosthesis.<sup>[23]</sup> Other techniques may not be able to reproduce all the anatomic features, and works only with the presence of intact ear in the other side.<sup>[23]</sup> However, there are some limitations of this technique in a situation where patient has a congenital facial asymmetry and the surgeon correct the distances measured from the normal side to fit with those of defect side and do not violate the anatomy.

This method saves time usually spent in waxing up the prosthesis was effective in producing a perfectly mirrored shape, form, and alignment to the nondefect contralateral ear. The use of craniofacial implants for retention of the extraoral prosthesis, such as ears, offers excellent support and retentive abilities, and improves a patient's appearance and quality of life.<sup>[3,24]</sup> However, a satisfactory outcome may only be achieved by careful planning in terms of the number and position and orientation of the implants and the proper connection of the auricular prosthesis to implant retention structure.<sup>[25]</sup>

Intrinsic coloration is better than extrinsic coloration as it makes the prosthesis less susceptible to environmental changes and provides better handling. According to studies by Leow *et al.*<sup>[26]</sup> coloring pigments are known to undergo discoloration after some time due to exposure to ultraviolet light, elevated temperatures, and sweat.<sup>[27-30]</sup> The patient was informed regarding the weathering of the prosthesis and was advised for refabrication of the prosthesis when required. There is still a need to produce a prosthesis color tone that blends with the tissue tone adjacent to the defect side, and looks natural under different lighting conditions.

## CONCLUSIONS

This technique provides a simple, safe, inexpensive and time saving, effective and accurate wax sculpture that orients the auricular prosthesis to look more natural as his symmetric intact ear. The patient was satisfied with the life-like appearance of the prosthesis.

**Financial support and sponsorship**  
Nil.

## Conflicts of interest

There are no conflicts of interest.

## REFERENCES

- Ozturk AN, Usumez A, Tosun Z. Implant-retained auricular prosthesis: A case report. *Eur J Dent* 2010;4:71-4.
- Beumer J, Zlotolow I. Restoration of facial defects: Etiology, disability, and rehabilitation. In: Beumer J, Curtis TA, Firtell DN, editors. *Maxillofacial Rehabilitation: Prosthodontic and Surgical Considerations*. St. Louis, MO: C.V. Mosby; 1979. p. 328-40.
- Chung RW, Siu AS, Chu FC, Chow TW. Magnet-retained auricular prosthesis with an implant-supported composite bar: A clinical report. *J Prosthet Dent* 2003;89:446-9.
- Mantri SS, Thombre RU, Pallavi D. Prosthodontic rehabilitation of a patient with bilateral auricular deformity. *J Adv Prosthodont* 2011;3:101-5.
- Beumer J, Curtis TA, Marunick MT. Maxillofacial rehabilitation. In: *Prosthodontic and Surgical Considerations*. St. Louis: Ishiyaku Euro America; 1996. p. 437.
- Roumanas ED, Chang TL, Beumer J. Use of osseointegrated implants in the restoration of head and neck defects. *J Calif Dent Assoc* 2006;34:711-8.
- Abu-Serriah MM, McGowan DA, Moos KF, Bagg J. Extra-oral endosseous craniofacial implants: Current status and future developments. *Int J Oral Maxillofac Surg* 2003;32:452-8.
- Visser A, Raghoebar GM, van Oort RP, Vissink A. Fate of implant-retained craniofacial prostheses: Life span and aftercare. *Int J Oral Maxillofac Implants* 2008;23:89-98.
- Wright RF, Zemnick C, Wazen JJ, Asher E. Osseointegrated implants and auricular defects: A case series study. *J Prosthodont* 2008;17:468-75.
- Karayazgan B, Gunay Y, Atay A, Noyun F. Facial defects restored with extraoral implant-supported prostheses. *J Craniofac Surg* 2007;18:1086-90.
- Chung RW, Siu AS, Chu FC, Chow TW. Magnet-retained auricular prosthesis with an implant-supported composite bar: A clinical report. *J Prosthet Dent* 2003;89:446-9.
- Voigt A, Christ S, Klein M. Experimental analysis of retention forces of different magnetic devices for bone-anchored auricular facial prostheses. *Int J Oral Maxillofac Surg* 2008;37:664-8.
- de Sousa AA, Mattos BS. Magnetic retention and bar-clip attachment for implant-retained auricular prostheses: A comparative analysis. *Int J Prosthodont* 2008;21:233-6.
- Hegde C, Krishma DP, Shukla P, Shetty M. Rehabilitation of auricular defects utilizing single implant and tissue support. *J Indian Prosthodont Soc* 2008;8:105-7.
- Seals RR Jr, Cortes AL, Parel SM. Fabrication of facial prostheses by applying the osseointegration concept for retention. *J Prosthet Dent* 1989;61:712-6.
- Gurbuz A, Kalkan M, Ozturk AN, Eskitascioglu G. Nasal prosthesis rehabilitation: A case report. *Quintessence Int* 2004;35:655-6.
- Godoy AJ, Lemon JC, Nakamura SH, King GE. A shade guide for acrylic resin facial prostheses. *J Prosthet Dent* 1992;68:120-2.
- McKinstry RE. *Fundamentals of Facial Prosthetics*. Clearwater: ABI Professional Publications; 1995. p. 169-79.
- Arora A, Pasam N, Gilra S, Arora PC. Prosthetic rehabilitation of auricular defect: A clinical report. *Prosthet Orthot Int* 2013;37:240-4.
- Del Valle V, Faulkner G, Wolfaardt J, Rangert B, Tan HK. Mechanical evaluation of craniofacial osseointegration retention systems. *Int J Oral Maxillofac Implants* 1995;10:491-8.
- Wolfaardt JF, Wilkes GH, Anderson JD. Craniofacial osseointegration: Prosthodontic treatment. In: Taylor TD, editor. *Clinical Maxillofacial Prosthetics*. Chicago: Quintessence; 2000. p. 285-7.
- Lovely M, Dathan PC, Gopal D, George BT, Chandrasekharan Nair K. Implant retained auricular prosthesis with a modified hader bar: A case report. *J Indian Prosthodont Soc* 2014;14:187-90.
- de Sousa AA, Mattos BS. Magnetic retention and bar-clip attachment for implant-retained auricular prostheses: A comparative analysis. *Int J Prosthodont* 2008;21:233-6.

24. Del Valle V, Faulkner G, Wolfaardt J, Rangert B, Tan HK. Mechanical evaluation of craniofacial osseointegration retention systems. *Int J Oral Maxillofac Implants* 1995;10:491-8.
25. Thomas KF. Freestanding magnetic retention for extraoral prosthesis with osseointegrated implants. *J Prosthet Dent* 1995;73:162-5.
26. Charkawi HG, Sharkawy AG. A simplified technique for orientation of a bone anchored auricular prostheses: A clinical report. *J Oral Maxillofac Res* 2012;3:e6.
27. McCartney JW. Osseointegrated implant-supported and magnetically retained ear prosthesis: A clinical report. *J Prosthet Dent* 1991;66:6-9.
28. Chung RW, Siu AS, Chu FC, Chow TW. Magnet-retained auricular prosthesis with an implant-supported composite bar: A clinical report. *J Prosthet Dent* 2003;89:446-9.
29. Gilson TD, Asgar K, Peyton FA. The quality of union formed in casting gold to embedded attachment metals. *J Prosthet Dent* 1965;15:464-73.
30. Leow ME, Ow RK, Valiyaveetil S, Lee MH, Pho RW. Colourfast pigments in silicone hand and maxillofacial prostheses. *Prosthet Orthot Int* 2002;26:124-34.

Access this article online	
<b>Quick Response Code:</b> 	<b>Website:</b> <a href="http://www.eurjdent.com">www.eurjdent.com</a>