

# A modified presurgical orthopedic (nasopalveolar molding) device in the treatment of unilateral cleft lip and palate

Chitravelu Siva Subramanian<sup>1</sup>, N. K. K. Koteswara Prasad<sup>1</sup>, Arun B. Chitharanjan<sup>1</sup>,  
Eric Jein Wein Liou<sup>2</sup>

**Correspondence:** Dr. Chitravelu Siva Subramanian  
Email: drsivaorthodontist@gmail.com

<sup>1</sup>Department of Orthodontics and Dentofacial Orthopedics, Faculty of Dental Sciences, Sri Ramachandra University, Porur, Chennai, Tamil Nadu, India,  
<sup>2</sup>Craniofacial Dentistry and Orthodontics, Faculty of Dentistry, Chang Gung Memorial Hospital, Taipei, Taiwan

## ABSTRACT

Nasopalveolar molding (NAM) can be done effectively to reshape the nasal cartilage and mold the maxillary dentoalveolar arch before surgical cleft lip repair and primary rhinoplasty. Presurgical NAM helps as an adjunct procedure to enhance the esthetic and functional outcome of the surgical procedures. We have developed a modified NAM device to suit to the needs of the patients coming from distant places for the treatment. This device helps in reducing the number of frequent visits the patient needs to take to the craniofacial center. The purpose of this presentation is to report this treatment technique and discuss its application.

**Key words:** Infant orthopedics, presurgical infant orthopedics presurgical nasopalveolar molding, unilateral cleft lip and palate

## INTRODUCTION

Presurgical infant orthopedic procedure plays an important role during the initial treatment of the neonatal cleft lip and palate cases. McNeil put forward the modern concept of presurgical maxillary infant orthopedics in 1950.<sup>[1]</sup> He used various plates to mold the alveolar segments into its proper place. Georgiade and Latham in the year 1975 used a pin-retained active appliance to retract the protruded premaxilla and expand the collapsed posterior segments at the same time over several days.<sup>[2]</sup> Matsuo *et al.* worked on neonatal nasal cartilage have shown that the nasal cartilage can be molded if treatment was initiated within the first 6 weeks from the time of birth due to

high levels of maternal estrogen in the fetal circulation. The hormone increases the hyaluronic acid level which alters the elasticity of cartilage, ligament, and the connective tissue.<sup>[3-5]</sup>

Nasopalveolar molding (NAM) technique has various advantages. (1) It is used for symmetrical re-contouring of the nasal cartilage on the defective side. (2) It is used to mold and approximate the alveolar process of the maxillary arch before surgical correction of the cleft lip. (3) Effective retraction of protruded premaxilla is observed. (4) Lengthening of deficient columella is also found. (5) It reduces the need for

This is an open access article distributed under the terms of the Creative Commons Attribution-NonCommercial-ShareAlike 3.0 License, which allows others to remix, tweak, and build upon the work non-commercially, as long as the author is credited and the new creations are licensed under the identical terms.

For reprints contact: reprints@medknow.com

**How to cite this article:** Subramanian CS, Prasad NK, Chitharanjan AB, Liou EJ. A modified presurgical orthopedic (nasopalveolar molding) device in the treatment of unilateral cleft lip and palate. *Eur J Dent* 2016;10:435-8.

DOI: 10.4103/1305-7456.184146

Access this article online	
<p>Quick Response Code:</p> 	<p>Website: www.eurjdent.com</p>

later secondary alveolar bone graft. (6) Pritchard put forward a concept that bone healing was inversely proportional to cleft size; hence, presurgical infant orthopedic procedures must be advocated to reduce the cleft size which may promote bone formation.<sup>[6]</sup> The main purpose of the presurgical NAM is to reduce the severity of cleft deformity and for the effective surgical repair of the lip alveolus and nose.<sup>[7]</sup>

In 1999, Grayson *et al.*<sup>[8]</sup> put forward a unique presurgical NAM procedure for infants born with cleft lip and palate. In this article, we describe a modified presurgical NAM technique.

## CASE REPORT

A female baby who was 45 days old reported to the craniofacial center with unilateral cleft lip and palate [Figure 1]. After clinical examination, NAM was planned for the patient. The parents were informed about the treatment procedure and the duration, with more emphasis placed on their daily involvement during the active phase of the NAM procedure.

### Impression technique

The parents were asked not to feed the baby at least 3 h before taking impression. Impression was taken with the child secure in the mother's lap. Primary impression of the maxillary arch was taken with silicone impression material in a special pediatric impression tray [Figure 2]. Caution was taken to avoid any airway obstruction. After the impression had been taken, oral and nasal cavities were inspected for any residual impression material. The impression was poured in dental stone for making a working model [Figure 3].

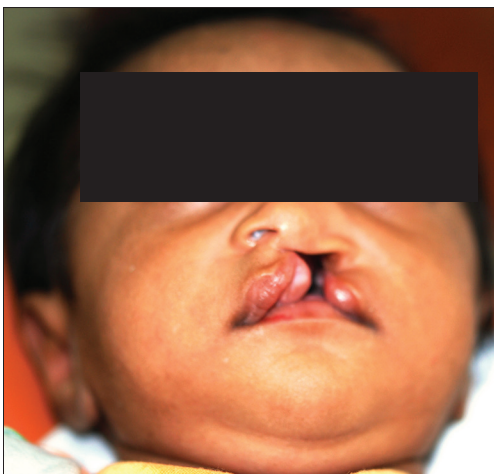

Figure 1: Baby with unilateral cleft lip and palate

### Appliance fabrication

The plate was fabricated on the impression cast after the undercut areas were blocked with utility wax. Separator medium was placed onto the cast. The plate was made of self-cure acrylic material. The plate should be at least 2 mm in thickness to provide rigidity during the NAM procedure. Nasal stent was made in. 032-inch titanium molybdenum alloy (TMA) wire, the retentive part was acrylized in the plate during the plate fabrication [Figure 4a and b]. The plate is placed in the infant's mouth, and from the wire, a coil is made which is 3–4 mm in diameter. The upper part of the wire reaches the dome of the nose which is bent into bean shape to incorporate acrylic bulb. The acrylic bulb is coated with soft acrylic for ease of insertion and also to prevent irritation during activation [Figure 5].

### Appliance insertion and taping

All the surfaces of the plate are smoothed any rough surface, or hard edges may irritate the soft tissues and may cause ulcerations. The plate was placed in the mouth and checked for fitting. Properly seated appliance will have the plate seated in the mouth and the nasal stent soft acrylic placed in the medial alar wall of the nose on the affected side. The baby was kept under observation for the initial few minutes to check for the stability of the plate. Steri strips are placed from one side of the cheeks to the other side [Figure 6]. After this procedure, the parents were asked to bottle feed the baby to ensure there is no gag reflex.

### Appliance adjustment

The baby was seen once in 2 weeks for appliance adjustment. The plate is adjusted to facilitate the approximation of the alveolar process. The nasal

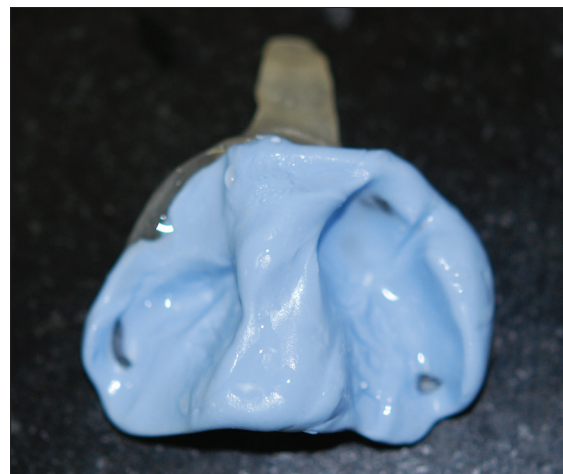

Figure 2: Maxillary arch impression using silicone impression material

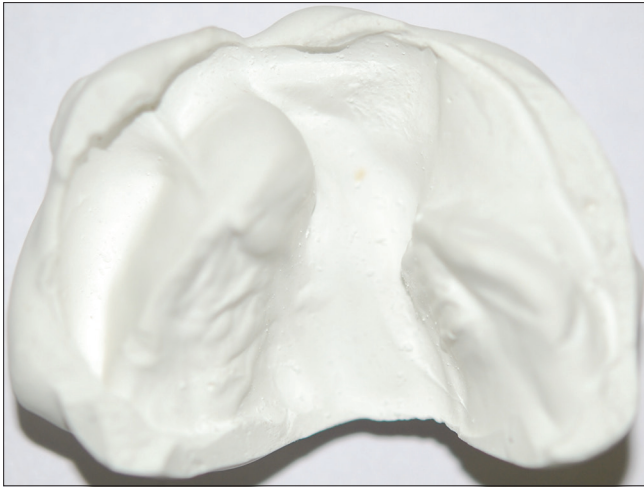

Figure 3: Stoneworking model of the cleft alveolus

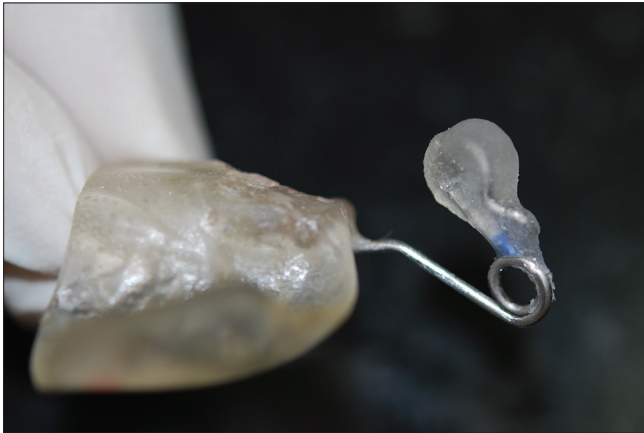

Figure 5: Modified nasoalveolar molding device with acrylic bulb

stent is adjusted to align the nasal dome, improve nasal projection, and increase the length of the columella. The adjustment of the nasal stent is done with orthodontic pliers. The parents were advised to clean the plate every day and keep the plate clean.

## DISCUSSION

Presurgical infant orthopedic procedures reduce the number of future surgeries and also the need for alveolar bone grafting. The advantage of presurgical NAM device is that it not only performs the molding function but also acts as feeding plate and facilitates the infant feeding, thereby helps in the development of the much-needed suckling reflex. In this technique, we have modified the NAM device by making the nasal stent with TMA wire. The advantage of the TMA wire is that it is more resilient, and hence, activation can be done once in 2 weeks unlike the other technique where

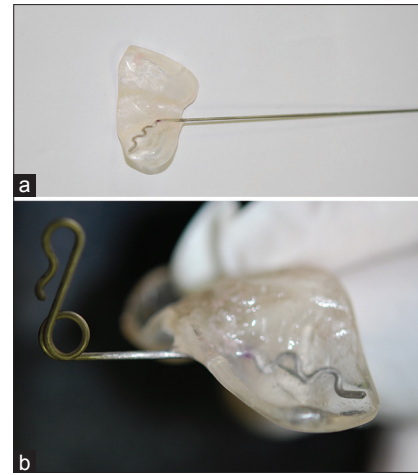


Figure 4: (a and b) Nasal stent wire made of 0.32 titanium molybdenum alloy

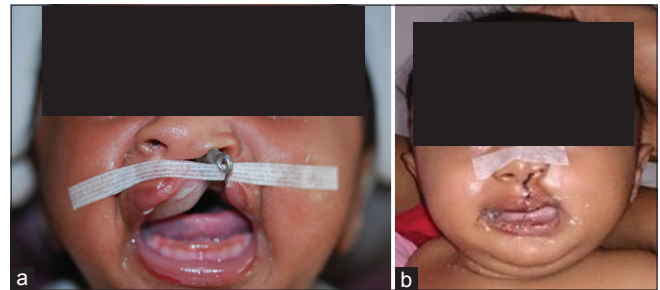


Figure 6: (a) Nasoalveolar molding device and taping in place. (b) Postsurgical

activation of the nasal bulb has to be done once in a week. This causes added burden for the parents who come from far distances to come with the baby once a week.<sup>[9]</sup> Further, the nasal stent made with TMA wire can be adjusted with orthodontic pliers, and the activation does not take long chairside time, which in turn increases the compliance of the baby during the activation period.

## CONCLUSION

In India, the numbers of cleft cases are significantly high, so it is imperative to develop and modify procedures to make the treatment cost-effective and ease the burden of the child with cleft lip and palate and that of the parents of child with such deformities which will help to improve the psychological well-being of the growing child and enable the child to become part of the society.

### Declaration of patient consent

The authors certify that they have obtained all appropriate patient consent forms. In the form the patient(s) has/have given his/her/their consent for

his/her/their images and other clinical information to be reported in the journal. The patients understand that their names and initials will not be published and due efforts will be made to conceal their identity, but anonymity cannot be guaranteed.

#### **Financial support and sponsorship**

Nil.

#### **Conflicts of interest**

There are no conflicts of interest.

## **REFERENCES**

1. McNeil C. Orthodontic procedures in the treatment of congenital cleft palate. *Dent Rec* 1950;70:126-32.
2. Burston WR. The early orthodontic treatment of cleft palate conditions. *Dent Pract* 1958;9:41.
3. Matsuo K, Hirose T. Nonsurgical correction of cleft lip nasal deformity in the early neonate. *Ann Acad Med Singapore* 1988;17:358-65.
4. Matsuo K, Hirose T, Otagiri T, Norose N. Repair of cleft lip with nonsurgical correction of nasal deformity in the early neonatal period. *Plast Reconstr Surg* 1989;83:25-31.
5. Matsuo K, Hirose T. Preoperative non-surgical over-correction of cleft lip nasal deformity. *Br J Plast Surg* 1991;44:5-11.
6. Santiago PE, Grayson BH, Cutting CB, Gianoutsos MP, Brecht LE, Kwon SM. Reduced need for alveolar bone grafting by presurgical orthopedics and primary gingivoperiosteoplasty. *Cleft Palate Craniofac J* 1998;35:77-80.
7. Grayson BH, Shetye PR. Presurgical nasoalveolar moulding treatment in cleft lip and palate patients. *Indian J Plast Surg* 2009;42:Suppl S1:56-61.
8. Grayson BH, Santiago PE, Brecht LE, Cutting CB. Presurgical nasoalveolar molding in infants with cleft lip and palate. *Cleft Palate Craniofac J* 1999;36:486-98.
9. Sischo L, Broder HL, Phillips C. Nasoalveolar molding: Prevalence of cleft centers offering NAM and who seeks it. *Cleft Palate Craniofac J* 2015;52:640-50.