

Free gingival grafting procedure after excisional biopsy, 12-year follow-up

Ilker Keskiner¹, B. Arzu Alkan², Zekeriya Tasdemir²

Correspondence: Dr. Ilker Keskiner
Email: ilkerkeskiner@yahoo.com

¹Department of Periodontology, Faculty of Dentistry, Ondokuz Mayıs University, Samsun, Türkiye,
²Department of Periodontology, Faculty of Dentistry, Erciyes University, Kayseri, Türkiye

ABSTRACT

The total removal of a lesion via excisional biopsy causes gingival recession, resulting in dentin hypersensitivity and esthetical problems. In this case report, a gingival recession defect resulting from an excisional biopsy was treated with a free gingival grafting procedure performed during the same appointment, and its 12-year follow-up was presented. A 44-year-old female patient was presented to our clinic with a firm, pedunculated, red gingival enlargement located on the labial surface of lower incisors. The exposed root surface, after the excisional biopsy, was covered with a free gingival graft. The lesion was pathologically diagnosed as pyogenic granuloma, and in the early postoperative phase, no recurrence was observed, but partial root coverage was determined. At 6-month follow-up, root coverage resulting from “creeping attachment” was observed, and this situation was maintained throughout the 12-year follow-up period. Repetitious postoperative discomfort and emotional stress for the patient may be avoided with a timesaving single appointment performing excisional biopsy and free gingival graft. Free gingival grafting procedure was used for this purpose not only to cover exposed root surfaces but also to eliminate dentin hypersensitivity and make oral hygiene procedures more effective.

Key words: Excisional biopsy, free gingival graft, pyogenic granuloma

INTRODUCTION

Pyogenic granuloma (PG) is benign, nonneoplastic, and the most commonly found lesion in the oral cavity.^[1] PGs can be found in all age groups; however, females are 2 times more frequently affected than males.^[2] Traumatic injuries, local irritations, hormonal factors, certain kinds of drugs, and even some vascular morphogenesis factors have been associated with PG.^[3]

An excisional biopsy should be performed with a safe distance of 1 mm apart from the borders of the lesion, due to the possibility of recurrence^[4]

and possible irritants and local factors must be removed.^[2] However, total removal of a lesion with healthy adjacent tissue by an excisional biopsy can lead to mucogingival problems^[5] such as gingival recession and disharmonic gingival margins. However, it may result in hypersensitivity and esthetical problems.

In this case report, the treatment of a gingival recession defect resulting from an excisional biopsy by a free gingival grafting procedure performed in the same appointment and its 12-year follow-up were presented.

This is an open access article distributed under the terms of the Creative Commons Attribution-NonCommercial-ShareAlike 3.0 License, which allows others to remix, tweak, and build upon the work non-commercially, as long as the author is credited and the new creations are licensed under the identical terms.

For reprints contact: reprints@medknow.com

How to cite this article: Keskiner I, Alkan BA, Tasdemir Z. Free gingival grafting procedure after excisional biopsy, 12-year follow-up. Eur J Dent 2016;10:432-4.

DOI: 10.4103/1305-7456.184154

Access this article online

Quick Response Code:



Website:
www.eurjdent.com

CASE REPORT

A 44-year-old female patient applied to the Periodontology Clinic at Ondokuz Mayıs University with a complaint of a gingival enlargement on the labial surface of lower incisors [Figure 1a]. The patient had noticed the enlargement for nearly 4 months previous to the appointment and was concerned about its gradually increasing size. The clinical examination revealed a firm, pedunculated, red gingival enlargement located on the vestibular surfaces of tooth #41 and #42. The lesion's diameter was approximately 1 cm, and bleeding was easily caused by the mechanical stimulus. She was nonsmoker who had a good general and dental health but with poor plaque control. There were no evident signs of pathology as evaluated by a periapical radiograph and orthopantomography. Treatment options were explained to the patient, and an excisional biopsy and free gingival graft surgery were scheduled. Before surgery, the patient signed the informed consent.

Following local anesthesia, the lesion was removed with a safe distance of approximately 1 mm apart from the healthy tissue to reduce the recurrence. Following surgical excision, a mucogingival defect with exposed root surfaces was occurred [Figure 1b]. Root planing was performed, and a free gingival graft obtained from the palatal premolar region was stabilized with 4/0 silk sutures [Figure 1c]. No periodontal dressing was used. The patient was prescribed analgesics and a mouthrinse. The tissue specimen was fixed in formalin and sent for pathological investigation and it diagnosed as PG.

The healing was uneventful, and the sutures were removed at 10 days. In the early postoperative phase,

no recurrence was observed, but partial root coverage was achieved. At the 6-month follow-up, root coverage resulting from "creeping attachment" was observed, and this situation was maintained throughout the 12-year follow-up period [Figure 2a-d]. The pocket depths measured as 1–2 mm from the mid-labial surfaces of teeth #41 and #42 at 1-month were maintained until the 12-year follow-up control.

DISCUSSION

A recurrence rate of between 16% and 21% has been reported for PGs with conventional excision techniques.^[6] One of the most important predisposing factors for recurrence is an inadequate excision. In our case, no recurrence occurred through 12 years of follow-up. In the light of the literature,^[2,5] an excision technique in which the lesion was removed with a safe distance of approximately 1 mm apart from the healthy tissue, and the removal of the remnants at the base of the original lesion, might have played key roles in this outcome.

Surgical excision of the lesion often results in a large amount of bone exposure because of the difficulty in obtaining primary closure of the wound area, a situation that may subsequently lead to bone resorption. Postoperative soft tissue recession may cause exposure of the root surface with esthetic problems, possible root sensitivity, and caries.^[5] For this reason, the present case required a treatment that included a periodontal plastic surgery procedure. Several different soft tissue surgical techniques may be suggested to treat similar lesions, including coronally positioned flaps and pedicle flaps with or without connective tissue grafts, as well as free keratinized tissue grafts. In the present case, especially in view

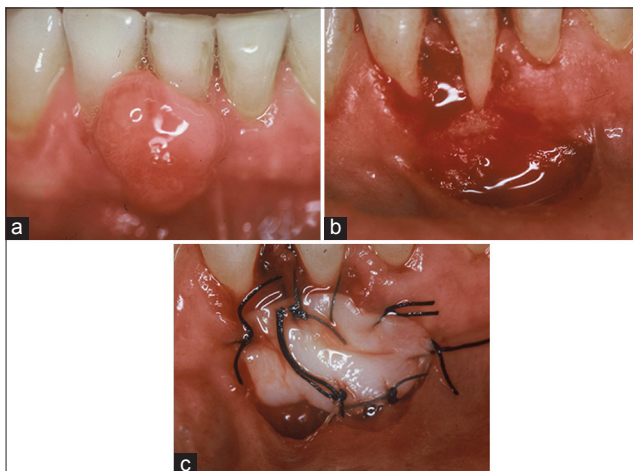


Figure 1: (a) Preoperative clinical view of lesion, (b) clinical view after excisional biopsy (c) free gingival graft placed on biopsy site

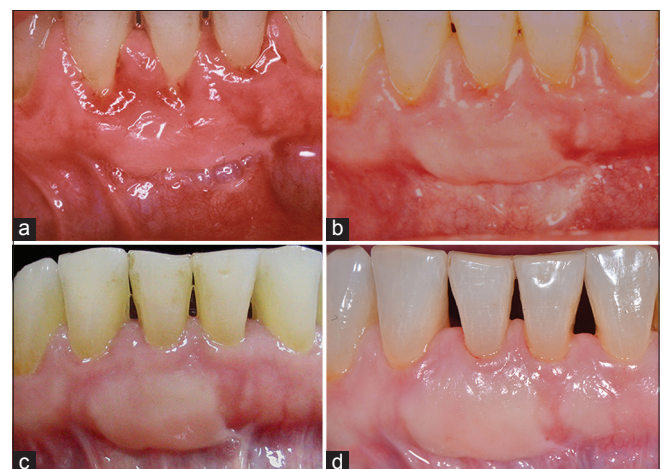

Figure 2: Postoperative clinical views at (a) 1 month (b) 6 months, (c) 2 years, (d) 12 years

of the relatively narrow band of keratinized tissue apical to the biopsy defect, we avoided performing coronally positioned flap. A laterally positioned flap was also could not be performed due to the extension of the biopsy area to the gingiva of the neighboring teeth, and the difficulty in covering two exposed root surfaces; in addition, a laterally positioned flap could have involved the risk of gingival recession if the facial bone at the donor site has a fenestration or dehiscence. Although the free keratinized tissue graft has the advantage of restoring an adequate amount of keratinized tissue width and thickness, coupled with root coverage, the white color of the gingiva may be disadvantageous. However, appearance of 12-year follow-up was esthetically satisfactory in our case.

Goldman *et al.*^[7] were the first to describe the term “creeping attachment” as the “postoperative migration of the gingival margin in a coronal direction over a previously denuded root.” Based on the research of Borghetti and Gardella,^[8] “creeping attachment” is any root coverage that occurs postoperatively after 1 month, with the mandibular anterior teeth best showing this condition with their narrow recessions.^[9] The average coverage is approximately 1 mm, which can be detected 1–12 months after graft surgery.^[10] The “creeping attachment” improved the results in our case, and the exposed root surfaces seen at 1-month were covered with “creeping attachment” at 6 months, which was maintained after 12 years.

In this particular case, a recession defect and a shallow vestibule sulcus might have occurred without an additional mucogingival treatment. Although defects following excisional surgery can be treated at a later stage, this may result in postoperative discomfort and emotional stress for the patient. The two dental

procedures performed (biopsy and free gingival graft) in a single appointment are timesaving both for the patient and the clinician.

Long-term follow-up is important after surgical excision. Our technique of eliminating the PG seemed to offer good esthetic results, with a stable and healthy gingival situation without recurrence at the 12-year follow-up.

Financial support and sponsorship

Nil.

Conflicts of interest

There are no conflicts of interest.

REFERENCES

1. Kocaman G, Beldüz N, Erdogan C, Ozbek E, Sadik E, Kara C. The use of surgical Nd: YAG laser in an oral pyogenic granuloma: A case report. *J Cosmet Laser Ther* 2014;16:197-200.
2. Joda T. Esthetic management of mucogingival defects after total excision in a case of pyogenic granuloma. *Eur J Esthet Dent* 2012;7:110-9.
3. Jafarzadeh H, Sanatkhani M, Mohtasham N. Oral pyogenic granuloma: A review. *J Oral Sci* 2006;48:167-75.
4. Bosco AF, Bonfante S, Luize DS, Bosco JM, Garcia VG. Periodontal plastic surgery associated with treatment for the removal of gingival overgrowth. *J Periodontol* 2006;77:922-8.
5. Chawla K, Lamba AK, Faraz F, Tandon S, Ahad A. Diode laser for excisional biopsy of peripheral ossifying fibroma. *Dent Res J (Isfahan)* 2014;11:525-30.
6. Salum FG, Yurgel LS, Cherubini K, De Figueiredo MA, Medeiros IC, Nicola FS. Pyogenic granuloma, peripheral giant cell granuloma and peripheral ossifying fibroma: Retrospective analysis of 138 cases. *Minerva Stomatol* 2008;57:227-32.
7. Goldman H, Schluger S, Fox L, Cohen D. *Periodontal Therapy*. 3rd ed. St. Louise: Mosby Co.; 1964.
8. Borghetti A, Gardella JP. Thick gingival autograft for the coverage of gingival recession: A clinical evaluation. *Int J Periodontics Restorative Dent* 1990;10:216-29.
9. Matter J. Creeping attachment of free gingival grafts. A five-year follow-up study. *J Periodontol* 1980;51:681-5.
10. Bell LA, Valluzzo TA, Garnick JJ, Pennel BM. The presence of “creeping attachment” in human gingiva. *J Periodontol* 1978;49:513-7.