

Nestin expressions of exposed pulp after direct pulp capping by calcium hydroxide and platelet rich plasma

Sartika Puspita¹, Totok Utoro², Tetiana Haniastuti³

¹Biomedical Department, School of Dentistry, Medical and Health Sciences Faculty Universitas Muhammadiyah Yogyakarta (UMY), Indonesia,

²Department of Pathology Anatomi, Faculty of Medicine, Gadjah Mada University, Yogyakarta, Indonesia,

³Department of Oral Biology, Faculty of Dentistry, Gadjah Mada University, Yogyakarta, Indonesia

Correspondence: Sartika Puspita
Email: tikadentist@yahoo.co.id

ABSTRACT

Objective: The aim of this study was to evaluate nestin expression of pulp tissue following direct pulp capping with platelet-rich plasma (PRP). **Materials and Methods:** The thirty sound teeth from Sprague-Dawley rats were used and divided into two groups: Groups 1, teeth were capped with calcium hydroxide/Ca(OH)₂ ($n = 15$) and Group 2 with PRP ($n = 15$). After 1st, 7th, and 21st days, respectively, 5 teeth each group (American Dental Association 41) were processed for light microscopic examination. Expressions of nestin were assessed by immunohistochemical techniques. **Results:** Nestin expression of Ca(OH)₂ on the distance place of exposure at 1st and 7th days were 80% and at 21st day were 60%. Nestin expression of PRP on the distance place at 1st day was 80%, 7th 100%, and 21st day was 80%. At day 21 observation, Kruskal–Wallis test shows nestin expression was increased significantly in PRP groups ($P < 0.05$), but it was not increase significantly compare with Ca(OH)₂. **Conclusion:** PRP had ability as a direct pulp capping material to induce nestin expression.

Key words: Nestin expressions, platelet rich plasma, pulp capping

INTRODUCTION

Nowadays, there are various materials used for the treatment of pulp capping. There are calcium hydroxide, zinc oxide eugenol, and resin-based materials. All of them have a high failure. Calcium hydroxide makes dentin bridge formation is not perfect and porous therefor, allowing the bacterial leakage at 50–87% of cases.^[1] After 83 days, the application of zinc oxide eugenol materials as much as 66.66% of the cases showed dentin bridge formation was not perfect with inflammation and necrosis.^[2]

Resin-based materials cause chronic inflammation and unformed dentin bridge.^[1]

The using of calcium hydroxide has been a long time and ubiquitous in endodontic treatment since that material has ability to change the tissue-healing milieu. The successfulness of the applying of this material was reported by some researchers.^[3] However, some research that shows there was a lack of calcium hydroxide as pulp capping material such

This is an open access article distributed under the terms of the Creative Commons Attribution-NonCommercial-ShareAlike 3.0 License, which allows others to remix, tweak, and build upon the work non-commercially, as long as the author is credited and the new creations are licensed under the identical terms.

For reprints contact: reprints@medknow.com

How to cite this article: Puspita S, Utoro T, Haniastuti T. Nestin expressions of exposed pulp after direct pulp capping by calcium hydroxide and platelet rich plasma. Eur J Dent 2016;10:341-4.

DOI: 10.4103/1305-7456.184157

Access this article online	
Quick Response Code: 	Website: www.eurjdent.com

as form necrotic areas on the pulp tissue when there is a direct contact with the material.^[4]

Some researchers developed a material from the growth factors present in platelet-rich plasma (PRP) called a platelet-derived growth factor (PDGF), research results indicate that PDGF plays an important role in the process of connective tissue regeneration and odontoblast cells differentiation because those materials are part of the process of dentinogenesis and pulp tissue regeneration.^[5]

PRP is a natural source of autologous growth factors and contains many growth factors such as PDGF, transforming growth factor-beta, vascular endothelial growth factor, insulin growth factor, and epidermal growth factor.^[6] PRP may accelerate healing in maxillofacial and periodontal surgery in the case of maxillofacial reconstruction, implants, and bone graft.^[7] PRP in the treatment of patients with damage of the infrabony pocket, the result shows the process of new bone formation faster on the patients using PRP treatment.^[6]

Initial formation of reparative dentin is a new odontoblast-like cells characterized by expression of nestin below the exposed pulp. Nestin is intermediate filament protein expressed on the process of tooth development and expressed back in the dentin-pulp complex in conditions of caries after cavity preparation and tooth replantation. Nestin is a marker of the function and differentiation of odontoblast.^[8] It is related to the ability secretion of dentin matrix.^[2]

MATERIALS AND METHODS

Ethical clearance standardized by The Medical Research Ethics Committee of Health University of Gadjah Mada was implemented in this study. Subjects were 30 teeth, divided into two groups consisting of 15 teeth as a treated group (PRP) and 15 teeth as a control group (Ca[OH]₂). Each group is divided by the observed period on the 1st, 7th, and 21st days. The criteria of this study are tooth of Sprague-Dawley that are 250–300 g and 3–4 months.

The preparation of PRP was made in the Laboratory of Clinical Pathology, Faculty of Medicine, Gadjah Mada University, Yogyakarta, by gradient centrifugation.^[6] Before PRP applied as a pulp capping material, by same volume of 10% calcium chloride in sterile saline and 100 U/ml sterile bovine thrombin. This mixture of PRP gel is sticky, so it is relatively easy to apply.^[9]

Before the preparation, animals are anesthetized using chloral hydrate 8% at a dose of 350 mg/kg body weight. Molar teeth of the upper right and left experimental animals are prepared on the occlusal surface using a round bur no. 10 with a diameter of 1 mm and a depth of 1–1.2 mm to get closer to the pulp and then the animal performed with the sonde until the pulp was open/perforation.

The decapitation process was on 1st, 7th, and 21st days. The animals were anesthetized with ether and cervical dislocation done. Teeth samples extracted and fixed by 10% buffered formalin for 24 h. Then, they are performed decalcification with formic acid for 1 week. After that, they were planted in paraffin and then cut longitudinally with a thickness of 4 µm and stained by immunohistochemistry.

The data were statistically analyzed using Kruskal-Wallis test (SPSS 10.0 software, SPSS, Chicago, IL, USA) to find out whether there were significant differences between the nestin expression in the control and the treatment groups, based on histological grading criteria of nestin expression below [Figure 1].^[8]

- Score 0: There is nestin expression in all of the place in the exposed pulp tissue (directly below the lesion as well as the coronal and apical)
- Score 1: There is an expression of nestin cells just directly below the pulp opened/exposed
- Score 2: There is an expression of nestin cells is not directly below (among away from) the pulp opened (among coronal or just apical)
- Score 3: There is no expression of nestin cells immunopositive.

RESULTS

Nestin expression differences treated group (PRP) and a control group of inflammatory response (Ca[OH]₂), determined by Kruskal-Wallis statistical test. The difference of nestin expression in the PRP group to Ca(OH)₂ conducted Mann-Whitney U statistical tests. Mann-Whitney U-test result indicates $P > 0.05$ so that nestin expression on days 1st, 7th, and 21st between the application of Ca(OH)₂ and PRP was no significant difference.

Kruskal-Wallis statistical test results show that there are significant differences ($P < 0.05$) on the expression of nestin in the provision of PRP as a direct pulp capping on days 1st, 7th, and 21st, but based on Mann-Whitney U-test was significant differences, the scores shown in nestin expression

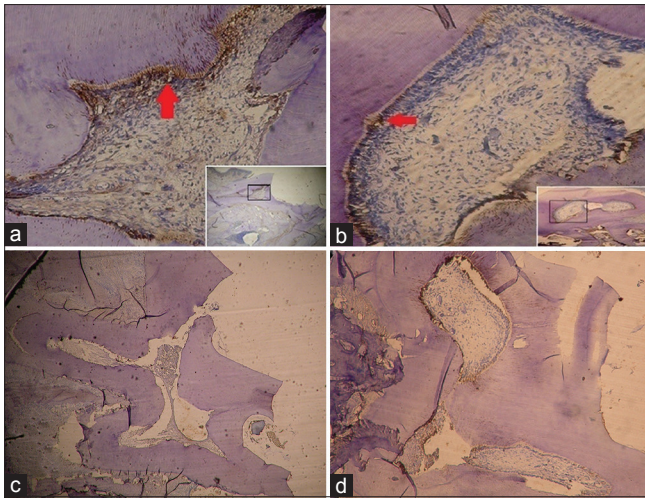


Figure 1: Microscopic picture of nestin expression by IHC staining ($\times 200$) on days 1st and 21st after direct pulp capping with $\text{Ca}(\text{OH})_2$. (a) Application of $\text{Ca}(\text{OH})_2$ day 1st, nestin positive (arrows), score 2. (b) Application of platelet-rich plasma day 21st, nestin positive (arrows), score 2. (c) Application of $\text{Ca}(\text{OH})_2$ day 1st, score 3. (d) Application of platelet-rich plasma day 21st, score 3

far away from the lesion is not positively expressed under the lesion.

The results of statistical tests Kruskal–Wallis nestin expression in the application of $\text{Ca}(\text{OH})_2$ 1st, 7th, and 21st days did not have a significant difference ($P > 0.05$), and no significant difference in the expression of nestin ($P < 0.05$) on the application of PRP as a pulp capping on 1st, 7th, and 21st days in a place away from the lesion. It was not a significant difference ($P > 0.05$) on the expression of nestin in the provision of $\text{Ca}(\text{OH})_2$ after 1st, 7th, and 21st days [Table 1]. The results of Mann–Whitney U statistical test to examine the expression of nestin comparison between the two groups of $\text{Ca}(\text{OH})_2$ and PRP showed a nonsignificant difference ($P > 0.05$).

DISCUSSION

Some researchers thought that PRP has a positive effect on the healing process.^[10] PRPs response of injury has advantage because of having a jump cascade properties/shortcut in the repairing tissue process.^[11] There are different injury response in mechanism between $\text{Ca}(\text{OH})_2$ and PRP as pulp capping. Calcium hydroxide as pulp capping material can be response to injury because it has alkaline properties that produce a favorable environment for alkaline phosphatase enzymes that play a role in the process of tooth mineralization.^[12] Calcium ions can reduce fluid and from the bloodstream can increase the concentration of intracellular calcium ions in the affected lesion.

Table 1: Score nestin expression in an exposed pulp after direct pulp capping with calcium hydroxide and platelet-rich plasma in each decapitation period

Score	$\text{Ca}(\text{OH})_2$			PRP		
	1 st days	7 th days	21 st days	1 st days	7 th days	21 st days
0	0	0	0	0	0	0
1	0	0	0	0	0	0
2	4	4	3	4	5	4
(%)	80	80	60	80	100	80
3	1	1	2	1	0	1
(%)	20	20	40	20	0	20

The positive nestin expression is not directly below the pulp exposed after 1st and 7th days after pulp capping with $\text{Ca}(\text{OH})_2$ was 80% of samples, and on the 21st day was 60% of samples. $\text{Ca}(\text{OH})_2$: Calcium hydroxide, PRP: Platelet rich plasma

This condition allows the availability of calcium ions required for the mineralization process and stimulates calcium-dependent pyrophosphatase enzyme that can lower the amount of mineralization inhibitory phosphatase ions, thus stimulate the calcification.

PRP stimulates healing mechanism in the exposed pulp tissue through the same approach in stimulating the formation of new bone in the treatment of periodontal defects and maxillofacial surgery.^[13] PRP has mitogenic effects that affect proliferation and differentiation odontoblast.^[10] Several growth factors and their receptors can be detected in the levels of mRNA and protein for growing teeth.^[13] Therefore, the growth factor has an important role in the proliferation and differentiation of odontoblast cells.

The ability of growth factors to enhance the process of dentinogenesis, in particular the formation of reparative dentin so far unclear. The administration of exogenous growth factors in exposed dentin have potential in the process of reparative dentin formation signaling,^[14] and the synergistic interaction between the two types of growth factors are needed to induce proliferation and differentiation cells.^[15] Some of the growth factors contained in PRP.^[6]

Other pulp capping material gives different effect such Biodentine, mineral trioxide aggregate Angelus, and Dycal can act as antibacterial agent.^[16] Ethylenediaminetetraacetic acid has an effect on hardness of radicular dentin.^[17]

CONCLUSION

It can be concluded that calcium hydroxide ($\text{Ca}(\text{OH})_2$) and PRP as a pulp capping have no increased expression of nestin just under an open lesion on the

pulp. PRP as a direct pulp capping has an influence on the expression of nestin in a place away from the lesion.

Financial support and sponsorship

Nil.

Conflicts of interest

There are no conflicts of interest.

REFERENCES

- Hargreaves KM, Goodis HE, Seltzer and Bender's: Dental Pulp. China: Books Quintessence Pub Co Inc.; 2002.
- Mjor IA. Pulp Dentin Biology in Restorative Dentistry. Chicago: Quintessence Pub Inc.; 2002.
- Suardita K. The role of fibroblast growth factor-2 in pulp fibroblast cell proliferation. *Majalash Kedokt Gigi* 2008;15:191-4.
- Tetsuaki M, Satoshi Y. *In vitro* effect of platelet-derived growth factor on dentinogenesis in dental pulp cells. *Jpn J Conserv Dent* 2005;48:332-41.
- Ouyang XY, Qiao J. Effect of platelet-rich plasma in the treatment of periodontal intrabony defects in humans. *Chin Med J (Engl)* 2006;119:1511-21.
- Carlson NE, Roach RB Jr. Platelet-rich plasma: Clinical applications in dentistry. *J Am Dent Assoc* 2002;133:1383-6.
- Kuratate M, Yoshiba K, Shigetani Y, Yoshiba N, Ohshima H, Okiji T. Immunohistochemical analysis of nestin, osteopontin, and proliferating cells in the reparative process of exposed dental pulp capped with mineral trioxide aggregate. *J Endod* 2008;34:970-4.
- Lu Y, Liu T, Li H, Pi G. Histological evaluation of direct pulp capping with a self-etching adhesive and calcium hydroxide on human pulp tissue. *Int Endod J* 2008;41:643-50.
- Petrovic V. The effect of hydroxyapatite and platelet-rich plasma on apexogenesis in monkeys. *Acta Vet (Beograd)* 2009;59:277-89.
- Anila S, Nadakumar K. Application of platelet rich plasma for regenerative therapy in Periodontics. *Trends Biomater Artif Organs* 2006;20:78-83.
- Murray PE, Windsor LJ, Smyth TW, Hafez AA, Cox CF. Analysis of pulpal reactions to restorative procedures, materials, pulp capping, and future therapies. *Crit Rev Oral Biol Med* 2002;13:509-20.
- Smith AJ. Vitality of the dentin-pulp complex in health and disease: Growth factors as key mediators. *J Dent Educ* 2003;67:678-89.
- Rieck P, Oliver L, Engelmann K, Fuhrmann G, Hartmann C, Courtois Y. The role of exogenous/endogenous basic fibroblast growth factor (FGF2) and transforming growth factor beta (TGF β -1) on human corneal endothelial cells proliferation *in vitro*. *Exp Cell Res* 1995;220:36-46.
- Werther GA, Cheesman H, Russo V. Olfactory bulb organ culture is supported by combined insulin-like growth factor-I and basic fibroblast growth factor. *Brain Res* 1993;617:339-42.
- Kim SG, Chung CH, Kim YK, Park JC, Lim SC. Use of particulate dentin-plaster of Paris combination with/without platelet-rich plasma in the treatment of bone defects around implants. *Int J Oral Maxillofac Implants* 2002;17:86-94.
- Koruyucu M, Topcuoglu N, Tuna EB, Ozel S, Gencay K, Kulekci G, *et al.* An assessment of antibacterial activity of three pulp capping materials on *Enterococcus faecalis* by a direct contact test: An *in vitro* study. *Eur J Dent* 2015;9:240-5.
- Yassen GH, Al-Angari SS, Platt JA. The use of traditional and novel techniques to determine the hardness and indentation properties of immature radicular dentin treated with antibiotic medicaments followed by ethylenediaminetetraacetic acid. *Eur J Dent* 2014;8:521-7.