

# Full-mouth rehabilitation of Class II deep-bite patient: A 5-year clinical report

Gulfem Ergun<sup>1</sup>, Erdal Bozkaya<sup>2</sup>

**Correspondence:** Dr. Gulfem Ergun  
Email: [ergungulfem@yahoo.com](mailto:ergungulfem@yahoo.com)

<sup>1</sup>Department of Prosthodontics, Faculty of Dentistry, Gazi University, Ankara, Turkiye,

<sup>2</sup>Department of Orthodontics, Faculty of Dentistry, Gazi University, Ankara, Turkiye

## ABSTRACT

This case report demonstrates the full-mouth rehabilitation of a 45-year-old male patient with severe deep-bite by increasing vertical dimension. The technique of anterior maxillary osteotomy performed in the present situation has been found to be effective, requiring anterior and inferior repositioning of the anterior maxilla to provide an esthetic and functional implant supported fixed prosthesis. Four months after surgery, the fixation system was removed, and 6 dental implants were placed. The anterior and inferior movements of the segment allowed for natural tooth anatomy and size in the definitive implant supported partial fixed prosthesis. A satisfactory functional and esthetic result was obtained after 5 years of follow-up.

**Key words:** Anterior maxillary osteotomy, Class II deep-bite, full-mouth rehabilitation, implant

## INTRODUCTION

To establish the desirable occlusion and articulation with proper inclination of teeth in deep-bite patients, orthodontic therapy alone is difficult and inefficient.<sup>[1,2]</sup> Therefore, orthognathic surgical procedures, which reconstruct occlusal plane by aligning teeth or correcting skeletal deformities, are preferred to obtain functional and marked esthetic results.<sup>[3-5]</sup> Since these procedures support the patient both physically and psychologically, they are constructive for the patient. In fact, these procedures could simplify the prosthodontic phase of treatment without damaging the tooth structure.<sup>[3,4]</sup>

Anterior segmental osteotomy is an important surgical procedure for the correction of maxillary and mandibular protrusion or retrusion to achieve improved occlusion and facial profile.<sup>[6-9]</sup> This osteotomy procedure is

primarily for correction of bimaxillary dentoalveolar protrusion, anterior open bite, excessive inclination of anterior teeth, excessive vertical, or anteroposterior development of the maxillary dentoalveolar process and severe skeletal problems that cannot be corrected with orthodontic treatment.<sup>[8,10]</sup>

It is difficult to achieve ideal facial proportions by increasing lower anterior facial height. In addition, the decreased vertical dimension of occlusion (VDO) in deep-bite patients can also cause unpleasant esthetic results, reduced masticatory capacity, muscle atrophy and pulpal sensitivity.<sup>[11-13]</sup> A progressive approach should be followed to restore VDO.<sup>[14]</sup> For such situations, occlusal splints, fixed or removable partial dentures are recommended as treatment alternatives.<sup>[15,16]</sup>

This is an open access article distributed under the terms of the Creative Commons Attribution-NonCommercial-ShareAlike 3.0 License, which allows others to remix, tweak, and build upon the work non-commercially, as long as the author is credited and the new creations are licensed under the identical terms.

**For reprints contact:** [reprints@medknow.com](mailto:reprints@medknow.com)

**How to cite this article:** Ergun G, Bozkaya E. Full-mouth rehabilitation of Class II deep-bite patient: A 5-year clinical report. *Eur J Dent* 2016;10:426-31.

**DOI:** 10.4103/1305-7456.184160

Access this article online	
Quick Response Code: 	Website: <a href="http://www.eurjdent.com">www.eurjdent.com</a>

The aim of the treatment was to reduce the anterior deep-bite and overjet by intrusion of the maxillary incisors to correct the maxillary protrusion. Additionally, the second aim was to create an adequate space for an implant supported fixed prosthesis through multidisciplinary treatment approaches including orthodontic, surgical, and prosthetic procedures.

## CASE REPORT

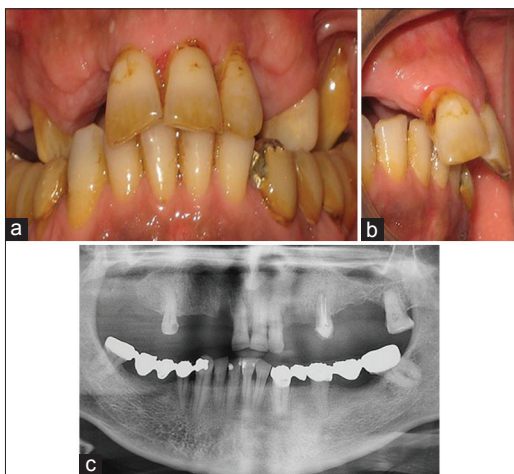
A 45-year-old male patient had been admitted to Gazi University, Department of Oral and Maxillofacial Surgery, with a chief complaint of difficulty in chewing and an unattractive smile. The patient had no history of general medical complaints. In addition, no masticatory muscle hyperactivity and temporomandibular dysfunction were observed. Extraoral examination showed a reduction in the lower facial height, protuberant lips, wrinkles, drooping, overclosed commissures, and excessive gingival display caused by collapsed VDO. Furthermore, the pretreatment profile demonstrated a marked protrusion of the maxilla with partial edentulism. The patient had poor oral hygiene. Besides, no pocket depth of over 2 mm or mobility was observed around any of the remaining teeth.

The intraoral and radiographic examination verified that #12, #13, #14, #24, #16, #17, #23, #24, #26, #27, #35, #36, #37, #44, and #46 teeth were lost [Figure 1]. During the clinical examination of the patient by the orthodontist, convex profile with upper lip protrusion and gummy smile were detected. He also had severe deep-bite and increased overjet with anterior maxillary protrusion [Figure 1]. Since the cephalometric analysis

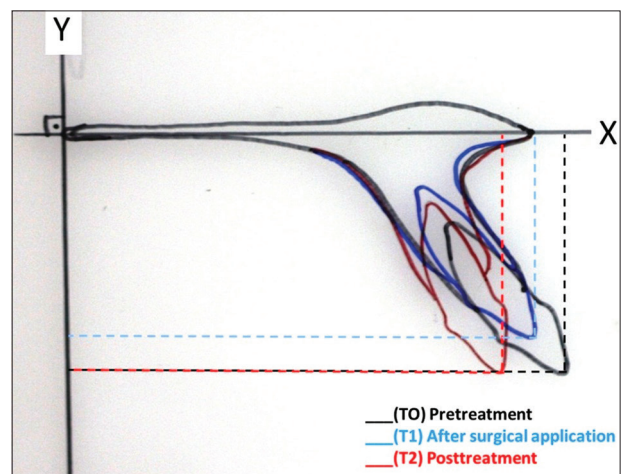
showed that maxillary central incisors were proclined ( $1-NA = 17^\circ$ ,  $1/NA = 44^\circ$ ,  $1/ANS\ PNS = 127^\circ$ ), the overjet was not within normal ranges (14 mm) [Figures 2 and 3].

The treatment plan was formulated in consultation with a prosthodontist, orthodontist, and an oral-maxillofacial surgeon. First, a diagnostic setup was constructed by the prosthodontist. Then, an interocclusal record was prepared with a polyvinyl-siloxane occlusal registration material (Exabite II; GC Corp., Tokyo, Japan) on a semi-adjustable articulator (Stratos 200, Ivoclar, Vivadent, Germany) using a face-bow record. Following a careful evaluation of the patient, a 7 mm loss of VDO was determined. The patient had no maxillary canines or posterior teeth to provide anchorage for retraction or intrusion of maxillary incisors.

Treatment alternatives were explained to the patient. First, the patient was young and did not want to use a partial prosthesis. Second, implant supported full-mouth fixed restorations were suggested. He also rejected this option because of the difficulties that might occur during establishing esthetic at anterior region. Therefore, to restore the lost VDO with severe deep-bite and stabilize the maxillary anterior segment in its desired position, increase the VDO by provisional removable partial prosthesis following subapical anterior maxillary segmental osteotomy. Then, full-mouth rehabilitation with implant-teeth supported metal-ceramic restorations was considered. Finally, stabilizing the maxillary anterior segment in the desired position by surgical therapy and the restoration of the edentulous maxillary posterior regions with 6 implants was suggested to the patient.



**Figure 1:** Preoperative intraoral view. (a) From facial aspect. (b) From right side. (c) Panoramic radiograph



**Figure 2:** Maxillary superposition, T0: Pretreatment, T1: After surgery, T2: After prosthetic rehabilitation

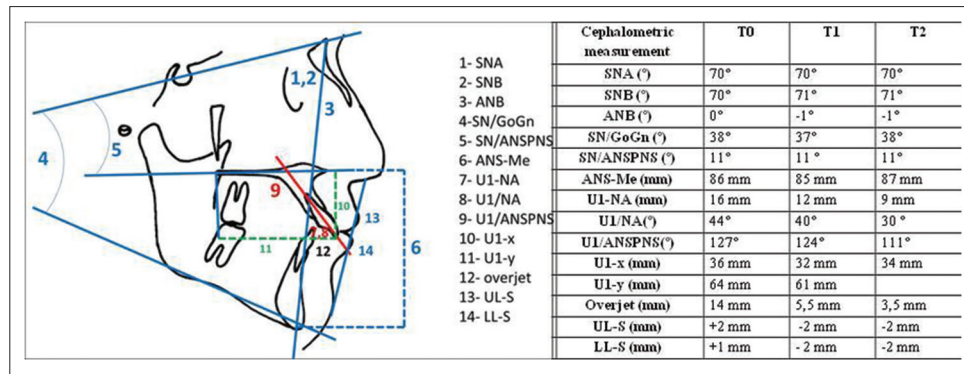


Figure 3: Cephalometric measurements of the patient, T0: Pretreatment, T1: After surgery, T2: After prosthetic rehabilitation

The patient gave written informed consent before the treatment. Then, anterior segmental osteotomy was performed [Figure 4]. Four months after surgery, the fixation system was removed [Figure 5a and b]. After the surgical stage, the maxillary incisors were retruded by 3 mm and impacted for 4 mm according to cephalometric superimpositions [Figure 3].

The occlusal vertical dimension was determined by the Niswonger method<sup>[17]</sup> and verified with the closest speaking space method. The space between lower centric occlusion line and the upper closest speaking line was named as the closest speaking space.<sup>[18]</sup> The centric relation was recorded with the interocclusal registration method. The patient's freeway space was 7 mm (difference between rest vertical dimension and VDO). Following the impaction of maxillary incisors for 4 mm, the new occlusal vertical dimension was set by approximately 3 mm increase using the incisal guidance pin of the articulator. At the first stage of the rehabilitation, a provisional removable restoration was fabricated at increased VDO as a guide for the definitive oral rehabilitation [Figure 5c] to be used for 3 months. The proper VDO was determined by using the physiologic rest position of the mandible as a guide and noting the existing interocclusal distance. Totally, VDO was increased for 7 mm. The patient's mastication, muscle sensitivity, temporomandibular junction pain, phonation and anterior and posterior speaking space were evaluated in this period. No muscle hyperactivity or temporomandibular discomfort was detected.

Extensive clinical examination, including prosthetic workups, revealed that misaligned maxillary second premolar teeth would not support functional or esthetic prosthetic restoration. Besides, there was inappropriate mesiodistal space for ideal implant placement. Therefore, these teeth were extracted

before implant surgery. Totally 6 implants were planned by the prosthodontist in cooperation with the surgeon. Mounted diagnostic guides were used by the surgeon. Six dental implants (4 units 4.1 mm × 10 mm and 2 units 4.8 mm × 10 mm; Standard Plus implants, Straumann AG, Basel, Switzerland) were placed to the maxillary arch (#14, #15, #17, #23, #24, and #26) in accordance with the prosthetic and surgical guidance. Additionally, #11, #21, and #22 teeth were prepared and provisional fixed restorations were made at increased VDO [Figure 6a]. Standard oral hygiene instructions were given to the patient immediately after surgery. Six months after the first surgery, second-stage surgery was performed. For soft-tissue healing around implants, the healing abutments were left in place for 3 weeks.

In consultation with the patient, full-mouth metal ceramic crowns were considered to be the best therapeutic option. Then, teeth were prepared with circumferential shoulder margins of 1–1.2 mm and an occlusal reduction of 1.5–2 mm [Figure 6b]. Provisional restorations were prepared by the dental technician and cemented temporarily (Temp Bond NETM; Kerr). The protrusive contact, canine guidance, esthetics, and phonetics were assessed, and 1- and 2-monthly regular checkups were performed. Definitive impressions of all teeth and abutments were made with a polyether impression material (Impregum, 3M ESPE, St. Paul, MN, USA). The models were mounted using an arbitrary facebow (Dentatus AED, Dentatus USA Ltd., NY, USA) and a centric relation record was obtained using polyether bite registration material (Ramitec, 3M ESPE) on a semi-adjustable articulator (Dentatus ARH, Dentatus USA Ltd.). After surgery, the overjet was 9.5 mm. Following prosthetic rehabilitation, the overjet was improved from 9.5 mm to 2.0 mm. The increased angle of the maxillary incisors was within normal range.



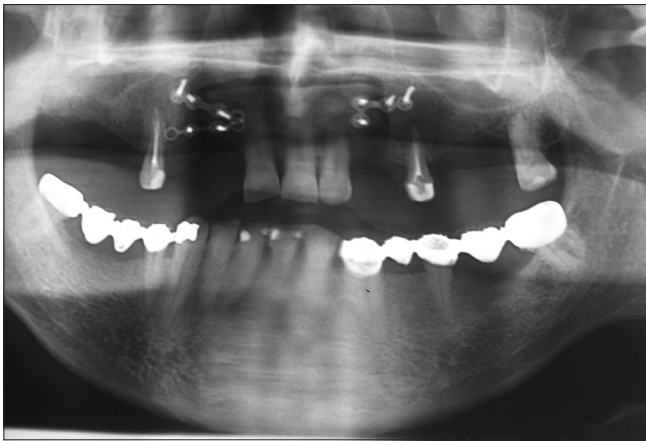

Figure 4: Panoramic radiograph after osteotomy

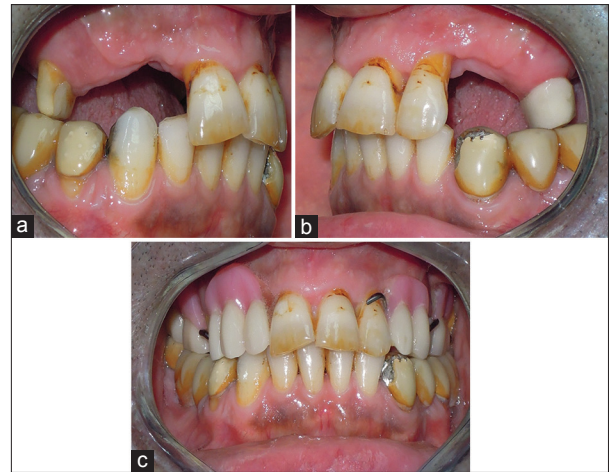

Figure 5: Intraoral view after osteotomy. (a) From right side. (b) From left side. (c) Provisional removable restoration

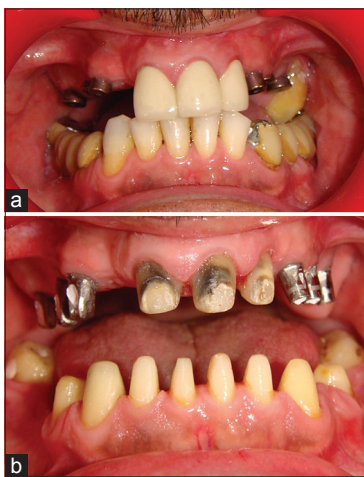

Figure 6: Intraoral view. (a) Following implant placement. (b) After preparation of the teeth

The canine-guided occlusion was established [Figure 7a and b]. The patient was checked at 1, 2 weeks, 1, 3, 6, and 12 months and then examined annually by visual and radiographic examinations [Figure 7c]. The patient acknowledged improved function and esthetics, and was pleased with the results [Figure 7b]. The cephalometric analysis of the patient before and after surgery and following prosthetic rehabilitation is given in Figure 8. Follow-up panoramic radiographs were taken after treatment and annually for up to 5 years. A satisfactory functional and esthetic result was obtained after 5 years of follow-up [Figure 9].

## DISCUSSION

To restore the dentition and improve the facial appearance in the present case, the VDO had to be increased to approximately 7 mm. However, there was no adequate dentition for orthodontic anchorage. Therefore, 4 mm incisor intrusion was achieved by

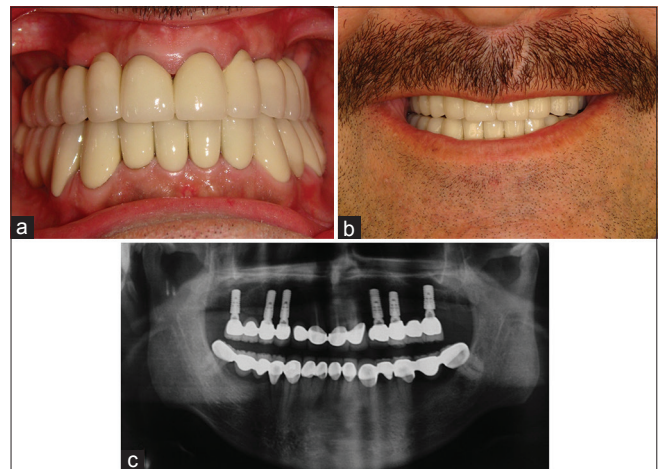
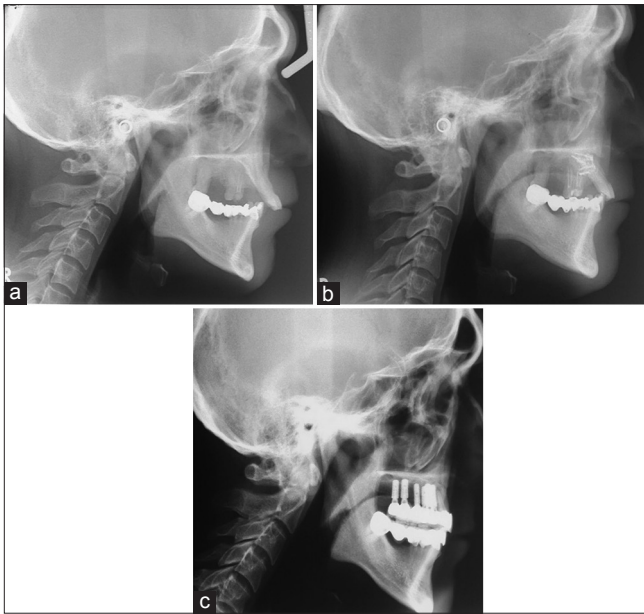


Figure 7: (a) Postoperative intraoral view of implant supported fixed restorations. (b) Postoperative smile of the patient. (c) Postoperative panoramic radiograph

anterior segmental osteotomy. At the end of treatment, the cephalometric measurements showed a relative increase in VDO [Figure 8c].

Anterior maxillary osteotomy is the most aggressive but multi-purpose treatment option for patients having bimaxillary protrusion and/or dentoalveolar protrusion with severe extrusion.<sup>[8]</sup> In the present clinical report, the osteotomy line was kept well above the apices of the laterals and the apices of teeth were protected without any damage. Besides, for restoring the vertical height, the teeth (#11, #21, and #22) had root canal treatment, before preparation procedures. The implant placement following virtual planning of implant positions was performed according to the multidisciplinary treatment approach which included a maxillofacial surgeon and prosthodontist. Overall, surgery and prosthetic rehabilitation resulted in

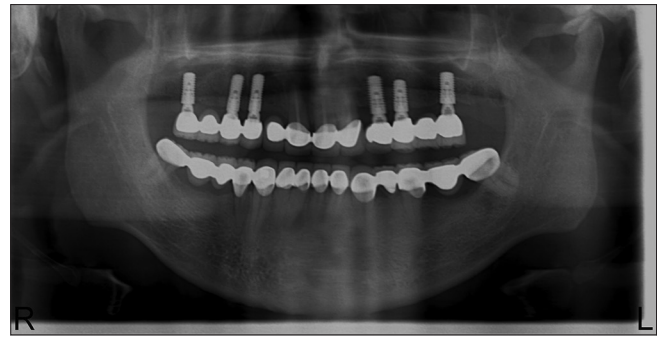

**Figure 8:** The cephalometric analysis of the patient. (a) Preoperative. (b) After surgery. (c) After prosthetic rehabilitation

greater reduction of overjet (12 mm) and greater improvement in skeletal and dental aspects.

In the present case, increasing vertical dimension with removable denture following fixed restoration of the remained teeth in upper jaw could be a treatment alternative to surgery, because surgical reconstruction might have disadvantages including the costs, length of recovery, and surgical complications. However, the patient was young and preferred not to use a removable prosthesis. Additionally, full-mouth restoration including implants in the posterior region could be used as prosthetic method for increasing the VDO. However, there would be difficulties in increasing VDO by 7 mm without surgery.

A previous study indicated that increasing VDO by restorative procedures should be undertaken cautiously, since this procedure disrupts a patient's dental physiology and adaptation.<sup>[13]</sup> In addition, it was reported that the patient can adapt a 5 mm increase in VDO. However, it is impossible to determine the upper limit.<sup>[19]</sup> Therefore, correction of dentofacial deformity caused by the lost VDO was treated partially with surgical procedures (4 mm intrusion) and partially by fixed restorations. Besides, the increase in VDO should be achieved with fixed restorations rather than a removable denture, since it improves function and esthetics and is therefore more predictable for patient adaptation.<sup>[19]</sup>



**Figure 9:** Panoramic radiograph after 5 years of follow-up

Previous studies indicated that the testing period of increased VDO with provisional restorations could be 2–6 months.<sup>[13,14]</sup> The use of removable partial dentures was suggested as provisional restorations for the patients with decreased VDO.<sup>[18]</sup> During a 3-month period, the patient was carefully evaluated to assess the adaptation to the VDO obtained with a removable prosthesis.

A mutually protected articulation was used to rehabilitate the present patient with provisional and definitive restorations. Furthermore, the patient had increased overbite and marked protrusion at the beginning of the treatment [Figure 1]. Both the facial appearance and the occlusion were significantly improved at the end of the prosthetic rehabilitation [Figure 7].

## CONCLUSION

The prosthetic restorations performed in the present case report improved the quality of life of the patient. Furthermore, dental practitioners should keep in mind that conventional prosthetic treatment might often be all that is needed for patients with skeletal problems.

## Acknowledgement

The authors wish to thank Assoc. Prof. Suleyman Bozkaya for his great effort and expert in surgical part of this case.

## Financial support and sponsorship

Nil.

## Conflicts of interest

There are no conflicts of interest.

## REFERENCES

1. Bell WH, Jacobs JD, Legan HL. Treatment of class II deep bite by orthodontic and surgical means. *Am J Orthod* 1984;85:1-20.
2. Matsushita K, Inoue N, Yamaguchi HO, Ooi K, Totsuka Y. Tooth-borne

- distraction of the lower anterior subapical segment for correction of class II malocclusion, subsequent to genioplasty. *Oral Maxillofac Surg* 2011;15:183-8.
3. Finlay PM, Atkinson JM, Moos KF. Orthognathic surgery: Patient expectations; psychological profile and satisfaction with outcome. *Br J Oral Maxillofac Surg* 1995;33:9-14.
  4. Basa S, Varol A, Sener ID, Sertgoz A. Posterior maxillary segmental osteotomy for restoring the mandible with dental implants: A clinical report. *J Prosthet Dent* 2008;99:340-3.
  5. Oz AZ, Akcan CA, El H, Ciger S. Evaluation of the soft tissue treatment simulation module of a computerized cephalometric program. *Eur J Dent* 2014;8:229-33.
  6. Dai J, Hu G, Wang X, Tang M, Dong Y, Yuan H, *et al.* CBCT combining with plaster models: Application in virtual three-dimensional subapical segmental osteotomy to obtain more precise occlusal splint. *J Craniofac Surg* 2012;23:1759-62.
  7. Park JU, Hwang YS. Evaluation of the soft and hard tissue changes after anterior segmental osteotomy on the maxilla and mandible. *J Oral Maxillofac Surg* 2008;66:98-103.
  8. Gunaseelan R, Anantanarayanan P, Veerabahu M, Vikraman B, Sripal R. Intraoperative and perioperative complications in anterior maxillary osteotomy: A retrospective evaluation of 103 patients. *J Oral Maxillofac Surg* 2009;67:1269-73.
  9. Bell RE. Palatal approach to the anterior maxillary sandwich osteotomy. *J Oral Maxillofac Surg* 2013;71:1005-9.
  10. Uzuner FD, Darendeliler N. Dentoalveolar surgery techniques combined with orthodontic treatment: A literature review. *Eur J Dent* 2013;7:257-65.
  11. Guttal S, Patil NP. Cast titanium overlay denture for a geriatric patient with a reduced vertical dimension. *Gerodontology* 2005;22:242-5.
  12. Ergun G, Cekic-Nagas I. Implant-prosthetic rehabilitation of a patient with nonsyndromic oligodontia: A clinical report. *J Oral Implantol* 2012;38:497-503.
  13. Cekic-Nagas I, Ergun G. Implant-supported prosthetic rehabilitation of a patient with localized severe attrition: A clinical report. *J Prosthodont* 2015;24:322-8.
  14. Song MY, Park JM, Park EJ. Full mouth rehabilitation of the patient with severely worn dentition: A case report. *J Adv Prosthodont* 2010;2:106-10.
  15. Ergun G, Yucel AS. Full-mouth rehabilitation of a patient with severe deep bite: A clinical report. *J Prosthodont* 2014;23:406-11.
  16. Windchy AM, Morris JC. An alternative treatment with the overlay removable partial denture: A clinical report. *J Prosthet Dent* 1998;79:249-53.
  17. Niswonger ME. Rest position of mandible and centric relation. *JADA* 1934;21:1572-82.
  18. Silverman MM. The comparative accuracy of the closet-speaking-space and the freeway space in measuring vertical dimension. *J Acad Gen Dent* 1974;22:34-6.
  19. Abduo J, Lyons K. Clinical considerations for increasing occlusal vertical dimension: A review. *Aust Dent J* 2012;57:2-10.