

Case report

Autonomous Functioning Thyroid Nodule in a 4-year-old Male Child Treated with Radioiodine (I-131)

Abhishek Khare, Puneet Bhutani, Suneel Chauhan

Department of Nuclear Medicine and PET/CT, Army Hospital (R and R), New Delhi, India

Abstract

Autonomous functioning thyroid nodules that cause toxic manifestations (toxic adenomas) are benign monoclonal tumors characterized by their capacity to grow and produce thyroxine (T4) and triiodothyronine (T3) autonomously, i.e. in the absence of thyrotropin thyroid stimulating hormone. Toxic adenomas are a rare presentation of hyperthyroidism in the pediatric population. Radioiodine (I-131) has been widely used for therapy of patients with toxic adenomas and is now accepted as a safe and effective treatment even in the pediatric age group. The authors here present a case of a 4-year-old boy with a solitary hyperfunctioning thyroid nodule, who was successfully treated with radioiodine (I-131) and is presently on follow-up.

Keywords: Autonomous functioning thyroid nodule, radioiodine (I-131), thyroid function tests

Introduction

Nodules with these properties are said to be hyperfunctioning adenomas and constitute approximately 5% of all solitary thyroid nodules. A toxic adenoma probably evolves gradually from a small autonomously hyperfunctioning adenoma that initially is only slightly more active than the extranodular tissue and which contributes little to overall thyroid secretion. As the adenoma grows, its contribution to thyroid secretion increases and thyroid stimulating hormone (TSH) secretion therefore decreases. The clinical expression of these properties is the presence of a palpable thyroid nodule that concentrates radioiodine (I-123/131) or pertechnetate (^{99m}Tc) scintigraphically manifests as a decrease in the radiotracer uptake of the extranodular thyroid tissue. This decrease results in decreased function of the extranodular tissue and hence that its ability to concentrate radionuclide decreases. With further growth, thyroid secretion becomes supranormal and TSH secretion becomes unequivocally low, so that the

extranodular tissue takes up little if any radionuclide and the patient develops overt thyrotoxicosis.^[1]

Case Report

The present case report is about a 4-year-old male child presented in May 2010 with a history of insidiously increasing swelling left side in the neck. Mother had first noted this swelling at 8 months age. This was slow growing since then. For the last 1 year, there was rapid growth in the size of the swelling. Child was getting progressively hyperactive and irritable. Clinically the child had attention deficit, tachycardia (Pulse rate-106/min., regular), Eye signs were positive with moist and warm Palms. Local Exam (Neck) revealed a 6 × 7 cm, firm non-tender swelling in the left side of the neck. The swelling moved with deglutition. There was no inspiratory stridor. Lower border of the swelling was palpable. The neck vessels were normal. Thyroid function was deranged with subnormal thyrotropin (TSH) and elevated T3 and T4 [Figure 1].

Ultrasonogram (neck) revealed an enlarged Left lobe of thyroid (measuring – 4.3 × 2.5 × 6.4 cm) and replaced by multiple various size cystic lesion with thin walled septa. Rt lobe (measured 6 × 5 × 8 mm) was comparatively smaller in size with normal echotexture. There was no neck lymphadenopathy. ^{99m}Tc Thyroid Scan revealed hot nodule involving the left lobe with suppression of extra nodular thyroid activity. The findings were

Access this article online

Quick Response Code:



Website:

www.wjnm.org

DOI:

10.4103/1450-1147.136695

Address for correspondence:

Dr Abhishek Khare, Department of Nuclear Medicine and PET/CT, Army Hospital (R and R), New Delhi - 110 010, India. E-mail: drakhare@gmail.com

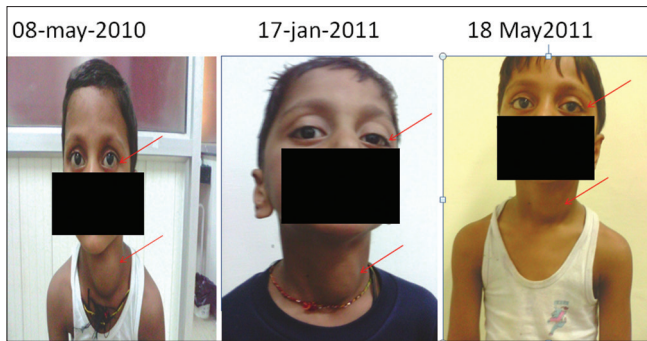

Figure 1: Clinical appearance (on treatment and follow-up)

suggestive of a hyperfunctioning nodule involving the left lobe of the thyroid.

The child was empirically treated with 10 mCi radioiodine (I-131) orally on 14 July 2010. The child was serially followed on clinical, thyroid function tests (TFT's) and 99 m-Tc scintigraphic parameters. The child is still on follow-up and in past 1 year has shown remarkable improvement both clinically, TFT's and scintigraphically. The patients signs and symptoms have now normalized and TFT parameters are within normal limits. Scintigraphically though the picture suggests partial resolution of the hyperfunctioning nodule [Figure 2].

Discussion

Autonomous functioning thyroid nodules (AFTN) are very rare in children. Activating mutations of the genes encoding the thyrotropin thyroid stimulating hormone receptor and the alpha subunit of Gs (GNAS1) have recently been described in AFTN.^[2] The youngest case reported is of a 22 month child with a large hyperfunctioning thyroid nodule who became overtly hyperthyroid after iodinated contrast administration.^[3] The treatment options are - antithyroid drugs, surgery and radioiodine (I-131). Hyperthyroidism due to thyroid nodular disease is permanent and there are no spontaneous remissions. Anti-thyroid medications may decrease thyroid hormone secretion but are not appropriate for long term therapy. Similarly, surgery can be reserved for large multinodular goiters, which produce compression or cosmetic disfigurement.

After discussion with concerned specialists and counseling of the parents, radioiodine (I-131) treatment was decided for this child.

A review of recent literature reveals that radioiodine (I-131) is an effective choice of treatment for pediatric

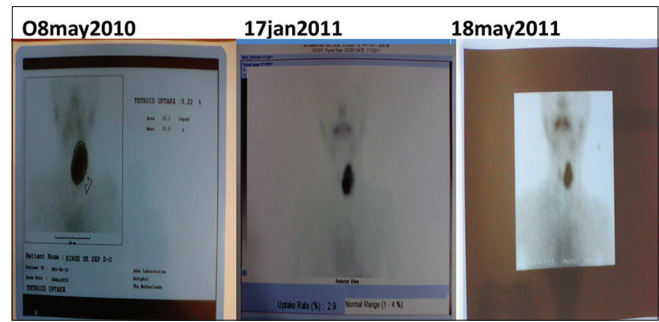


Figure 2: Scitigraphic appearance (on treatment and follow-up)

hyperthyroidism and is not associated with increased risk of cancer when recommended doses are used.

The co-operative thyrotoxicosis therapy follow-up study also showed that thyroid neoplasms developed in children treated with lower rather than higher doses of I-131. The incidence of thyroid adenomas was more in children treated with low dose (approximately 30 μ Ci/gm rather than 110-200 μ Ci/g).^[4] Regarding efficacy of dosages administered, in a study published by Morteza Taghavi, MD and Hatami Ghazal, MD in Thyroid Science on evaluating 780 patients with hyperthyroidism during a 7-year period who were treated with a fixed dose of radioiodine (I-131) concluded that a cure rate of 93.8% can occur within 6 months with a fixed and uncalculated dose of radioiodine. This result was similar to the results of treatment with calculated dose of radioiodine.^[5]

References

1. Werner SC, Ingbar SH, Braverman LE, Utiger RD, eds. Werner and Ingbar's The Thyroid: A Fundamental and Clinical Text. 8th ed. Philadelphia, PA: Lippincott Williams and Wilkins; 2000:564-572.
2. Nyuzuki H, Nagasaki K, Matsuyama H, Tomita M, Imai C, Ogawa Y, et al. Autonomously functioning thyroid nodule in a four-year-old boy with Sotos syndrome. *Pediatr Int* 2011;53:137-8.
3. Namba H, Ross JL, Goodman D, Fagin JA. Solitary polyclonal autonomous thyroid nodule: A rare cause of childhood hyperthyroidism. *J Clin Endocrinol Metab* 1991;72:1108-12.
4. Dobyns BM, Shekine GE, Workman JB, Tompkins EA, McConahey WM, Becker DV. Malignant and benign nodules of thyroid in patients treated for hyperthyroidiam. *J Clin Endocrinol Metab* 1974;38:976-98.
5. Taghavi M, Ghazal H. Outcome of fixed and uncalculated dose of radioiodine the treatment of hyper functioning thyroid nodules. *Thyroid Sci* 2010;6:1-3.

How to cite this article: Khare A, Bhutani P, Chauhan S. Autonomous Functioning Thyroid Nodule in a 4-year-old Male Child Treated with Radioiodine (I-131). *World J Nucl Med* 2013;12:65-6.

Source of Support: Nil, **Conflict of Interest:** None declared.