

Case report

^{99m}Tc DTPA renogram identifies Bochdalek hernia with an intra thoracic kidney as its content

Subramanyam Padma, Shantanu R. Pande, Palaniswamy Shanmuga Sundaram

Department of Nuclear Medicine and PETCT, Amrita Institute of Medical Sciences, Cochin, Kerala, India

Abstract

Congenital diaphragmatic hernia (CDH) is a rare anomaly with reported incidence of 1 in 16,000 and is associated with herniation of stomach, intestinal loops, spleen, and kidney through a chest wall defect. We report a case of 1-year-old male child with history of recurrent fever and non-visualization of left kidney on ultrasonogram. Patient was referred to us to look for ectopic left kidney. ^{99m}Tc -diethylenetriaminepentaacetic acid renogram was performed. An ectopically placed intrathoracic left kidney was identified. Subsequently a chest X-ray was done that showed bowel loops and diagnosis of CDH was confirmed. The patient underwent thoracoscopic repair of CDH and hernial contents were found to be left kidney, intestinal loops and spleen.

Keywords: Bowel in thorax, diaphragmatic hernia, diethylenetriamine pentaacetic acid renogram, intrathoracic kidney

Introduction

Congenital diaphragmatic hernia (CDH) is a rare anomaly with reported incidence of 1 in 16,000 population and is associated with herniation of stomach, intestinal loops, spleen, and kidney through a chest wall defect. The situation turns grave when these herniating contents prevent the normal development of lung parenchyma in antenatal and neonatal period. Diagnosis can be made by prenatal ultrasonogram (USG) examination, but its accuracy can be limited by poor acoustic contrast between fetal lung, herniated viscera and, position of fetus.

Case Report

An 1-year-old male child (First born child of a non-consanguineous marriage, full term normal

delivery) presented to our pediatrics department with history of recurrent fever with occasional chills and rigor in past 4 months. There was no associated history of cough, dyspnea, or seizures. Patient has attained normal milestones. Baby was suspected to have urinary tract infection. Routine urine microscopic test was performed that was reported as normal. Clinical examination was normal. There was no clinical suspicion of upper respiratory tract infection. Patient was subsequently sent for an abdominal USG examination to rule out any intra-abdominal mass and also to further evaluate the kidneys as there was phimosis. USG reported non-visualization of left kidney.

Child was then referred for further evaluation by ^{99m}Tc -diethylenetriamine pentaacetic acid (^{99m}Tc DTPA) renogram to rule out an ectopically placed left kidney. An intravenous (IV) line was secured and oral sedation was given (trichlofos at a dosage of 0.5-1 mg/kg body weight). Once sedated, patient was injected with 3 mCi of Tc DTPA IV under the gamma camera. Initial dynamic images (renal angiogram) were acquired at 2 s/frame for 60 s followed by extraction phase images at the rate of 15 s/frame for 20 min. An ectopically placed, normally functioning left kidney was seen in thorax just beside the heart. Right kidney was normally

Access this article online

Quick Response Code:



Website:
www.wjnm.org

DOI:
10.4103/1450-1147.144821

Address for correspondence:

Dr. Subramanyam Padma, Clinical Professor, Department of Nuclear Medicine and PETCT, Amrita Institute of Medical Sciences, Cochin -41, Kerala, India. Email: padmas@aims.amrita.edu

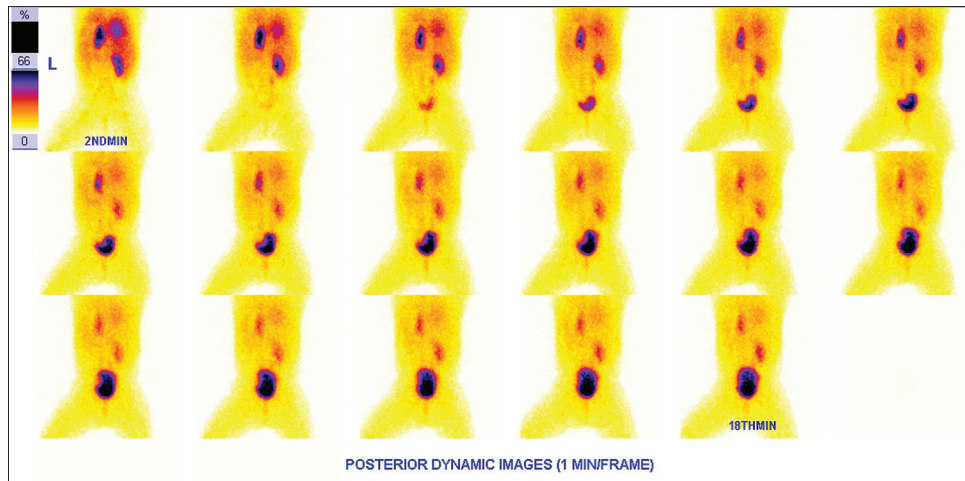


Figure 1: Posterior dynamic images of ^{99m}Tc DTPA renogram were acquired at 2 s/frame for 60 s followed by 15 s/frame for 20 min. Left kidney was found to be ectopically placed in thorax beside the heart. Right kidney was normally placed, normally functioning with no evidence of pelviureteric junction obstruction

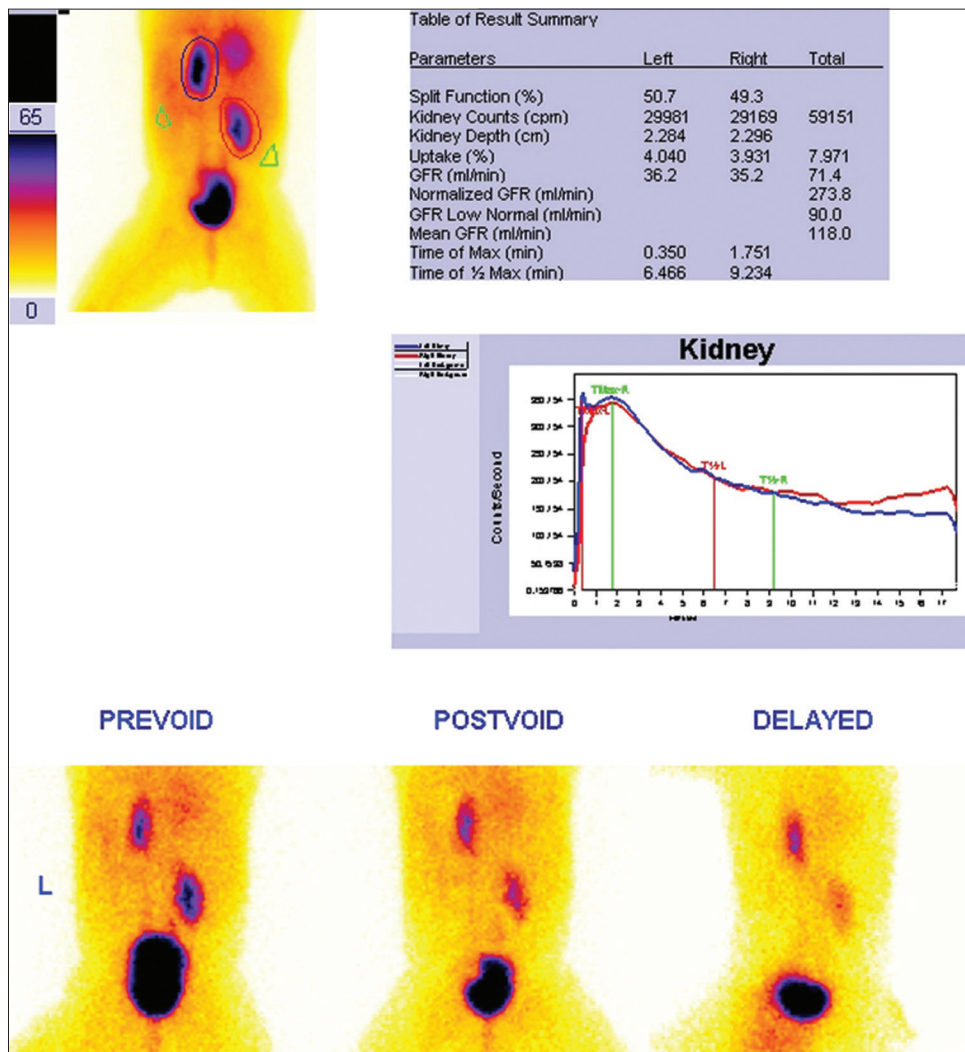


Figure 2: Renogram shows bilaterally pelviureteric junction (PUJ) non-obstructed kidneys. Although the left kidney is intrathoracic in location it is posteriorly placed as evident from the images. Pre-void, post-void and delayed images show no retention of tracer in pelvicalyceal system further confirming bilateral PUJ non-obstruction

placed and normally functioning. Both the kidneys showed no evidence of any pelviureteric junction (PUJ) obstruction [Figures 1 and 2].

Discussion

Intrathoracic kidney is a very rare anomaly with reported incidence of 1 in 16,000 population.^[1-4] Intrathoracic kidney constitutes 5% of all ectopic kidneys. Kidney passes through a defect in the diaphragm into the thorax and not into the pleural cavity. It may get malrotated, or may have a unipolar deviation and have a long ureter. However, unlike pelvic kidney, intrathoracic kidney is generally PUJ non-obstructed.

The diagnosis of CDH, CDH is usually confirmed by a plain chest radiograph that demonstrates loops of intestines in chest.^[5] CDH has a reported incidence of 1 in 2500 and 1 in 4000 live births.^[6,7] The characteristic chest X-ray PA view findings in our patient are (i) herniated bowel loops in left hemithorax (ii) left hemidiaphragm not appreciable separately (iii) tracheal and mediastinal shift to right (iv) clear lung fields (v) no associated pleural effusion [Figures 3 and 4]. Lateral view shows intestinal loops in posterior aspect of hemithorax. This hernia is known as Bochdalek hernia, also called posterolateral diaphragmatic hernia and is the most common manifestation of CDH, accounting for more than 95% of cases.

Diaphragmatic hernias were recognized as far back as the late 17th century. Vincent Alexander Bochdalek in 1848, first described the non-fusion of the posterolateral foramina of the diaphragm. They tend to be unilateral but can be bilateral in 14% of cases, left sided hernias are 5 times more frequent than the right probably because of earlier closure of the right pleuroperitoneal canal than the left. The Bochdalek hernia is usually congenital, arising due to failed closure of the pleuroperitoneal ducts during the 4th and 12th weeks of gestation. If the pleuroperitoneal canal remains open when the intestinal loops return to the abdomen from the umbilical cord during the 10th week, the abdominal viscera move freely into the thoracic cavity. If the pleuroperitoneal canal closes but fails to become muscularized, a hernia with a sac results, as is seen in 10–15% of patients with CDH.^[8] The vast majority of Bochdalek hernias are diagnosed acutely in neonates and infants with associated respiratory symptoms. These patients develop severe respiratory complications that include pulmonary hypoplasia and pulmonary hypertension.

Historically, management of CDH was immediate surgery, but over a period of time it was realized that immediate surgery may not be needed and hence intubation, oxygenation and extracorporeal membrane oxygenation was introduced. Our patient underwent thoracoscopic repair for left sided bochdalek hernia

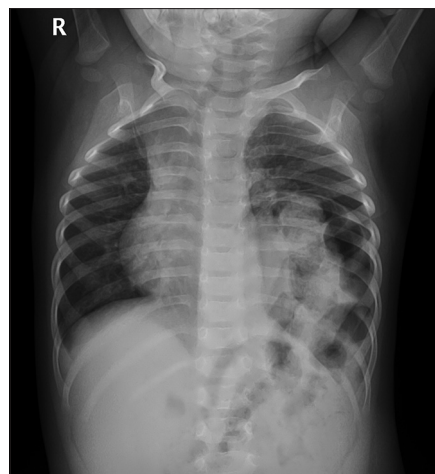


Figure 3: Chest X-ray PA view shows (i) herniated bowel loops in left hemithorax (ii) hemidiaphragm (left) is not separately seen (iii) tracheal and mediastinum are shifted to the right (iv) lung fields are clear (v) no associated pleural effusion seen

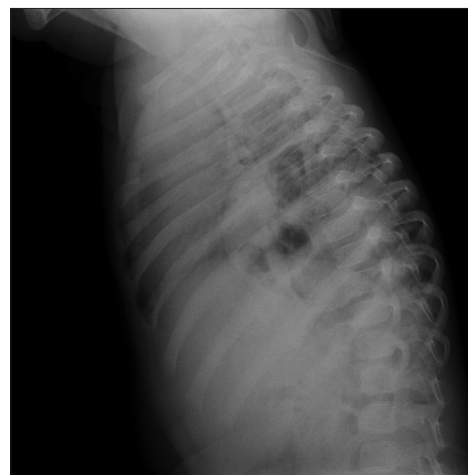


Figure 4: Lateral X-ray of chest shows intestinal loops in posterior aspect of hemithorax

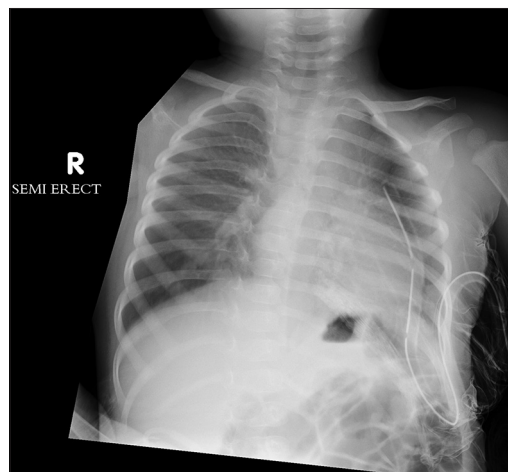


Figure 5: Post-operative chest X-ray image of the same child who underwent thoracoscopic repair for congenital diaphragmatic hernia and the contents of hernia were identified as intestinal loops, spleen and left kidney. The image shows an intercostal drain *in situ*, right apical lung field to be clear and presence of fundic gas bubble below the diaphragm confirming stomach to be normally placed

and contents of hernia were found to be intestinal loops, spleen and left kidney [Figure 5]. Patient had an uneventful post-operative period and is doing well at 6 months follow-up.

References

1. Angulo JC, Lopez JI, Vilanova JR, Flores N. Intrathoracic kidney and vertebral fusion: A model of combined misdevelopment. *J Urol* 1992;147:1351-3.
2. Baillet AM, Escure MN. X-ray computerised tomographic imaging in the diagnosis of intrathoracic kidney. *J Radiol*. 1988 Apr;69(4):269-73.
3. Campbell MF. Renal ectopy. *J Urol* 1930;24:187.
4. Donat SM, Donat PE. Intrathoracic kidney: A case report with a review of the world literature. *J Urol* 1988;140:131-3.
5. Haller JA Jr. Professor Bochdalek and his hernia: Then and now. *Prog Pediatr Surg* 1986;20:252-5.
6. Wenstrom KD, Weiner CP, Hanson JW. A five-year statewide experience with congenital diaphragmatic hernia. *Am J Obstet Gynecol* 1991;165:838-42.
7. Langham MR Jr, Kays DW, Ledbetter DJ, Frentzen B, Sanford LL, Richards DS. Congenital diaphragmatic hernia. Epidemiology and outcome. *Clin Perinatol* 1996;23:671-88.
8. Salaçin S, Alper B, Cekin N, Gülmen MK. Bochdalek hernia in adulthood: A review and an autopsy case report. *J Forensic Sci* 1994;39:1112-6.

How to cite this article: Padma S, Pande SR, Sundaram PS. ^{99m}Tc dtpa renogram identifies bochdalek hernia with an intra thoracic kidney as its content. *World J Nucl Med* 2014;13:193-6.

Source of Support: Nil, **Conflict of Interest:** None declared.