

Case report

Gallium-68 DOTA-TATE Positron Emission Tomography/Computed Tomography: Scintigraphic Changes of Adrenal Glands Following Management of Ectopic Cushing's Syndrome by Steroidogenesis Inhibitors

Yu-Ting Huang¹, Shaikh Irfan Aziz^{1,2}, Aravind S. Ravi Kumar^{1,2,3}

¹Specialised PET Services, ²Department of Nuclear Medicine, Royal Brisbane and Women's Hospital, Brisbane, ³School of Medicine, University of Queensland, St. Lucia, Queensland, Australia

Abstract

In the era of emerging functional imaging techniques, an understanding of the effects of hormonal therapies on the scintigraphic appearance of endocrine organs is desirable to minimize the erroneous scan interpretation. The mechanisms by which changes in the scintigraphic appearance of endocrine organs occur however sometimes remain ambiguous. This case demonstrates the gallium-68 (Ga-68) DOTA-TATE positron emission tomography/computed tomography (CT) appearance of adrenal glands following management with steroidogenesis inhibitors. The potential mechanisms underlying this change are discussed. A 17-year-old boy with adrenocorticotrophic hormone (ACTH) dependent Cushing's syndrome secondary to ectopic ACTH secretion underwent pre- and post-metyrapone and dexamethasone treatment Ga-68 DOTA-TATE scans 4 months apart. Pretreatment, both adrenals demonstrated normal symmetrical prominent Ga-68 DOTA-TATE uptake and normal CT appearance. The posttherapy scan revealed marked symmetrical suppression of Ga-68 DOTA-TATE uptake, but with bilateral adrenal hypertrophy on CT.

Keywords: Adrenal suppression, cushing's syndrome, gallium-68 DOTA-TATE positron emission tomography/computed tomography, metyrapone, steroidogenesis inhibitor

Introduction

Chronic exposure to excess glucocorticoid results in Cushing's syndrome.^[1,2] Cushing's syndrome in children and adolescents is uncommon.^[1,2] Most commonly, Cushing's syndrome is iatrogenic.^[3] "Spontaneous" Cushing's syndrome is either adrenocorticotrophic hormone (ACTH) dependent or ACTH independent.^[2] Cushing's disease due to pituitary ACTH hypersecretion

is the most frequent type of Cushing's syndrome and is responsible for about 70% of reported cases.^[1-3]

Ectopic adrenocorticotrophic hormone syndrome (EAS) is one of the ACTH dependent causes of Cushing's syndrome, accounting for 10-15% of reported cases.^[1,2] EAS is extremely rare in children and adolescents, they commonly present with weight gain and growth retardation.^[1]

Case Report

A 17-year-old boy with rapid onset of features suggestive of hypercortisolism presented for a gallium-68 (Ga-68) DOTA-TATE positron emission tomography/computed tomography (PET/CT) scan. He had striae, moon face, bruising, central obesity, proximal muscle weakness

Access this article online

Quick Response Code:



Website:
www.wjnm.org

DOI:
10.4103/1450-1147.144823

Address for correspondence:

Dr. Aravind S. Ravi Kumar, Department of Nuclear Medicine, Royal Brisbane and Women's Hospital, Level 3, Ned Hanlon Building, Herston, QLD 4029, Australia. E-mail: aravind.ravikumar@health.qld.gov.au

and hypertension. Biochemically, his 24 h urinary free cortisol levels were seven to eight times the upper limit of normal, with elevated serum cortisol, ACTH and hypokalemia. High dose dexamethasone suppression test failed to suppress cortisol, which suggests an ectopic source of ACTH production [Table 1]. The pituitary gland was also normal on magnetic resonance imaging (MRI). Bilateral inferior petrosal sinus sampling results were again consistent with an ectopic source of excess ACTH production [Table 1].

Gallium-68 DOTA-TATE PET/CT scan was undertaken to identify the ectopic source, but did not identify one. It demonstrated typical somatostatin receptor subtype-two (SSR2) rich adrenal glands with prominent Ga-68 DOTA-TATE activity, which is a normal scan appearance^[4,5] [Figure 1]. The patient's hypercortisolemia was treated medically with "block and replace" strategy with steroidogenesis inhibitor, metyrapone (block), and dexamethasone (replace). An escalated dose of oral metyrapone from 250 to 750 mg 3 times a day was administered.

Four months postcommencement of metyrapone and dexamethasone, biochemistry profile revealed normal serum cortisol, 24-h urinary free cortisol and a suppressed ACTH [Table 1] A follow-up Ga-68 DOTA-TATE PET/CT scan showed marked abnormal reduction in Ga-68 DOTA-TATE avidity [Figure 1] and hypertrophy of bilateral adrenal glands [Figure 2].

Discussion

Bilateral inferior petrosal sinus sampling is the gold standard to differentiate between EAS and Cushing's disease in children and adolescents.^[1,2] Clinically, symptoms of muscle weakness, hypokalemia and

hypertension are relatively more frequent in patients with EAS as demonstrated in our patient.^[1] Weight gain and growth retardation in adolescent patients are equally common with EAS and Cushing's disease.^[1] Investigation results for our case were consistent with EAS, and Ga-68 DOTA-TATE PET/CT scans were undertaken to localize the ectopic source and disease monitoring.

Localization of ectopic ACTH secreting tumors is challenging.^[1,2] CT and MRI of the neck, chest, and abdomen is usually the first line approach.^[1] Functional nuclear medicine imaging, such as PET, have an emerging role in assisting in tumor localization.^[1,5] Ga-68 DOTA-TATE is a somatostatin analog with high affinity for SSR2, which enables its use in detection of ACTH positive neuroendocrine tumors.^[4,5] Normal physiological Ga-68 DOTA-TATE uptake has been demonstrated in organs expressing SSR2 such as the adrenal glands.^[4]

Treatment of hypercortisolism with medical therapy is often attempted prior to surgery due to severity of the hormonal effects.^[1] Metyrapone is an adrenal enzyme (11-beta-hydroxylase) inhibitor that blocks the final step of cortisol synthesis^[6,7] [Figure 3]. To the best of our knowledge, metyrapone is not known to have any direct effects on somatostatin receptors.

The mechanism by which metyrapone and dexamethasone might have resulted in the change in scintigraphic appearance of the adrenal glands has not been previously

Table 1: Biochemical profile

	Pre-treatment	Post-treatment
Serum ACTH (normal <50 ng/L)	>130	<10
Serum cortisol (paediatric normal range 200-700 nmol/L)	1120	151
24-h urinary free cortisol (normal <290 nmol/24-h)	2340	30
High dose dexamethasone suppression test	<50% reduction	Not applicable
Bilateral inferior petrosal sinus sampling	<1.8	Not applicable

ACTH: Adrenocorticotrophic hormone

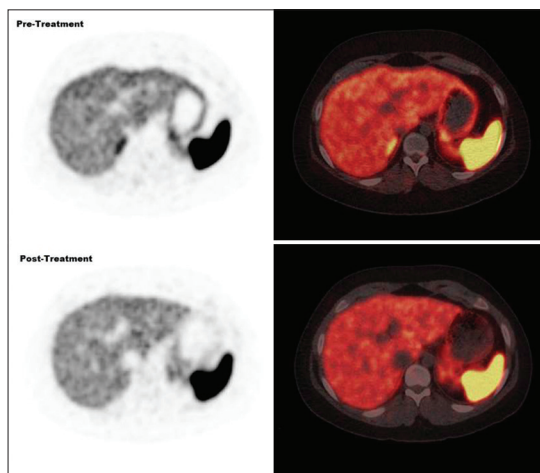


Figure 1: Gallium-68 DOTA-TATE positron emission tomography/computed tomography scans pre- and post-metyrapone treatment showing marked adrenal suppression posttreatment

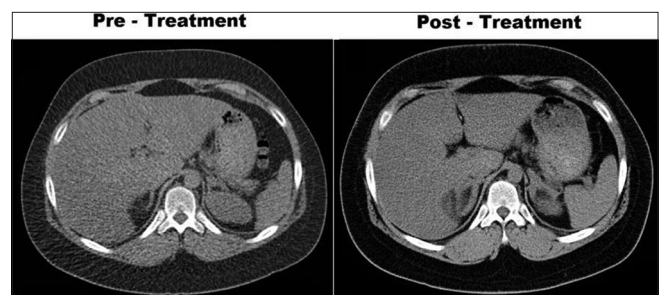


Figure 2: Pre- and post-treatment axial CT showing enlarging adrenal glands post treatment

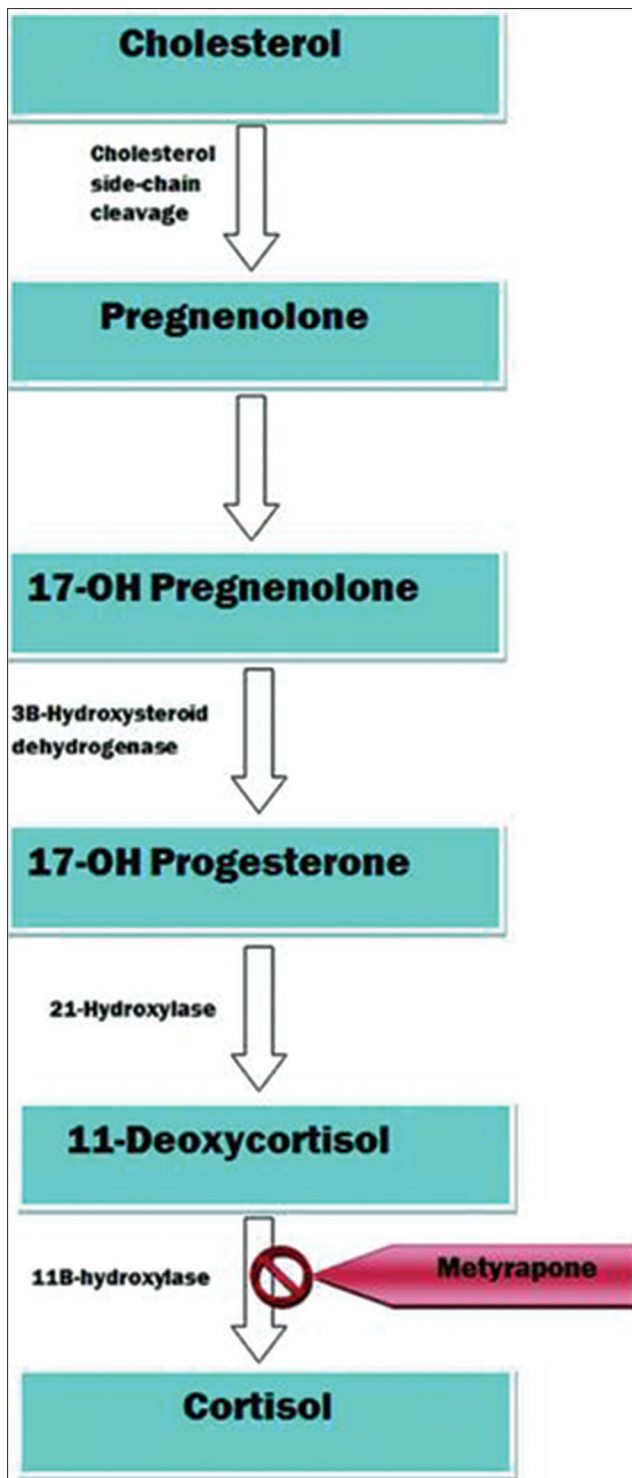


Figure 3: Action of metyrapone therapy on the steroidogenesis pathway

described and merits further discussion. The actions of somatostatin (and therefore receptor expression) at the adrenal gland level is not well-characterized.^[8] Decreased uptake of Ga-68 DOTA-TATE was observed in our patient indicating down regulation of SSR2 receptors in adrenal gland. Metyrapone blocks steroidogenesis, direct effect of metyrapone on SSR2 receptor down-regulation

could be postulated. A more favorable explanation is SSR2 receptor down regulation secondary to overall better disease control.

Following treatment, our patient was noted to have an expected normal level of plasma cortisol and 24-h urinary free cortisol; however, his plasma ACTH levels were also suppressed. To explain this, research has demonstrated dual effects of metyrapone on plasma ACTH, including a suppressive effect on plasma ACTH, the mechanism of which is not known and a stimulatory effect on plasma ACTH via well-known “feed-back” mechanism.^[7] However, if this is true for a patient with EAS is debatable and open for future research.

One might argue that ectopic plasma ACTH was suppressed in our patient due to the use of dexamethasone. However, dexamethasone provides negative feedback to the pituitary gland to suppress the secretion of ACTH, but does not cause ACTH suppression from an ectopic source, which is the basis of high-dose dexamethasone suppression test.

Finally, animal models have concluded metyrapone-activated adrenal cortical hypertrophy is secondary to an increase in circulating ACTH as a result of decrease in negative feedback at the pituitary.^[9,10] The mechanism underlying posttherapy adrenal hypertrophy in the absence of ACTH elevation in our patient is open for discussion.

References

1. More J, Young J, Reznik Y, Raverot G, Borson-Chazot F, Rohmer V, et al. Ectopic ACTH syndrome in children and adolescents. *J Clin Endocrinol Metab* 2011;96:1213-22.
2. Savage MO, Chan LF, Grossman AB, Storr HL. Work-up and management of paediatric Cushing's syndrome. *Curr Opin Endocrinol Diabetes Obes* 2008;15:346-51.
3. Carroll T, Aron DC, Findling JW, Tyrrell JB. Glucocorticoids and adrenal androgens. In: Gardner DG, Shoback D, editors. *Greenspan's Basic and Clinical Endocrinology*. 8th ed. San Francisco: McGraw-Hill; 2007. p. 378.
4. Shastry M, Kayani I, Wild D, Caplin M, Visvikis D, Gacinovic S, et al. Distribution pattern of 68Ga-DOTATATE in disease-free patients. *Nucl Med Commun* 2010;31:1025-32.
5. Willhauck MJ, Pöpperl G, Rachinger W, Giese A, Auernhammer CJ, Spitzweg C. An unusual case of ectopic ACTH syndrome. *Exp Clin Endocrinol Diabetes* 2012;120:63-7.
6. Sharma ST, Nieman LK. Prolonged remission after long-term treatment with steroidogenesis inhibitors in Cushing's syndrome caused by ectopic ACTH secretion. *Eur J Endocrinol* 2012;166:531-6.
7. Schöneshöfer M, Fenner A, Claus M. Suppressive effect of metyrapone on plasma corticotrophin immunoreactivity in normal man. *Clin Endocrinol (Oxf)* 1983;18:363-70.
8. Moreno-Herrera A, Cordoba-Chacon J, Gahete M, Pozo-Salas A, de Lecea L, Kineman R, et al. Role of endogenous somatostatin and cortistatin in regulating adrenal gland function. *Endocr Abstr* 2012;29:15. Presented at 1st International and 1st European

Congress of Endocrinology 2012, Florence, Italy. Available from: <http://www.endocrine-abstracts.org/ea/0029/ea0029p15.htm>. [Last accessed on 2012 Oct 10].

9. Coulter CL, Goldsmith PC, Mesiano S, Voytek CC, Martin MC, Han VK, *et al.* Functional maturation of the primate fetal adrenal *in vivo*: I. Role of insulin-like growth factors (IGFs), IGF-I receptor, and IGF binding proteins in growth regulation. *Endocrinology* 1996;137:4487-98.
10. Warnes KE, McMillen IC, Robinson JS, Coulter CL. Metyrapone

infusion stimulates adrenal growth without activating the cell cycle or the IGF system in the late gestation fetal sheep. *Endocr Res* 2004;30:535-9.

How to cite this article: Huang YT, Aziz SI, Ravi Kumar AS. Gallium-68 DOTA-Tate positron emission tomography/computed tomography: Scintigraphic changes of adrenal glands following management of ectopic cushing's syndrome by steroidogenesis inhibitors. *World J Nucl Med* 2014;13:201-4.

Source of Support: Nil. **Conflict of Interest:** None declared.