

## Case report

# Occult Prostate Cancer Detected with 18F-Fluorocholine Positron Emission Tomography/Computed Tomography

Wanying Xie, Andrew Eik Hock Tan<sup>1</sup>, Christopher Cheng<sup>2</sup>, Anthony Goh Soon Whatt

Department of Nuclear Medicine and PET, <sup>2</sup>Department of Urology and <sup>3</sup>Pathology, Singapore General Hospital, Singapore 169608, <sup>1</sup>Department of Diagnostic Radiology, Raffles Hospital, Singapore S188770, Singapore

## Abstract

We present a case of a 63-year-old gentleman, who had an initial negative prostate needle biopsy, but persistently elevated prostate-specific antigen levels. An magnetic resonance imaging study of the prostate failed to demonstrate the presence of malignancy. 18F-fluorocholine positron emission tomography/computed tomography (PET/CT) was then acquired which revealed suspicious prostate lesions. These were confirmed by subsequent surgery and histology to represent prostatic carcinoma.

**Keywords:** Fluorocholine positron emission tomography/computed tomography, prostate cancer, transrectal ultrasound

## Introduction

Prostate needle biopsy under transrectal ultrasound (TRUS) guidance is performed in patients with suspected prostate cancer. However the incidence of false negative cancer detection rates are high and reported to exceed 20%.<sup>[1]</sup> Noninvasive detection of prostate cancer remains a diagnostic challenge, as current imaging modalities are unable to localize malignant changes even in the presence of elevated prostate-specific antigen (PSA) levels which may portend early prostate cancer. This can also be extrapolated in sampling of the prostate, which focuses on systematic sextant, rather than targeted biopsies, with a rather dismal sensitivity of 50–60%.<sup>[2]</sup> This case highlights the benefit of metabolic information obtained from fluorocholine (FCH) positron emission tomography/computed tomography (PET/CT), which shows promise in identifying prostate lesions which are radiographically occult by conventional anatomic imaging.

## Case Report

A 63-year-old Chinese gentleman was discovered on screening to have a mildly elevated PSA level of 6.6 ng/ml. Digital rectal examination (DRE) revealed a normal sized prostate, estimated at 15–20 g. A transrectal ultrasound (TRUS) guided sextant prostatic needle biopsy yielded benign histology.

Subsequent serial PSA levels continued to uptrend, but the patient was reluctant to repeat prostate biopsies, choosing instead to monitor his PSA levels. Four years after his initial biopsy result, the DRE revealed a slightly larger prostate, estimated at 20–25 g. His PSA level was by then 11.9 ng/ml.

The patient was again offered repeat prostate needle biopsy, but declined, citing reasons of discomfort and pain experienced during the first biopsy. However he was agreeable to non-invasive imaging. An magnetic resonance imaging (MRI) study of the prostate was performed and showed no discernible focus of abnormal signal intensity to indicate the presence of tumor [Figure 1]. As the clinical suspicion for malignancy was high, an FCH PET/CT was then acquired.

Positron emission tomography/CT scan was performed using a combined PET and CT system (Discovery 690; GE

### Access this article online

#### Quick Response Code:



Website:  
www.wjnm.org

DOI:  
10.4103/1450-1147.144824

#### Address for correspondence:

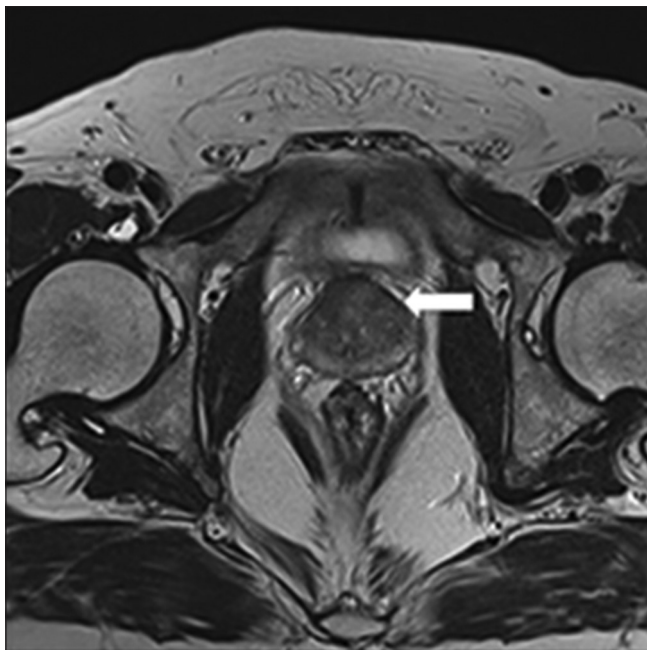
Dr. Wanying Xie, Department of Nuclear Medicine and PET, Singapore General Hospital, Outram Road, Singapore 169608.  
E-mail: fairywren@gmail.com

Healthcare). 3.9 MBq/kg of 18F FCH was administered to the patient after a 6 h fast. Imaging with a dual time point protocol was performed, with an initial 2 min local view of the pelvis and a delayed scan at 10 min, from the head to the upper thighs.

Computed tomography data were used for attenuation correction and anatomical localization. A standardized uptake value (SUV), defined as the measured voxel activity divided by the injected radioactivity normalized to body weight, was used to quantify uptake.

Abnormal focal tracer uptake was present in the left lateral and the left anterolateral regions at the base of the prostate gland. Lesional regions of interest were drawn on the PET image with an SUVmax of 7.9 g/ml. There were no extracapsular sites of increased focal tracer avidity. No tracer avid nodal or extra-prostatic disease was detected [Figure 2].

Given the highly suspicious results of the FCH-PET scan on the background of progressively rising PSA levels, the patient was offered the choice of repeated TRUS biopsy or definitive surgery. He chose the latter and therefore no further biopsies were performed. The patient consented for surgery and underwent a laparoscopic assisted radical prostatectomy. Histology confirmed the presence of adenocarcinoma confined to the prostate gland at the left base (Gleason score 3 + 3), corresponding to the foci of FCH avidity. The dissected obturator nodes bilaterally were negative for malignancy.



**Figure 1:** Magnetic resonance imaging T2-weighted axial image of the prostate, showing normal prostate anatomy. No abnormal focus of signal intensity is detected to suggest the presence of tumor

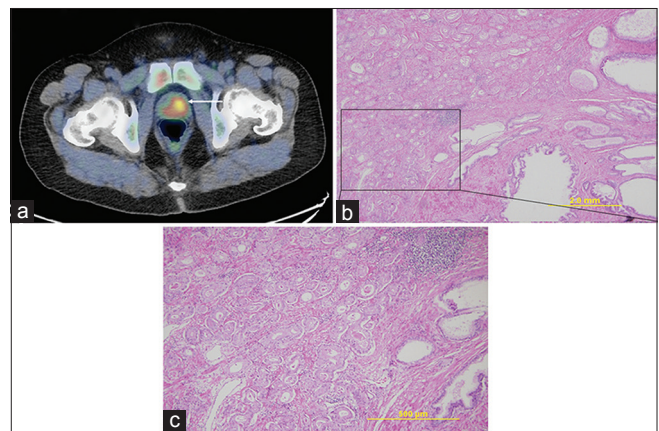
The PSA levels of the patient remained within normal limits at 6 months follow-up postsurgery.

## Discussion

Current imaging modalities are unable to satisfactorily detect localized prostate malignancy. Furthermore, the commonly employed sextant biopsy only samples part of a prostate segment and can miss early prostate cancer as a result of sampling errors, contributing to the high false negative rates of prostate needle biopsies. With PSA based screening and earlier cancer detection of smaller volume disease, it is imperative to reduce the false negative rates of TRUS. This may be achieved by targeted biopsy, which in turn, relies on improved imaged guided localization of malignancy.

Promising results with high diagnostic specificity have been reported with the use of biopsies guided by FCH PET images fused with MRI compared to MRI alone.<sup>[3]</sup> Although in our case report, image guided prostate biopsy was not performed at the patient's request, the final histology correlated well with the sites of prostatic malignancy demonstrated in the FCH PET/CT scan.

In cases where there are elevated PSA levels despite an initial negative prostate biopsy, conventional MRI T2-weighted imaging (T2-W) has been used with limited success to detect and re-biopsy suspected lesions. T2-W imaging is beset by high false positive rates and limited specificity, the most common contributory factors including prostatitis, benign prostatic hyperplasia and post treatment changes.<sup>[4]</sup> Tumor detection in the central gland of the prostate is also poor due to poor tumor-stromal contrast in this region.



**Figure 2:** (a) Fused fluorocholine positron emission tomography/computed tomography axial image of the prostate show focal FCH uptake at the left anterolateral aspect of the prostate, denoting the presence of tumor. Hematoxylin and eosin stain of the prostate at (b) low (x4) magnification and at (c) higher (x10) magnification reveal closely packed infiltrative glandular carcinoma, with cells showing prominent nucleoli

Alternative metabolic imaging modalities were thus explored, more extensively in the last decade. Conventionally, 18F-FDG has been used for metabolic imaging of cancer. However, many studies have demonstrated limited utility of FDG PET/CT for staging of prostate cancer, due to low sensitivity and specificity.<sup>[5-7]</sup> This has prompted the search for more accurate oncologic PET tracers.

Of these, 18F-FCH has showed promising results, as it has high avidity for prostate cancer.<sup>[8,9]</sup> Choline is phosphorylated by choline kinase to form phosphatidylcholine, which is essential for cell membrane synthesis. By the same pathway, FCH also forms a substrate for choline kinase and is phosphorylated to 18F-phosphorylfluorocholine. FCH targets the choline metabolic pathway and elevated choline metabolites has been well documented in prostate malignancies.<sup>[10-12]</sup>

In a study of 26 patients, stable or increasing accumulation of 18F-FCH in malignant prostatic tissue was observed.<sup>[13]</sup> Furthermore, Kwee *et al.* were able to find a direct correlation between tumor uptake and tumor diameter in malignant sextants.<sup>[14]</sup> The use of FCH PET/CT to guide prostate biopsy has demonstrated promising results in another study, with a detection rate of 25% in patients who had biochemical relapse, but had multiple previously negative biopsies.<sup>[15]</sup>

Changes in metabolic status of the prostate malignant cells may precede discernible anatomical differences by conventional imaging. Our initial experience with FCH PET/CT has been promising, as demonstrated in this case which revealed focal malignant changes which were otherwise undetected on MRI study. We observed focal FCH uptake by areas of tumor, which is consistent with the hypothesis of increased choline utilization in prostate tumors secondary to increased cell proliferation.

In the near future, fusion FCH PET/MRI could permit precise localization of malignant cells in early prostate cancer. MRI offers improved spatial resolution and excellent soft tissue anatomical contrast, allowing more accurate localization of hypermetabolic areas demonstrated by FCH PET. As PET/MRI imaging is still largely under research, further studies are required to establish its role for tumor diagnosis.

## Conclusion

This case illustrates that FCH PET imaging can be a valuable tool in revealing malignant sites in patients with high clinical suspicion of prostatic malignancy, where other imaging or even biopsy findings are negative.

## Acknowledgments

No external source of funding was obtained for the case report. The authors would like to thank Dr. Kesavan from the Department of Pathology, Singapore General Hospital for his kind contribution of pictures used in Figures 2a and 2b.

## References

- Rabbani F, Stroumbakis N, Kava BR, Cookson MS, Fair WR. Incidence and clinical significance of false-negative sextant prostate biopsies. *J Urol* 1998;159:1247-50.
- Wefer AE, Hricak H, Vigneron DB, Coakley FV, Lu Y, Wefer J, *et al.* Sextant localization of prostate cancer: Comparison of sextant biopsy, magnetic resonance imaging and magnetic resonance spectroscopic imaging with step section histology. *J Urol* 2000;164:400-4.
- Yamaguchi T, Lee J, Uemura H, Sasaki T, Takahashi N, Oka T, *et al.* Prostate cancer: A comparative study of 11C-choline PET and MR imaging combined with proton MR spectroscopy. *Eur J Nucl Med Mol Imaging* 2005;32:742-8.
- Mazaheri Y, Shukla-Dave A, Muellner A, Hricak H. MR imaging of the prostate in clinical practice. *MAGMA* 2008;21:379-92.
- Effert PJ, Bares R, Handt S, Wolff JM, Büll U, Jakse G. Metabolic imaging of untreated prostate cancer by positron emission tomography with 18fluorine-labeled deoxyglucose. *J Urol* 1996;155:994-8.
- Hofer C, Laubenbacher C, Block T, Breul J, Hartung R, Schwaiger M. Fluorine-18-fluorodeoxyglucose positron emission tomography is useless for the detection of local recurrence after radical prostatectomy. *Eur Urol* 1999;36:31-5.
- Liu IJ, Zafar MB, Lai YH, Segall GM, Terris MK. Fluorodeoxyglucose positron emission tomography studies in diagnosis and staging of clinically organ-confined prostate cancer. *Urology* 2001;57:108-11.
- Price DT, Coleman RE, Liao RP, Robertson CN, Polascik TJ, DeGrado TR. Comparison of [18 F] fluorocholine and [18 F] fluorodeoxyglucose for positron emission tomography of androgen dependent and androgen independent prostate cancer. *J Urol* 2002;168:273-80.
- DeGrado TR, Baldwin SW, Wang S, Orr MD, Liao RP, Friedman HS, *et al.* Synthesis and evaluation of (18) F-labeled choline analogs as oncologic PET tracers. *J Nucl Med* 2001;42:1805-14.
- Cornel EB, Smits GA, Oosterhof GO, Karthaus HF, Deburynne FM, Schalken JA, *et al.* Characterization of human prostate cancer, benign prostatic hyperplasia and normal prostate by *in vitro* 1H and 31P magnetic resonance spectroscopy. *J Urol* 1993;150:2019-24.
- Negendank W. Studies of human tumors by MRS: A review. *NMR Biomed* 1992;5:303-24.
- Nakagami K, Uchida T, Ohwada S, Koibuchi Y, Suda Y, Sekine T, *et al.* Increased choline kinase activity and elevated phosphocholine levels in human colon cancer. *Jpn J Cancer Res* 1999;90:419-24.
- Kwee SA, Wei H, Sesterhenn I, Yun D, Coel MN. Localization of primary prostate cancer with dual-phase 18F-fluorocholine PET. *J Nucl Med* 2006;47:262-9.
- Kwee SA, Thibault GP, Stack RS, Coel MN, Furusato B, Sesterhenn IA. Use of step-section histopathology to evaluate 18F-fluorocholine PET sextant localization of prostate cancer. *Mol Imaging* 2008;7:12-20.
- Igerc I, Kohlfürst S, Gallowitsch HJ, Matschnig S, Kresnik E,

Gomez-Segovia I, *et al.* The value of 18F-choline PET/CT in patients with elevated PSA-level and negative prostate needle biopsy for localisation of prostate cancer. *Eur J Nucl Med Mol Imaging* 2008;35:976-83.

**How to cite this article:** Xie W, Tan AH, Cheng C, Whatt AS. Occult prostate cancer detected with 18F-fluorocholine positron emission tomography/computed tomography. *World J Nucl Med* 2014;13:205-8.

**Source of Support:** Nil. **Conflict of Interest:** None declared.