

## Case report

# Systemic Radiopharmaceutical Agents (Sm-153) may be Dangerous in Hepatocellular Carcinoma

Onur Keskin, Cigdem Soydal<sup>1</sup>, Xheni Deda, Bengu Manti, Ali Tuzun

Departments of Gastroenterology and <sup>1</sup>Nuclear Medicine, School of Medicine, Ankara University, Ankara, Turkey

## Abstract

Palliation of bone metastases in hepatocellular carcinoma (HCC) is sometimes difficult. Systemic pharmaceuticals have been successfully used for the palliation of bone metastasis for many years. Safety of these agents in HCC is not known completely. We presented a male patient with decompensated liver cirrhosis with HCC. Multifocal bone metastases developed in this patient and he had refractory bone pain. We treated this patient with Sm-153 (samarium) after obtaining patient's consent. Two days after treatment, he experienced dyspnea and we detected a massive hemorrhagic pericardial effusion. He died due to this unexpected bleeding. We should use this radiopharmaceutical treatment cautiously in these cytopenic cirrhotic patients.

**Keywords:** Bone metastasis, hepatocellular carcinoma, Sm-153

## Introduction

Hepatocellular carcinoma (HCC) is one of the most common malignancies in the world. The incidence of bone metastasis in HCC is increasing over time. Bone metastasis was found in 13% of the HCC patients in a Japan study.<sup>[1]</sup> Bone metastasis may cause pain and functional loss in this patient group. Pain palliation is unsuccessful in at least 45% of patients with bone metastasis.<sup>[2]</sup> Systemic radiopharmaceuticals may be used in the palliation of pain due to multifocal osteoblastic metastasis. One of these radiopharmaceuticals is samarium Sm-153 Lexidronam (Sm-153). Sm-153 is produced by neutron irradiation of Sm-152 oxide and makes a complex with ethylenediaminetetramethylenephosphonic acid (EDTMP) to form Sm-153-EDTMP. In this form, samarium selectively accumulates within metastatic bone tissue.<sup>[3]</sup> Mild hematological side-effects (mild myelosuppression) have been reported with this agent. In this report, we share our experience in use of Sm-153

EDTMP in a patient with hepatitis B virus (HBV) related decompensated liver cirrhosis.

## Case Report

The case we present here is about a 49-year-old male patient who had a history of HBV related chronic liver failure and HCC for 2 years developed multiple osteoblastic bone metastasis [Figure 1] and bone pain was refractory to analgesic treatments (tramadol, fentanyl). SM-153 treatment was planned for palliation of bone pain. He was mildly decompensated in terms of liver disease, and there was no significant finding except minimal pleural effusion and a chronic infiltrative area at chest X-ray graphic examination taken before the procedure [Figure 2a]. Laboratory findings of patient at the day of treatment were Hb: 9.3 g/dl, Plt: 66.000 and white blood cell (WBC): 3400; creatinine 0.6 mg/dl, glomerular filtration rate (GFR): Normal and total bilirubin: 5.09 mg/dl. Sm-153 intravenous (IV) bolus (1 mCi/kg) and 100 cc %0.9 NaCl 1 h IV infusion was applied for pain palliation. Sm-153 accumulation at bone metastatic sites was shown by total body scintigraphic imaging at 24<sup>th</sup> h. Patient had dyspnea and the cardiac shadow was more prominent at chest X-ray taken 2 days after the SM-153 treatment [Figure 2b]. Massive pericardial effusion was determined at echocardiography. Bilateral pleural effusion, massive

### Access this article online

#### Quick Response Code:

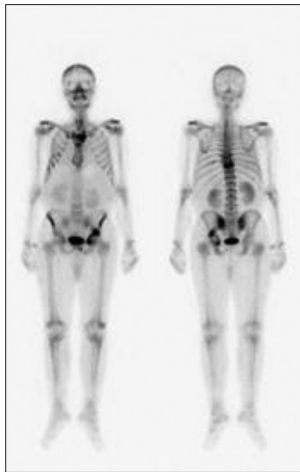

Website:  
www.wjnm.org

DOI:  
10.4103/1450-1147.150548

#### Address for correspondence:

Dr. Onur Keskin, Department of Gastroenterology, School of Medicine, Ankara University, Ibni Sina Hospital, Ankara, Turkey.  
E-mail: onurkeskin81@gmail.com

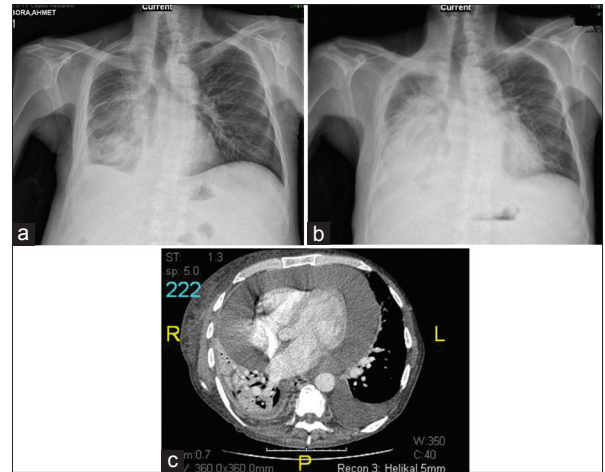


**Figure 1:** Scintigraphic examination of patient

pericardial effusion and subtotal collapse of right lung were noticed at thorax CT [Figure 2c]. Pericardiectomy was performed, and the effusion was hemorrhagic. No malignant cell was determined at cytologic examination, and there was no proliferation in culture of pericardial fluid. Approximately, 500 cc/day pericardial hemorrhagic fluid was drained. The bilirubin level increased up to 30 mg/dl and the patient died 20 days after the application of Sm-153.

## Discussion

Radiopharmaceutical drugs are important alternatives in pain palliation of osteoblastic bone metastases. Although there is no certain approach in this issue, most centers prefer the minimal standards of Hb > 9 g/dl, WBC > 3500, neutrophil > 1500, Plt > 100,000, GFR > 50 ml/min. The effectiveness and reliability of Samarium have been studied mostly in prostate and breast cancers until now.<sup>[4]</sup> However, there is no sufficient data about the use of radiopharmaceutical drugs in HCC. Because HCC mostly originates from underlying cirrhosis and most of the cirrhotic patients are pancytopenic due to hypersplenism, all types of systemic treatment have to be



**Figure 2:** Chest X-ray graph of patient before procedure (a), and after procedure (b), thorax computed tomography examination after Sm-153 treatment (c)

used very carefully. Our patient had critical liver disease and died due to a rapid fulminant progression with pericardial effusion due to an unexpected hemorrhage. Systemic radiopharmaceutical drugs should be used cautiously in these patients.

## References

1. Fukutomi M, Yokota M, Chuman H, Harada H, Zaitzu Y, Funakoshi A, *et al.* Increased incidence of bone metastases in hepatocellular carcinoma. *Eur J Gastroenterol Hepatol* 2001;13:1083-8.
2. Serafini AN. Therapy of metastatic bone pain. *J Nucl Med* 2001;42:895-906.
3. Paes FM, Ernani V, Hosein P, Serafini AN. Radiopharmaceuticals: When and how to use them to treat metastatic bone pain. *J Support Oncol* 2011;9:197-205.
4. Fischer M, Kampen WU. Radionuclide Therapy of Bone Metastases. *Breast Care (Basel)* 2012;7:100-07.4.

**How to cite this article:** Keskin O, Soydal C, Deda X, Manti B, Tuzun A. Systemic Radiopharmaceutical Agents (Sm-153) may be Dangerous in Hepatocellular Carcinoma. *World J Nucl Med* 2015;14:51-2.

**Source of Support:** Nil, **Conflict of Interest:** None declared