Article published online: 2022-05-21

Original article

Value of Oblique View in Nodular Thyroid Disease; Revisiting Fundamentals

Abdelhamid H. Elgazzar, Saud Alenezi, Jehan M. Alshammari, Mohammad Ghanem, Saqr Asa'ad

Department of Nuclear Medicine, Kuwait University, Kuwait

Abstract

Thyroid scintigraphy plays an important role in the anatomical and functional evaluation of thyroid nodules which carry the risk of malignancy. The presence of multiple nodules carries overall smaller risk of cancer than solitary nodule. Missing nodules, whether solitary or multiple, may mean delaying detection of possible cancer. Therefore, it is important to improve the delectability of thyroid scintigraphy using most optimal imaging techniques. For pinhole thyroid imaging, there is a recent trend to omit oblique projections by some laboratories. The objective of this study was to reevaluate the impact of oblique projections in the detection of thyroid nodules. A total of 92 cases with nodular thyroid disease on routine pinhole thyroid scintigraphy was reviewed retrospectively. Two nuclear medicine physicians recorded the number of nodules based on the anterior view only and another time with adding the oblique views. A total of 192 nodules was detected using the three views. Sixty nodules (31%) were only seen on the oblique views and were missed on the anterior projections. Oblique pinhole projections are mandatory for adequate thyroid scintigraphy since 31% of nodules are missed if only anterior projection was used for interpretation. Following proper techniques will avoid missing of detection of nodule that may harbor cancer.

Keywords: Radionuclide, oblique views, pinhole, thyroid nodules, thyroid scintigraphy

Introduction

Thyroid scintigraphy is one of the common nuclear medicine procedures that continue to play an important role in the functional and anatomical evaluation of the thyroid gland. There are several clinical indications for thyroid scintigraphy in clinical practice of which characterization of thyroid nodules in suspected nodular thyroid disease is a major one.

Evaluation of thyroid nodules is very important given the potential risk of malignancy. Clinically, impalpable thyroid nodules are common. In one study, 13% of nodules were nonpalpable and discovered only on ultrasonography with a malignancy rate of 28.8% among these nodules.[1] Histopathological evaluation of these nodules with ultrasound-guided fine-needle aspiration cytology (FNAC) usually gives an adequate answer of the nature of these nodules. However, this procedure cannot be used for screening as it is invasive and carries the risk for infection and bleeding.[2] Therefore, a simple noninvasive modality would be of value for the initial evaluation of these nodules.

Access this article online

Quick Response Code:

Website: www.wjnm.org

DOI: 10.4103/1450-1147.153911

Thyroid scintigraphy is a simple noninvasive modality that is very useful in the anatomical and functional characterization of these nodules and, therefore, directing the next steps in their clinical management. It provides information on the functional status of these nodules and accordingly divides them into hot or cold nodules. Hot nodules carry very low risk of malignancy (<1%) and therefore may not require further evaluation. Cold nodules carry a relatively higher risk of cancer (around 5% overall) and require further evaluation with FNAC.[3] Thyroid scintigraphy can also provide anatomical information about the size and number of nodules. It has been a consistent observation in the reported literature that the risk of thyroid cancer is less with in patients with multiple nodules than with solitary or with a dominant nodule in patients with multinodular goiter.[4,5]

Address for correspondence:
Prof. Abdelhamid H. Elgazzar, Department of Nuclear Medicine, Kuwait University, Kuwait. E-mail: aelgazzar49@hotmail.com

Thyroid imaging is ideally performed using a gamma camera equipped with a pinhole collimator because of its ability to magnify the image and yet with improved system resolution. However, with the improvement of gamma cameras over the years and availability of high and ultra-high resolution collimators, there has been a gradually increasing trend to replace pinhole with the use of high-resolution parallel hole collimator with zoom in thyroid imaging.[6] Our group compared the parallel hole collimator to pinhole collimator imaging for thyroid gland in patients with suspected nodular disease and found that up to 75% of nodules could be missed if parallel hole is used compared to pinhole collimator.[7]

With pinhole imaging, multiple views are usually acquired including anterior, left anterior oblique (LAO), and right anterior oblique (RAO) in addition to marker views for nodules as required and a standard one with a marker at the suprasternal notch to evaluate retrosternal extension. However, another trend noted in some departments, especially the ones with busy schedule, is to restrict imaging to anterior views only[8] omitting both anterior oblique views.

This study was designed to assess the added value of oblique views with a pinhole collimator in detecting thyroid nodules.

Materials and Methods

A total of 92 patients, 58 females and 34 males, who were referred routinely for thyroid scintigraphy for the assessment of thyroid nodules and have reported nodules on their studies, were included in this study. Their scans were reviewed retrospectively. Patient age ranged from 15 to 65 years.

The images were obtained 15–20 min following the intravenous administration of 185 MBq (5 mCi) of Tc-99m pertechnetate. Multiple images were acquired including anterior, RAO, and LAO views. These images were acquired using a gamma camera equipped with a pinhole collimator with an aperture of 5 mm. All images were acquired with 256 × 256 matrix with 1.6 zoom and variable distance from patient's neck so that the thyroid gland occupies approximately two-third of the field of view. For each image, 100 K counts were acquired with the energy window 20% centered at 140 Kev.

Two nuclear medicine physicians reviewed all the images and counted the number of nodules independently and reached a consensus subsequently. The number of nodules were determined utilizing the anterior view only and another time the number was determined after adding both anterior oblique views. The number of nodules on the anterior images was recorded. As well, the number of nodules that were added on the oblique images was recorded. The difference of the number of nodules between the anterior and oblique images was then determined. The location of nodules that were not seen on the anterior view was also identified and recorded.

Results

A total of 192 nodules was found in all the 92 patients using the three views. Sixty nodules (31%) were only seen on the oblique views and were missed on the anterior views. In 22 patients (24%), the anterior views showed a normal gland while the oblique views detected the presence of nodules [Figure 1]. In seven patients (7.6%), the anterior views showed solitary nodule while the oblique views demonstrated the presence of multiple nodules [Figure 2].

Most of the nodules which were missed on the anterior images are located on the lateral (48%) and posterior (20%) aspects of the gland. Sixteen (26%) of the missed nodules are located at the isthmus.

In addition to detect additional nodules that were missed on the anterior views, both readers agreed that the oblique views added more certainty in identifying to some of the nodules that were seen on the anterior views.

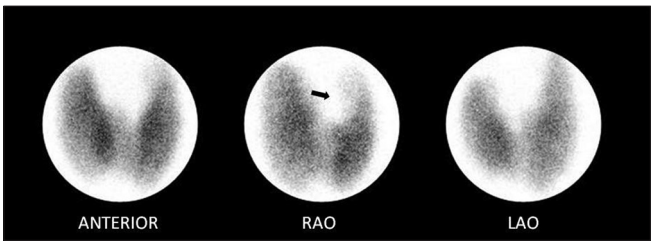

Figure 1: Multiple projections of a Tc-99m pertechnetate thyroid study. The anterior image demonstrates normal gland with no definite nodules. The RAO image demonstrates a cold nodule at the posteromedial aspect of the right upper pole (arrow). RAO: Right anterior oblique

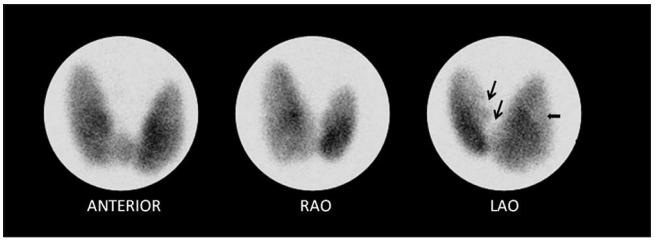

Figure 2: Tc-99m pertechnetate pinhole thyroid study with multiple projections. The anterior image shows no definite evidence of discrete nodules. The LAO demonstrates a large cold nodule at the lateral aspect of the left upper pole (thick arrow). As well, there are two small cold nodules at the posterior aspect of the right lobe (thin arrows). LAO: Left anterior oblique

Discussion

The number of thyroid nodules is an independent predictor of the risk of thyroid malignancy[5] while the size of nodules was not found to be an independent predictor for the risk of malignancy.[9] It is generally accepted that multinodular goiter carries a smaller risk of cancer than a solitary nodule. Therefore, detecting the presence of nodules and their number is an important step in the management of thyroid nodules. Accordingly, thyroid scintigraphy should be obtained using the most optimal scanning techniques to improve the detection of thyroid nodules.

In a previous study, our group compared the use of parallel hole collimator to pinhole collimator in imaging the thyroid gland. It was found that up to 75% of nodules could be missed if parallel hole collimator is used compared to pinhole collimator.[3]

In this study, we found that 31% of the nodules were detected only on the oblique views and were missed on the anterior views. Accordingly, the use of the oblique views changed the final report or diagnosis in these patients. The anterior views demonstrated normal gland in about a quarter of patients while the oblique views detected the presence of nodules. In addition, in 7% of patients, anterior views showed solitary nodule while oblique views changed the impression to multinodular goiter. In both situations, the management of patients can be seriously affected.

Smith and Wraight in 1989 studied 73 scans for euthyroid patients referred with focal or diffuse thyroid disease. Based on the oblique views, it was found that 30% of patients had multiple nodules which were not seen on the anterior views alone.[10] This result is similar to ours in the current study which reports a larger number of patients. In addition, our study was intended to reconfirm the principle of the value of oblique projections after the apparent trend of omitting such important projections by some laboratories in the recent years.

Our study also found that most of the nodules which were missed on the anterior views were located at the lateral and posterior aspects of the gland. This can be explained by the presence of normal functioning thyroid tissue in front or behind the nodule.[7] As well, 26% of the missed nodules are located at the isthmus. This could be attributed to the presence of thin thyroid tissue at this region, making the detection of the nodules often difficult.[7]

In addition to its ability to detect nodules that are missed in the anterior views, oblique views also improve the certainty and confidence in identifying the nodules. It is also helpful in assessing the relative function of thyroid nodule which appears hypofunctional on the anterior views.[11] Therefore, anatomical delineation and functional status assessment of nodules can be improved by obtaining routine oblique projections.

One of the main limitations of this study is the lack of correlation with ultrasonography. Ultrasonography can provide important anatomical details regarding the number and location of nodules. However, the main objective of the study was to compare anterior projection with the three projections in detecting the thyroid nodules.

Conclusion

Oblique views are mandatory for proper interpretation of thyroid scintigraphy. Acquiring only anterior view can lead to missing 31% of nodules. Following proper techniques will avoid missing of detection of nodule that may harbor malignancy.

References

1. Kang HW, No JH, Chung JH, Min YK, Lee MS, Lee MK, *et al*. Prevalence, clinical and ultrasonographic characteristics of thyroid incidentalomas. Thyroid 2004;14:29-33.
2. Polyzos SA, Anastasilakis AD. Clinical complications following thyroid fine-needle biopsy: A systematic review. Clin Endocrinol (Oxf) 2009;71:157-65.
3. Frates MC, Benson CB, Doubilet PM, Kunreuther E, Contreras M, Cibas ES, *et al*. Prevalence and distribution of carcinoma in patients with solitary and multiple thyroid nodules on sonography. J Clin Endocrinol Metab 2006;91:3411-7.
4. Gandolfi PP, Frisina A, Raffa M, Renda F, Rocchetti O, Ruggeri C, *et al*. The incidence of thyroid carcinoma in multinodular goiter: Retrospective analysis. Acta Biomed 2004;75:114-7.
5. Raber W, Kaserer K, Niederle B, Vierhapper H. Risk factors for malignancy of thyroid nodules initially identified as follicular neoplasia by fine-needle aspiration: Results of a prospective study of one hundred twenty patients. Thyroid 2000;10:709-12.
6. Seret A. A comparison of contrast and sensitivity in Tc-99m thyroid scintigraphy between nine nuclear medicine centers of a geographic area. Alasbimn J 2006;32:AJ32-33.
7. Ghanem MA, Elgazzar AH, Elsaid MM, Shehab F. Comparison of pinhole and high-resolution parallel-hole imaging for nodular thyroid disease. Clin Nucl Med 2011;36:770-1.
8. Crawford ES, Guarasci DT, Larson SA. A survey of thyroid gland scintigraphy. J Nucl Med Technol 2009;37:173-8.
9. McHenry CR, Huh ES, Machekano RN. Is nodule size an independent predictor of thyroid malignancy? Surgery 2008;144:1062-8.
10. Smith ML, Wraight EP. Oblique views in thyroid imaging. Clin Radiol 1989;40:505-7.
11. Karelitz JR, Richards JB. Necessity of oblique views in evaluating the functional status of a thyroid nodule. J Nucl Med 1974;15:782-5.

How to cite this article: Elgazzar AH, Alenezi S, Alshammari JM, Ghanem M, Asa'ad S. Value of Oblique View in Nodular Thyroid Disease; Revisiting Fundamentals. World J Nucl Med 2015;14:125-7.

Source of Support: Nil, **Conflict of Interest:** None declared.