

Case report

Retroperitoneal Endometriosis: A Possible Cause of False Positive Finding at ^{18}F -Fluorodeoxyglucose Positron Emission Tomography/Computed Tomography

Anna Margherita Maffione, Riccardo Panzavolta¹, Laura Camilla Lisato², Maria Ballotta², Mariangela Zanforlini D'Isanto¹, Domenico Rubello

Departments of Nuclear Medicine, ¹Radiology and ²Pathology, Santa Maria Della Misericordia Hospital, Rovigo, Italy

Abstract

Endometriosis is a frequent and clinically relevant problem in young women. Laparoscopy is still the gold standard for the diagnosis of endometriosis, but frequently both morphologic and functional imaging techniques are involved in the diagnostic course before achieving a conclusive diagnosis. We present a case of a patient affected by infiltrating retroperitoneal endometriosis falsely interpreted as a malignant mass by contrast-enhanced magnetic resonance imaging and ^{18}F -fluorodeoxyglucose positron emission tomography/computed tomography.

Keywords: Endometriosis, false positive, fluorodeoxyglucose, magnetic resonance imaging, menstrual cycle, positron emission tomography/computed tomography

Introduction

Endometriosis is a common and clinically important problem in women of childbearing age. It is classically defined as the presence of functional endometrial glands and stroma outside the uterine cavity and musculature.^[1] It may vary from microscopic endometrioid implants to large cysts (endometriomas). In general, endometriosis occurs in young women with a mean age of 25-29. Pelvic pain could be cycle-related. Laparoscopy is the gold standard for the diagnosis of endometriosis. Since surgery remains the best therapeutic option for many patients, the accurate preoperative estimation of the extension of endometriotic disease is extremely important.

Case Report

A young woman aged 36-year-old affected by left lumbar and thigh pain underwent both abdominal contrast-enhanced computed tomography (ceCT) and inferior abdominal contrast-enhanced magnetic resonance imaging (ceMRI) during the secretory phase of the menstrual cycle. Contrast-enhanced T1-weighted MRI sequences [Figure 1] showed a retroperitoneal mass infiltrating left psoas and iliac muscles, L5-S1 left conjugation foramen with edema of spongious left sacral wing bone. Significant contrast enhancement of the lesion and trombosis of the left iliac venous axis was also reported.

In order to better characterize the lesion, an ^{18}F -fluorodeoxyglucose (^{18}F -FDG) positron emission tomography/CT (PET/CT) scan was performed (at day 8 of the menstrual cycle, proliferative phase). PET investigation [Figure 2] showed an area of dishomogeneous increased FDG uptake corresponding to the known retroperitoneal lesion leaning to the front edge of the left sacral wing (in the absence of clear signs

Access this article online

Quick Response Code:



Website:
www.wjnm.org

DOI:
10.4103/1450-1147.154230

Address for correspondence:

Dr. Anna Margherita Maffione, Department of Nuclear Medicine, Santa Maria Della Misericordia Hospital, 140, Viale Tre Martiri, 45100 Rovigo, Italy.
E-mail: maffionemarghe@libero.it

of bone infiltration) which, with its more cranial portion appeared to infiltrate the left L5-S1 intervertebral foramen and caudally terminating in the arcuate line of the iliac region (maximum standardized uptake value [SUVmax] 4.8; maximum diameter of the hypermetabolic area: LL = 5.1 cm, CC = 5.4 cm). CT, MRI, and PET/CT findings were described as compatible with malignancy. Later, an ultrasounds-guided fine needle aspiration biopsy of the mass was performed during the secretory phase: The presence of both the endometrial-type epithelium and stroma CD-10 positive, immunoreactive for estrogen, and progesteron receptors, met the criteria for a diagnosis of endometriosis. Figure 3 shows Ki-67 proliferative rate of 6% in the endometrial gland and 10% in the stroma (Ki-67 immunoperoxidase stain, fast red, $\times 200$. Brown granules are hemosiderin). This diagnosis was also confirmed by symptoms: In fact, the patient reported that the pain was dramatically amplified with menstruation. The present case showed relatively high FDG uptake in the proliferative phase and dishomogeneous relatively low Ki-67 staining in the secretory phase: The different cycle phases could explain the absence of correlation between SUV and Ki-67. Moreover, the infiltrating behavior of the mass could explain the increased glycolytic tissue activity. In this case, the cycle-related pain, more than imaging, has contributed to support the pathological findings.

Discussion

The present case shows the false positive reports of ceCT, ceMRI, and ^{18}F -FDG PET/CT. MRI imaging could yield important findings for grading and identifying subperitoneal extension and other associated disease entities, thereby facilitating accurate diagnosis and treatment. Unfortunately, infiltrating endometriotic lesions can mimic malignancies: Radiologists should be, therefore, familiar with the MRI findings in order to avoid false positive report.^[2] ^{18}F -FDG can occasionally accumulate in uterus and ovaries, more frequently in menstrual and ovulatory phase.^[3] There is no univocal agreement on the grade of FDG uptake in ectopic endometrial tissue, also due to the small number of studies published on this specific topic. Increased FDG uptake in endometriosis was described in three case reports as the cause of false positive PET finding.^[4-6] Moreover, Rieber *et al.* observed four cases of endometriosis falsely interpreted as malignancies by PET in a series of suspicion ovarian masses.^[7] Activated macrophages, high proliferative activity, and microvessel density, which frequently occur in the endometrioid tissue, could explain this high uptake of FDG.

On the contrary, Fastrez *et al.*^[8] have demonstrated the absence of significant FDG uptake in a prospective study

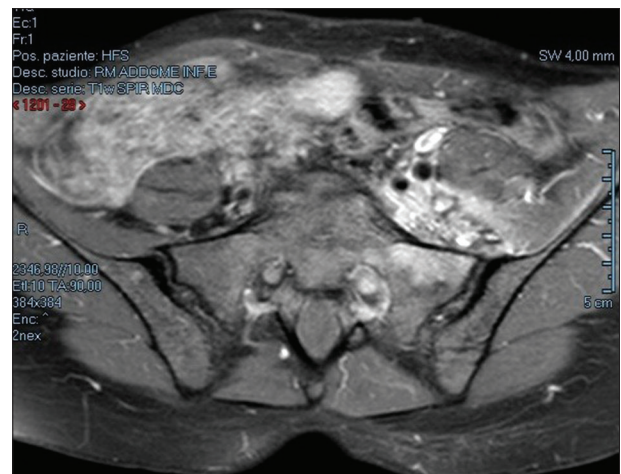


Figure 1: Contrast-enhanced T1-weighted MRI sequence showing a retroperitoneal mass infiltrating left psoas and iliac muscles, L5-S1 left conjugation foramen with edema of spongy bone

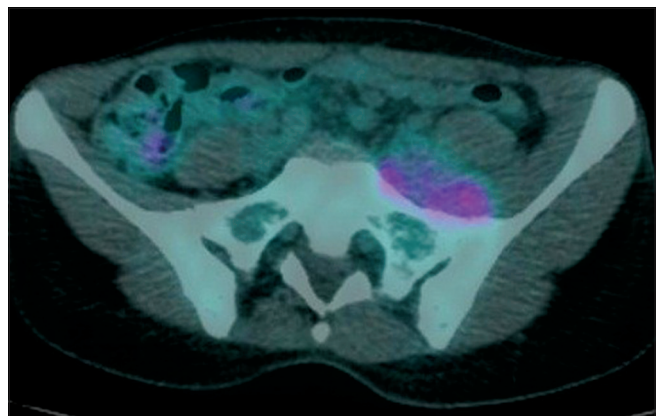


Figure 2: Fused transaxials of ^{18}F -FDG PET/CT showing inhomogeneous increased FDG uptake (SUVmax 4.8) to the front edge of the left sacral wing

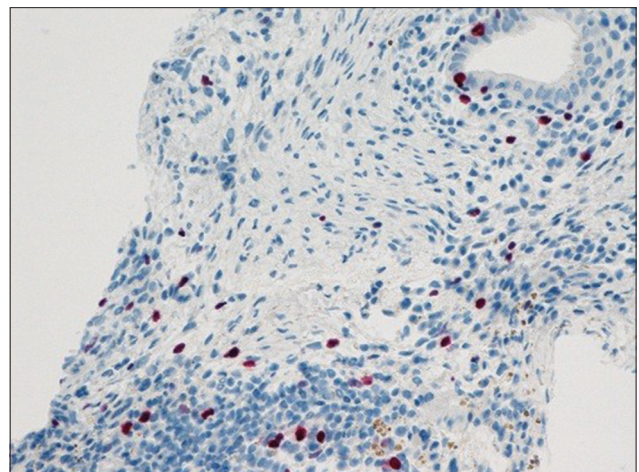


Figure 3: Tissue biopsy section showing relatively low Ki-67 proliferative rate (nuclear red stain) of a small endometrial gland and stroma. Brown granules are hemosiderin (Ki-67 immunoperoxidase stain, Fast Red, $\times 200$)

on nine patients with endometriosis (but only five with pathology confirmation) during the follicular phase of the cycle. It has to be underlined that the presence of large cystic endometrioid glands (observed in four out of nine patients of that cohort) could be the cause of false negative PET scan.

A recent study^[9] has demonstrated that proliferation activity in endometrioid tissue is responsive to the menstrual cycle: Proliferative phase corresponds to an increase of cell proliferation (stroma and epithelium) while the secretory phase is characterized by a more quiescent behavior. It has been demonstrated that apparent diffusion coefficient values of diffusion-weighted MRI in endometrioma is different in the menstrual versus luteal phase.^[10] A similar evidence has not yet been demonstrated for FDG PET. The hypothesis that the different phases of the menstrual cycle may influence the degree of endometriotic glycolytic activity and hence, the intensity of FDG uptake requires studies with a large population where the PET and biopsies are performed in the same phase of the menstrual cycle.

References

1. Olive DL, Schwartz LB. Endometriosis. *N Engl J Med* 1993;328:1759-69.
2. Coutinho A Jr, Bittencourt LK, Pires CE, Junqueira F, Lima CM, Coutinho E, *et al.* MR imaging in deep pelvic endometriosis: A pictorial essay. *Radiographics* 2011;31:549-67.
3. Lerman H, Metser U, Grisaru D, Fishman A, Lievshitz G, Even-Sapir E. Normal and abnormal ¹⁸F-FDG endometrial and ovarian uptake in pre-and postmenopausal patients: Assessment by PET/CT. *J Nucl Med* 2004;45:266-71.
4. Derman AY, Sperling D, Merav A, Jain VR, Levin M, Jana S, *et al.* Endometrioma presenting as a cavitary lung mass with intense ¹⁸F-FDG uptake on PET-CT. *J Thorac Imaging* 2007;22:172-5.
5. Jeffry L, Kerrou K, Camatte S, Metzger U, Lelièvre L, Talbot JN, *et al.* Endometriosis with FDG uptake on PET. *Eur J Obstet Gynecol Reprod Biol* 2004;117:236-9.
6. Holder WD Jr, White RL Jr, Zuger JH, Easton EJ Jr, Greene FL. Effectiveness of positron emission tomography for the detection of melanoma metastases. *Ann Surg* 1998;227:764-9.
7. Rieber A, Nüssle K, Stöhr I, Grab D, Fenchel S, Kreienberg R, *et al.* Preoperative diagnosis of ovarian tumors with MR imaging: Comparison with transvaginal sonography, positron emission tomography, and histologic findings. *AJR Am J Roentgenol* 2001;177:123-9.
8. Fastrez M, Nogarède C, Tondeur M, Sirtaine N, Rozenberg S. Evaluation of ¹⁸FDG PET-CT in the diagnosis of endometriosis: A prospective study. *Reprod Sci* 2011;18:540-4.
9. Strehl JD, Hackl J, Wachter DL, Klingsiek P, Burghaus S, Renner SP, *et al.* Correlation of histological and macroscopic findings in peritoneal endometriosis. *Int J Clin Exp Pathol* 2014;7:152-62.
10. Genç B, Solak A, Sahin N, Genç M, Ogul H, Sivrikoz ON, *et al.* Diffusion-weighted imaging in the evaluation of hormonal cyclic changes in abdominal wall endometriomas. *Clin Radiol* 2014;69:130-6.

How to cite this article: Maffione AM, Panzavolta R, Lisato LC, Ballotta M, D'Isanto MZ, Rubello D. Retroperitoneal Endometriosis: A Possible Cause of False Positive Finding at ¹⁸F-Fluorodeoxyglucose Positron Emission Tomography/Computed Tomography. *World J Nucl Med* 2015;14:131-3.

Source of Support: Nil. **Conflict of Interest:** None declared.