

Original article

Modified PISAPED Criteria in Combination with Ventilation Scintigraphic Finding for Predicting Acute Pulmonary Embolism

Naoyuki Watanabe, Jure Fettich¹, Nurie Özlem Küçük², Otakar Kraft³, Fernando Mut⁴, Partha Choudhury⁵, Surendra K. Sharma⁶, Keigo Endo⁷, Maurizio Dondi

Department of Nuclear Sciences and Applications, Division of Human Health, International Atomic Energy Agency, Vienna, Austria, ¹Department of Nuclear Medicine, University Medical Center, Ljubljana, Slovenia, ²Department of Nuclear Medicine, Ankara University, Ankara, Turkey, ³Department of Nuclear Medicine, University Hospital, University of Strava, Ostrava, Czech Republic, ⁴Nuclear Medicine Service, Spanish Association Hospital, Montevideo, Uruguay, ⁵Department of Nuclear Medicine, Rajiv Gandhi Cancer Institute and Research Centre, ⁶Department of Medicine, Division of Pulmonary, Critical Care and Sleep Medicine, All India Institute of Medical Sciences, New Delhi, India, ⁷Kyoto Medical Science College, Kyoto, Japan

Abstract

This prospective clinical study aimed at assessing three pulmonary scintigraphic algorithms to detect acute pulmonary embolism (PE): Lung ventilation/perfusion (V/Q) scintigraphy along with modified prospective investigation of pulmonary embolism diagnosis (PIOPED) criteria; lung perfusion scintigraphy along with prospective investigative study of acute pulmonary embolism diagnosis (PISAPED) criteria; and lung perfusion scan in combination with ventilation scan, along with modified PISAPED criteria, which were newly developed. Patients with suspicion of PE were eligible for this study if they had no abnormal chest x-ray. Their diagnostic workup included a clinical assessment, a pulmonary V/Q scintigraphy, and CT pulmonary angiography (CTPA), as well as a clinical outcome assessment over a period of 24 weeks. Referred to the final clinical diagnosis of patients, the sensitivity and specificity of each algorithm were evaluated. The diagnostic performance of each algorithm by the area under the maximum likelihood fitted receiver operating characteristic (ROC) curve was determined. With respect to the PISAPED criteria, the sensitivity was 60.8% and specificity was 87.3%. No patient was classified into nondiagnostic category. The PIOPED criteria showed that the sensitivity was 95.0% and specificity was 88.2%, while 57.4% of the patients were in nondiagnostic category. The areas under the ROC curve constructed from the PISAPED criteria results and the modified PIOPED criteria results were 0.734 and 0.859 ($P < 0.01$), respectively. The modified PISAPED criteria demonstrated that the sensitivity was 83.8% and specificity was 89.1%. No patient was classified into nondiagnostic category. The area under the ROC curve constructed from modified PISAPED criteria was 0.864 ($P < 0.01$). Perfusion scans used with ventilation scans and modified PISAPED criteria may increase the diagnostic accuracy of pulmonary scintigraphy for acute PE, compared with the two major algorithms.

Keywords: Acute pulmonary embolism, modified prospective investigation of pulmonary embolism diagnosis criteria, modified prospective investigative study of acute pulmonary embolism diagnosis criteria, PISAPED criteria, pulmonary scintigraphy

Access this article online

Quick Response Code:



Website:
www.wjnm.org

DOI:
10.4103/1450-1147.163248

Introduction

Efficacy and continued technical improvements in CT pulmonary angiography (CTPA) have produced a significant rise in its use for the diagnosis of acute pulmonary embolism (PE).^[1] The growth of CTPA has produced a corresponding reduction in the utilization

Address for correspondence:

Dr. Naoyuki Watanabe, Medical Director, Gunma Prefectural Government, Gunma 373-0033, Japan. E-mail: wata-na@pref.gunma.lg.jp

of pulmonary scintigraphy to the extent that some publications have suggested that lung scanning has become a second-line test.^[2-4] The several distinct advantages of multiple detector CT (MDCT) including high specificity, availability, and the superior ability to supply alternative diagnoses have come at the expense of an increased radiation burden.^[4] The effect of a low clinical threshold for utilization that promotes indiscriminate and repeated use, particularly in younger patients, is yet to be felt.^[4] Although the statistical data may be difficult to gather, it is intuitive that the lower radiation dose and higher sensitivity of scintigraphy in younger patients can only be beneficial.^[4] As with CT, scintigraphy offers specific advantages in a number of scenarios, particularly those in which high negative predictive value and low radiation dose are of parallel importance, such as in a young pregnant patient.^[4] The routine use of scintigraphy in patients who are young, have no preexisting lung pathology, and have a normal chest radiograph should not be demeaned.^[4] Scintigraphy remains one of the best tests yet established for the follow-up of PE after diagnosis and shows significant advantage in the investigation of the etiology of pulmonary hypertension.^[4]

Lung ventilation/perfusion (V/Q) scintigraphy along with modified prospective investigation of pulmonary embolism diagnosis (PIOPED) interpretation criteria has been utilized to diagnose acute PE.^[5-7] More recently, a simplified algorithm comprising pulmonary perfusion scan along with prospective investigative study of pulmonary embolism diagnosis (PISAPED) interpretation criteria^[8] has shown a reduction of intermediate probability as one of the lung scan readings generated by the modified PIOPED criteria and has improved the sensitivity and specificity of the lung scintigraphy along with the modified PIOPED criteria to detect acute PE.^[9] However, it has been reported that results obtained with the perfusion scan along with the PISAPED criteria are less satisfactory than those results obtained in the context in which the test was developed.^[10]

Therefore, a prospective clinical study conducted by the International Atomic Energy Agency (IAEA) through the Coordinated Research Project (CRP) E1.30.20 was undertaken to assess two pulmonary scintigraphic algorithms, one employing lung V/Q scan along with modified PIOPED criteria^[5-7] and the other employing only a pulmonary perfusion scan along with PISAPED criteria.^[8] In addition, a new algorithm and lung perfusion scintigraphy in combination with ventilation scan along with modified PISAPED criteria, which were developed by us in an effort to improve the sensitivity and specificity to detect acute PE, were similarly evaluated.

Materials and Methods

Study protocol

A standard procedure of the IAEA CRP E1.30.20, entitled "Evaluation of a single utilization of pulmonary perfusion scintigraphy in patients with suspected pulmonary embolism" is described as follows:

- All patients suspected of having PE will be given a clinical score of pretest likelihood based on clinical and biochemical data, results of a chest x-ray (CXR), an electrocardiogram (ECG), arterial blood gases, and a digital ultrasound (DUS)
- Patients with low likelihood and a negative D-dimer (DD) will not proceed to any further imaging but will be followed up for 24 weeks
- Patients with positive DD, or an intermediate or high likelihood, will have a V/Q scan and CTPA
- All patients will be assessed clinically by a physician every 12 weeks for 24 weeks. The physician will be aware of the results of all the above tests so as to formulate an overall judgment on patients' outcome
- DUS should be repeated at the final follow-up examination.
- If echocardiography was used in the initial scoring, it should also be used in the final follow-up examination.

Inclusion criteria are

- Patients presenting with suspicion of acute PE within 24 h
- Informed written consent, approved by the local ethical committee, should be obtained.

Exclusion criteria are

- Pregnant females and children under 18 years
- Patients with established major right-left shunt
- Patients with a life expectancy of less than 24 weeks
- Patients who have been on thrombolytic therapy for >3 days before the event
- Patients who can be difficult to follow up for 24 weeks
- Patients who are known to be allergic to iodine
- Patients who suffer renal failure
- Patients who are known to have pulmonary hypertension.

The study procedure is summarized in Figure 1.

The type of gamma camera, ventilation agent, and CTPA in each institute is summarized in Table 1. The methodology for pulmonary scintigraphy followed the procedure guidelines for lung scintigraphy as published by the Society of Nuclear Medicine.^[11] The CTPA procedure was conducted following local protocols in each institute. All patients had given informed consent

for the present study, and no patient was personally identified in this study.

Patients

Patients were enrolled from five nuclear medicine departments in Slovenia, Turkey, the Czech Republic, Uruguay, and India between October 2004 and September 2008. Two hundred and one patients with suspected acute PE were registered in the study. Out of the total number of patients, 129 were eligible for this current study since they showed no abnormalities in CXR. The group comprised 66 females (mean age 60 years, range 19-95 years) and 63 males (mean age 58 years, range 22-85 years).

Scintigraphic criteria for PE interpretation

Two experienced nuclear medicine physicians who had no clinical information on patients independently assessed the V/Q scans according to modified PIOPED criteria as PE present, PE absent, or nondiagnostic [Table 2]. Then, they independently evaluated perfusion scans according to

the conventional PISAPED criteria as PE present, PE absent, or nondiagnostic [Table 2]. Finally, the nuclear medicine physicians interpreted the perfusion scans in combination with ventilation scans according to modified PISAPED criteria as PE present, PE absent, or nondiagnostic [Table 3].

CTPA criteria for PE interpretation

Two experienced radiologists who had no clinical information on patients independently assessed CTPAs according to the CTPA criteria as PE present, PE absent, or nondiagnostic [Table 4].^[12-14]

Evaluation of final clinical assessment

A clinician with extensive experience in acute PE who was blind to interpretations on any medical imaging, except for CXR, assessed the clinical follow-up within a period of 24 weeks (the efficacy of subsequent anticoagulation treatment and the clinical outcome of the patients at 24 weeks from the acute episode brought by the local physicians). This assessment was a reference standard for the final clinical diagnosis of acute PE in this study.

Data analysis

The primary analysis compared the CTPA criteria results, the modified PIOPED criteria results, the PISAPED criteria results, and the modified PISAPED criteria results using the clinical outcome at 24 weeks as reference standard for the final clinical diagnosis of acute PE. The sensitivity and specificity of each algorithm were obtained. Nondiagnostic scintigram readings were

Table 1: Type of gamma camera, ventilation agent, and CTPA in each institute

Participated institute	Gamma camera	Ventilation agent	CTPA
CZR	Dual head	99mTc-DTPA aerosol	MDCT (16 slices)
IND	Dual head	99mTc-DTPA aerosol	Spiral CT
SLO	Dual head	133Xe-gas	MDCT (16 slices)
TUR	Single head	99mTc-ultrafine gas	Spiral CT
URG	Dual head	99mTc-ultrafine gas	Spiral CT

CTPA: CT pulmonary angiography; MDCT: Multiple detector CT

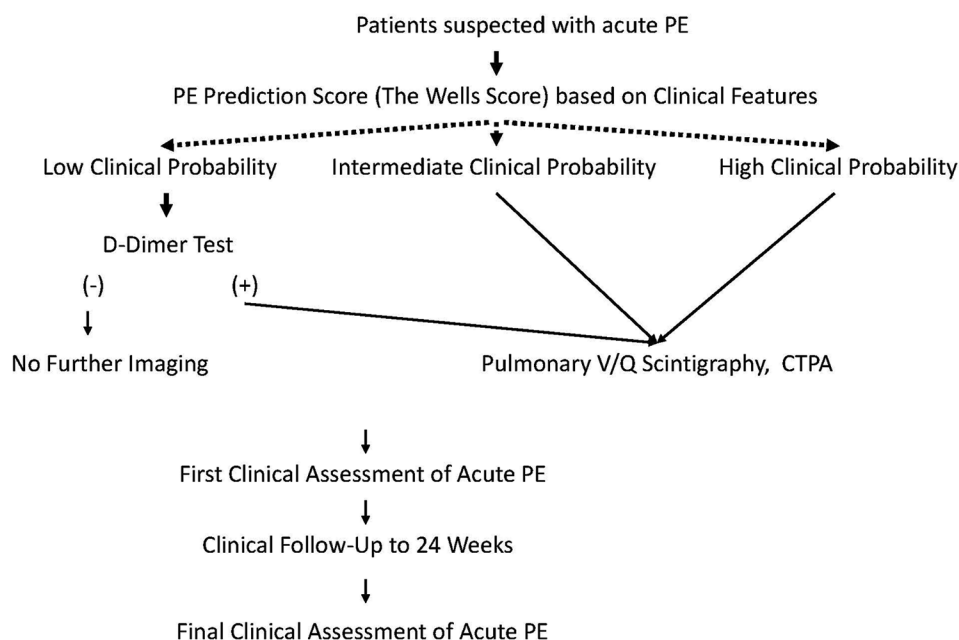


Figure 1: Main scheme of a study of IAEA CRP E1.30.29

Table 2: Modified PLOPED criteria and PISAPED scintigraphic criteria

Criteria		
Finding	Modified PLOPED	PISAPED
PE present	High probability Two or more large mismatched segmental defects or equivalent moderate/large defects with a normal x-ray Any perfusion defect substantially larger than radiographic abnormality	Abnormal, suggestive of PE Presence of single or multiple wedge-shaped perfusion defects, the size of which corresponds to that of lobar, segmental, or subsegmental regions of the lung
PE absent	Normal scan No perfusion defects Very low probability Three or less small perfusion defects with a normal x-ray Low probability Nonsegmental defects-small effusion blunting costophrenic angle, cardiomegaly, elevated diaphragm, ectatic aorta Any perfusion defect with substantially larger radiographic abnormality Matched ventilation and perfusion defects with normal chest radiograph Small subsegmental perfusion defects	Normal scan No perfusion defects Near normal Presence of impressions caused by enlarged heart, hila, or mediastinum on an otherwise normal scan Abnormal, not suggestive of PE Presence of single or multiple other than wedge-shaped perfusion defects
Nondiagnostic	Intermediate probability Multiple perfusion defects with associated radiographic opacities Greater than 25% of a segment and less than two mismatched segmental perfusion defects with normal radiograph, one moderate segmental, one large or two moderate segmental, one large and one moderate segmental, three moderate segmental Triple match: Solitary moderate-large matching segmental defect with matching radiograph Difficult to characterize as high probability or low probability due to poor image quality	All other findings or poor image quality

PLOPED: Prospective investigation of pulmonary embolism diagnosis; PISAPED: Prospective investigative study of acute pulmonary embolism diagnosis; PE: Pulmonary embolism

Table 3: Modified PISAPED scintigraphic criteria

Criteria	
Finding	Modified PISAPED
PE present	Abnormal (with normal ventilation) Presence of single or multiple wedge-shaped perfusion defects the size of which corresponds to that of lobar, segmental, or subsegmental regions of the lung and the perfusion defects being filled up with ventilation Abnormal (with normal ventilation) Presence of single or multiple other than wedge-shaped perfusion defects and the perfusion defects being filled up with ventilation
PE absent	Normal No perfusion defects and no abnormality of ventilation Near normal Presence of impressions caused by enlarged heart, hila, or mediastinum on an otherwise normal scan and ventilation defect Abnormal (without normal ventilation) Presence of single or multiple other than wedge-shaped perfusion defects and the perfusion defects not being filled up with ventilation Abnormal (without normal ventilation) Presence of single or multiple wedge-shaped perfusion defects the size of which corresponds to that of lobar, segmental, or subsegmental regions of the lung and the perfusion defects not being filled up with ventilation
Nondiagnostic	All other findings or poor image quality

PISAPED: Prospective investigative study of acute pulmonary embolism diagnosis; PE: Pulmonary embolism

then excluded from the calculation of sensitivity and specificity.

The second analysis determined the diagnostic performance of each algorithm by the area under maximum likelihood fitted receiver operating characteristic (ROC) curve.

P values smaller than 0.01 were assumed to be statistically significant.

Results

Of the 129 patients, 74 were evaluated as acute PE and 55 as nonacute PE according to the final clinical assessment, based on the clinical follow-up at 24 weeks. The two cases of CTPA fell in the nondiagnostic category on account of poor image quality. There was no discordance in clinical diagnosis of acute PE between the expert physicians and local physicians in the institutes for this study. Further, there was no discordance in interpretation of medical images except for CTPA between the expert readers for this study and local readers in the institutes.

The CTPA criteria resulted in 68 (53.5%) patients being classified as PE present and 59 (46.5%) as PE absent.

Two (1.6%) were in the nondiagnostic category because of poor image quality. The sensitivity of CTPA to detect acute PE was 91.7% and specificity was 96.4%.

The modified PIOPED criteria resulted in 40 (31.0%) patients being classified as PE present and 17 (13.2%) as PE absent. A further 74 (57.4%) were in the nondiagnostic category (intermediate probability). The sensitivity of the V/Q scan along with the modified PIOPED criteria to detect acute PE was 95.0% and specificity was 88.2%.

The PISAPED criteria resulted in 52 (40.3%) patients being classified as PE present and 77 (59.7%) as PE absent. No patient was classified into the nondiagnostic

category. The sensitivity of perfusion scan along with the PISAPED criteria was 60.8% and specificity was 87.3%.

The modified PISAPED criteria resulted in 68 (52.7%) patients being classified as PE present and 61 (47.3%) as PE absent. No patient was classified into the nondiagnostic category. The sensitivity of the perfusion scan in combination with ventilation scan, along with the modified PISAPED criteria was 83.8% and specificity was 89.1%.

The diagnostic performance of the V/Q lung scan along with the modified PIOPED criteria, as determined by the area under a maximum likelihood fitted ROC curve, measured 0.858 (95% CI, 0.804-0.913) [Figure 2]. The value was significantly higher ($P = 0.002$) when compared with that of the perfusion lung scan along with the PISAPED criteria, which measured 0.734 (95% CI, 0.660-0.807) [Figure 2].

The diagnostic performance of the perfusion scan in combination with ventilation scan, along with the modified PISAPED criteria measured 0.864 (95% CI, 0.807-0.922) as determined by the area under a maximum likelihood fitted ROC curve [Figure 3]. This value was significantly higher ($P = 0.001$) in comparison to that of the perfusion lung scan along with the PISAPED criteria [Figure 3].

Table 4: CTPA criteria

Criteria	CTPA
PE present	As acute PE, Complete arterial occlusion with failure to opacify vessel lumen. Artery may be enlarged as compared to others of the same order Central filling defect surrounded by contrast Periphebral intraluminal filling defect that makes an acute angle with the arterial wall
PE absent	Normal No perfusion defects by contrast As chronic PE, Complete occlusion of vessel that is smaller than others of same order of branching Peripheral filling defect that makes obtuse angles with the vessel wall Contrast flowing through vessels that appear thick-walled due to recanalization
Nondiagnostic	Poor image quality

CTPA: CT pulmonary angiography; PE: Pulmonary embolism

Discussion

The aim of this study was to evaluate three pulmonary scintigraphic algorithms for the detection of acute PE. In our study, the pulmonary perfusion scan along with

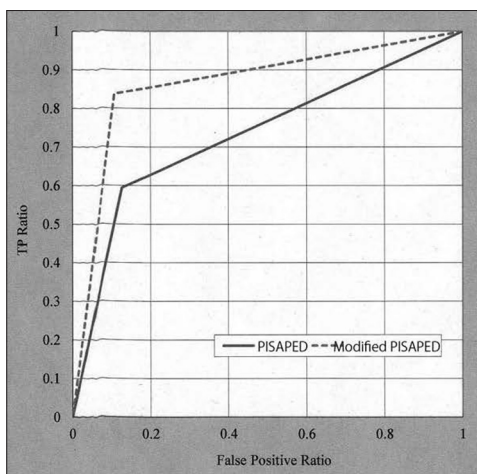


Figure 2: ROC curves demonstrated no superior diagnostic performance of the pulmonary perfusion scan along with the PISAPED criteria (solid line) compared with the lung V/Q scan along with the modified PIOPED criteria (dotted line)

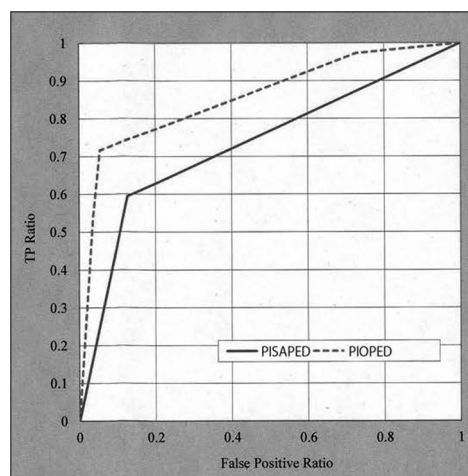


Figure 3: ROC curves showed the superior diagnostic performance of the pulmonary perfusion scan in combination with lung ventilation scan along with the modified PISAPED criteria (dotted line) compared with the pulmonary perfusion scan along with the PISAPED criteria (solid line)

the PISAPED criteria showed no improved accuracy in predicting acute PE compared with the V/Q scan along with the modified PIOPED criteria, except for reduction in the number of nondiagnostic cases. The simplified algorithm performed poorly in this regard as was previously reported.^[10] On the other hand, the new algorithm, the pulmonary perfusion scan in combination with ventilation scan along with the modified PISAPED criteria, which were developed by us demonstrated significantly improved accuracy in predicting acute PE in comparison to the simplified algorithm.

It was observed that 58.6% of the false-negative cases recognized by the PISAPED criteria were reclassified into the true positive category by making reference to the corresponding ventilation findings. Non-single, non-wedge-shaped defects with normal ventilation (50% of the false-negative cases) may be the result of acute PE. Pulmonary thromboembolism could dissolve into smaller parts with time.^[15] Therefore, wedge-shaped defects of pulmonary scintigraphic findings of perfusion may be transformed into non-wedge-shaped ones.^[15] Such a scene might be delineated in the first scintigraphy of the study. Serial-combined pulmonary ventilation-perfusion imaging is very useful to maximize diagnostic specificity for PE.^[15] On the other hand, wedge-shaped defects with abnormal ventilation (50% of the false-negative cases) may originate from non-PE. The decrease in pulmonary perfusion can emerge by means of the physiological mechanism of hypoxic vasoconstriction caused by ventilation abnormalities such as emphysema, pneumonia.^[16] These abnormalities are not so easy to detect on CXR images. Regional pulmonary ventilation abnormalities seem to become distinct in acute PE patients suffered from polypnea.

Our study may highlight that the finding of pulmonary ventilation scan is indispensable to the scintigraphic interpretation of acute PE.

Conclusion

The perfusion scan in combination with ventilation scan along with the modified PISAPED criteria may bring about reduction in the number of nondiagnostic cases and increase the diagnostic accuracy of pulmonary scintigraphy for acute PE in comparison to the two major algorithms.

Acknowledgement

A part of the study was presented at the Radiological Society of North America's 97th Scientific Assembly and Annual Meeting in Chicago, IL (RSNA2011).

References

- Schoepf UJ. Diagnosing pulmonary embolism: Time to rewrite the textbooks. *Int J Cardiovasc Imaging* 2005;21:155-63.
- Hayashino Y, Goto M, Noguchi Y, Fukui T. Ventilation-perfusion scanning and helical CT in suspected pulmonary embolism: Meta-analysis of diagnostic performance. *Radiology* 2005;234:740-8.
- O'Neil JM, Wright L, Murchison JT. Helical CTPA in the investigation of pulmonary embolism: A 6-year review. *Clin Radiol* 2004;59:819-25.
- Reid JH, Coche EE, Inoue T, Kim EE, Dondi M, Watanabe N, et al.; International Atomic Energy Agency Consultants' Group. Is the lung scan alive and well? Facts and controversies in defining the role of lung scintigraphy for the diagnosis of pulmonary embolism in the era of MDCT. *Eur J Nucl Med Mol Imaging* 2009;36:505-21.
- Freitas FE, Sarosi MG, Nagle CC, Yeomans ME, Freitas AE, Juni JE. Modified PIOPED criteria used in clinical practice. *J Nucl Med* 1995;36:1573-8.
- Sostman HD, Coleman RE, DeLong DM, Newman GE, Paine S. Evaluation of revised criteria for ventilation-perfusion scintigraphy in patients with suspected pulmonary embolism. *Radiology* 1994;193:103-7.
- Worsely DF, Alavi A. Comprehensive analysis of the results of the PIOPED study. Prospective Investigation of Pulmonary Embolism Diagnosis Study. *J Nucl Med* 1995;36:2380-7.
- Miniati M, Pistolesi M, Mariani C, Di Ricco G, Formichi B, Prediletto R, et al. Value of perfusion lung scan in the diagnosis of pulmonary embolism: Results of the prospective investigative study of acute pulmonary embolism diagnosis (Pisa-PED). *Am J Respir Crit Care Med* 1996;154:1387-93.
- Miniati M, Sostman HD, Gottschalk A, Monti S, Pistolesi M. Perfusion lung scintigraphy for the diagnosis of pulmonary embolism: A reappraisal and review of the prospective investigative study of acute pulmonary embolism diagnosis methods. *Semin Nucl Med* 2008;38:450-61.
- McLean RG, Carolan M, Bui C, Arvelo O, Ford JC, Chew M, et al. Comparison of new clinical and scintigraphic algorithms for the diagnosis of pulmonary embolism. *Br J Radiol* 2004;77:372-6.
- Parker JA, Coleman RE, Hilson AJ, Royal HD, Siegel BA, Sostman HD. Society of Nuclear Medicine Procedure Guideline for Lung Scintigraphy. The Society of Nuclear Medicine. Version 3.0. Approved February 7, 2004.
- Qanadli SD, Hajjam M, Mesurole B, Barré O, Bruckert F, Joseph T, et al. Pulmonary embolism detection: Prospective evaluation of dual-section helical CT versus selective pulmonary arteriography in 157 patients. *Radiology* 2000;217:447-55.
- Schoepf UJ, Holzknecht N, Helmberger TK, Crispin A, Becker CR, et al. Subsegmental pulmonary emboli: Improved detection with thin-collimation multi-detector row spiral CT. *Radiology* 2002;222:483-90.
- Wittram C, Maher MM, Yoo AJ, Kalra MK, Shepard JA, McCloud TC. CT angiography of pulmonary embolism: Diagnostic criteria and causes of misdiagnosis. *Radiographics* 2004;24:1219-38.
- Watanabe N, Oriuchi N, Suzuki H, Yukihiro M, Fukushima Y, Higuchi T, et al. A "changing stripe sign" in serial pulmonary perfusion imaging. *Clin Nucl Med* 1996;21:111-4.
- Watanabe N, Hirano T, Inoue T, Matsumoto M, Oriuchi N, Tateno M, et al. Transient unilateral reverse ventilation/perfusion mismatch in a patient with lung cancer. *Clin Nucl Med* 1992;17:705-8.

How to cite this article: Watanabe N, Fettich J, Kūçük NÖ, Kraft O, Mut F, Choudhury P, et al. Modified PISAPED Criteria in Combination with Ventilation Scintigraphic Finding for Predicting Acute Pulmonary Embolism. *World J Nucl Med* 2015;14:178-83.

Source of Support: Nil. **Conflict of Interest:** None declared.