

## Case report

# A Case of Lingual Thyroid Presenting with Severe Hematemesis in Pregnancy

Amol Sudke, Amit Kumar Dey, Suchin Dhamanskar, Varsha Kulkarni

Department of General Surgery, King Edward Memorial Hospital, Mumbai, Maharashtra, India

## Abstract

Lingual thyroid is a rare anomaly with symptoms such as upper airway obstruction, dysphagia, or hypothyroidism. However, bleeding is a very rare manifestation. This report describes a case of lingual thyroid in women with 28 weeks of amenorrhea and hematemesis, and its course of diagnosis and treatment. The pathogenesis of lingual thyroid is unknown. Although ectopic lingual thyroid is usually not managed surgically, excision of ectopic lingual thyroid can be lifesaving when it is causing bleeding or airway obstruction. However, during pregnancy, surgery is the preferred mode of treatment.

**Keywords:** Hematemesis, lingual thyroid, pregnancy

## Introduction

Lingual thyroid is a rare anomaly of the developing thyroid gland, due to which the gland fails in descending from its anlage, early in the course of embryogenesis.<sup>[1]</sup> Most of the lingual thyroids are symptomatic during pregnancy, puberty, and menses because these conditions result in hypertrophy of the lingual thyroid tissue.<sup>[2]</sup> The prevalence rate of lingual thyroid varies from 1 in 100,000 to 1 in 300,000, with a predominance of female patients; the ratio of females to males ranges from 4:1 to 7:1. In 70% of the patients with lingual thyroid, there is no other thyroid tissue and hypothyroidism is reported in one-third of the patients.<sup>[3]</sup>

Our case was written with an objective to report a very rare case of lingual thyroid during pregnancy, presenting with hematemesis that is a very rare symptom, and its course of diagnosis and management.

## Case Report

A 24-year-old primigravida with 28 weeks of amenorrhea was admitted as an emergency case in 2014 with two episodes of bright red hematemesis of 200 mL each, referred from a private nursing home. She was of a small stature and she was fairly well-nourished. This was the first event with no history of vomiting, abdominal pain, weight loss, or dysphagia. On examination, oral and nasal mucosae showed no abnormality. There was no abdominal tenderness, guarding, or rigidity. Pulse rate recorded was 110 bpm and the blood pressure recorded was 90/60 mmHg. Respiratory sounds were bilaterally clear to auscultation and bowel sounds were heard in all four quadrants of the abdomen. On admission, a Ryle's tube was placed. Blood was drawn for blood investigations including blood group and crossmatch, and she was started on intravenous fluids. Fetal heart sounds were heard on the Doppler. In the meantime, upper gastrointestinal (GI) endoscopy was done that revealed no abnormality. The reports showed blood hemoglobin level to be 7 g/dL and hematocrit to be 35%. Abdominal examination revealed no epigastric tenderness. Red blood cell count was 3.5 trillion cells/L and white blood cell count was 20,000 (polymorphs 85%, lymphocytes 10%, large monocytes 4%, and eosinophils 1%). The patient again had an episode of bright red hematemesis of 300 mL after some time. This was followed by loss of fetal heart sounds on the

### Access this article online

#### Quick Response Code:



Website:  
www.wjnm.org

DOI:  
10.4103/1450-1147.167580

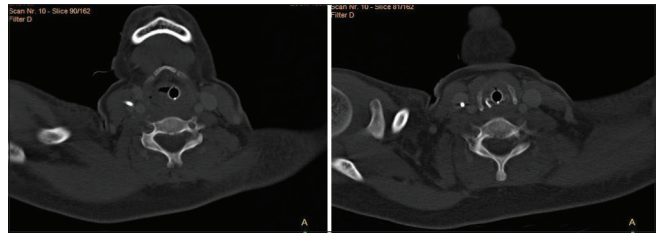
#### Address for correspondence:

Dr. Amit Kumar Dey, Room No. 107, Main Boy's Hostel, Acharya Donde Marg, Parel, Mumbai - 400 012, Maharashtra, India.  
E-mail: amit5kem@gmail.com

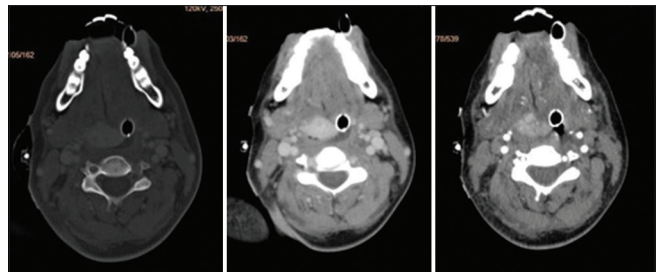
Doppler with intrauterine fetal demise. Ryle's tube was taken out and upper GI endoscopy was done again that revealed no anomaly. Immediately, a Ryle's tube was placed again. This was succeeded by one more similar episode of hematemesis following which the department of otolaryngology was called for evaluation. They did an endoscopy again and while removing the endoscope, bleeding was noticed at the oropharynx. Examination of the mouth with the help of a laryngeal mirror revealed a sublingually present pale-pink, globular mass. The suprasternal space appeared to be empty and the trachea was easily palpable. The thyroid gland could not be felt in the neck. Hence, it was suspected as a case of lingual thyroid. The bleeding area was packed and subsequently a tracheostomy was done to prevent any risk of aspiration from hematemesis under local anesthesia. A computed tomography (CT) was done that did not show the thyroid gland in its normal anatomical position [Figure 1]. The CT also revealed a well-defined mass in the midline of the tongue base [Figure 2]. Thyroid scintigraphy (technetium (Tc)-99m) showed an ectopic uptake in the tongue base consistent with lingual thyroid and no uptake in the normal thyroid location. [Figure 3]. The serum triiodothyronine (T3) level was 113.7 ng/dL, the free thyroxine (T4) level was 1.62 ng/dL, and the thyroid-stimulating hormone (TSH) was 3.35  $\mu$ IU/mL, all of which were in the normal range. After packing, the hematemesis stopped. The patient received four units of packed red blood cells after which the patient's hematocrit improved. After the patient was made stable, normal vaginal delivery was achieved without any complications. After the delivery was performed, there were no more episodes of hematemesis. She was gradually weaned off tracheostomy. There was no need for the patient to be operated for the removal of the lingual thyroid. The patient was discharged after 10 days, and the post-discharge course was uneventful. There was no need of surgery in our case to remove the lingual thyroid.

## Discussion

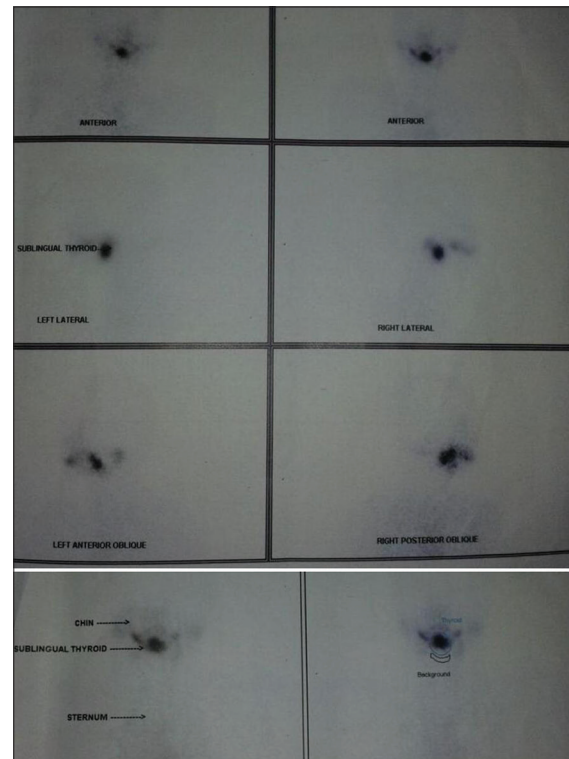
Lingual thyroid is an ectopic thyroid tissue forming a mass at the base of the tongue. Of all cases, 90% of ectopic thyroid usually occur at the base of the tongue that is known as lingual thyroid.<sup>[4]</sup> Although the pathogenesis is unclear, some authors have postulated that maternal antithyroid immunoglobulins may impair gland descent during early fetal life.<sup>[5]</sup> Lingual thyroid has varied clinical presentations ranging from oropharyngeal obstruction, which may include dysphagia (mild or severe), dyspnea and dysphonia, fullness in the throat, and sleep apnea. Stridor is the most common in neonates. Bleeding from lingual thyroid is a very rare presentation in the form of hematemesis.<sup>[6]</sup> The lingual thyroid tissue may be present as a painless, midline, nontender, and reddish swelling at



**Figure 1:** CT scan of the neck reveals that the thyroid gland is not in its normal anatomical position



**Figure 2:** CT scan of the neck reveals a slightly hyper dense mass at the midline that is not distinguishable from the posterior aspect of the tongue. Normal thyroid gland is not seen at the anatomical location. Lymphadenopathy is not seen



**Figure 3:** Tc-99m thyroid scan showing evidence of functioning lingual thyroid. The functioning thyroid tissue is not noted at the normal location of thyroid gland

the base of the tongue with a smooth or irregular surface with or without prominent blood vessels that can lead to massive hemorrhaging if large blood vessels are present. The mean age when clinical manifestations of obstruction or bleeding occur is 40 years, with two statistical peaks

at 12 years and 50 years of age.<sup>[2]</sup> In our case, massive bleeding from the lingual thyroid was noted during the 28 weeks of the patient's pregnancy. The possible cause may be the result of an increased blood flow and relative insufficiency of thyroid hormone or any trauma during procedures to the lingual thyroid. Physical examination of the head and neck with special attention to the base of the tongue is mandatory to check the presence or the absence of the thyroid gland in its normal position.

Initial laboratory studies should include thyroid function tests to find out whether the gland is functioning properly under the stimulation of the hormones such as T3, T4, and TSH.<sup>[7]</sup> It can be confirmed either by <sup>131</sup>I or Tc-99m scan or by an unenhanced CT scan.<sup>[8]</sup> CT scan differentiates lingual thyroid from other swellings as the high iodine content results in hyperdensity as compared to other tissues.<sup>[3]</sup> Histologic confirmation is usually not necessary unless iodine or CT scanning result is negative or unless malignancy is suspected. Wood has noted the association of a fetal adenoma with the lingual thyroid.<sup>[8]</sup>

Treatment of the lingual thyroid depends on many factors like size, the presence or absence of symptoms, and complicating factors such as ulceration, hemorrhage, malignancy, or airway obstruction.<sup>[2]</sup> Levothyroxine is indicated in patients with mild symptoms or hypothyroidism while surgery is the mainstay in patients with worsening symptoms.<sup>[7]</sup> Patients with airway obstruction, dysphagia, suspected malignancy, ulceration, and hemorrhaging or those who fail thyroxine suppression therapy should undergo <sup>131</sup>I ablation or surgical excision of the thyroid tissue with or without autotransplantation. However, surgical treatment is the method of choice for lingual thyroid in pregnancy though in our case it resolved on its own.<sup>[2]</sup> Prasad *et al.* reported the suprahyoid approach instead of transoral route for better operative field and hemostasis.<sup>[9]</sup>

Massive bleeding in the ectopic lingual thyroid is an indication for a need of surgical intervention. Embolizing

the main feeding artery to the lingual thyroid before the operation is a mandatory step for hemostasis, reducing the bleeding in the surgical field. Because pregnancy can increase the risk of bleeding, more attention should be paid to a pregnant woman with lingual thyroid as in our case.<sup>[2]</sup>

## Conclusion

The primary objective of this article is to report a very rare case of lingual thyroid in a pregnant patient with 28 weeks of amenorrhea and hematemeses that pose a diagnostic challenge for us. Surgery is the preferred method of treatment during pregnancy.

## References

1. Batsakis JG, El-Naggar AK, Luna MA. Thyroid gland ectopias. *Ann Otol Rhinol Laryngol* 1996;105:996-1000.
2. Chiu TT, Su CY, Hwang CF, Chien CY, Eng HL. Massive bleeding from an ectopic lingual thyroid follicular adenoma during pregnancy. *Am J Otolaryngol* 2002;23:185-8.
3. Rahbar R, Yoon MJ, Connolly LP, Robson CD, Vargas SO, McGill TJ, *et al.* Lingual thyroid in children: A rare clinical entity. *Laryngoscope* 2008;118:1174-9.
4. Chanin LR, Greenberg LM. Pediatric upper airway obstruction due to ectopic thyroid: Classification and case reports. *Laryngoscope* 1998;98:422-7.
5. van der Gaag RD, Drexhage HA, Dussault JH. Role of maternal immunoglobulins blocking TSH-induced thyroid growth in sporadic forms of congenital hypothyroidism. *Lancet* 1985;1:246-50.
6. Amr B, Monib S. Lingual thyroid: A case report. *Int J Surg Case Rep* 2011;2:313-5.
7. Lai YT, Chen HS, Chang YL. Lingual thyroid. *Otolaryngol Head Neck Surg* 2009;140:944-5.
8. Kansal P, Sakati N, Rifai A, Woodhouse N. Lingual thyroid. Diagnosis and treatment. *Arch Intern Med* 1987;147:2046-8.
9. Prasad KC, Bhat V. Surgical management of lingual thyroid: A report of four cases. *J Oral Maxillofac Surg* 2000;58:223-7.

**How to cite this article:** Sudke A, Dey AK, Dhamanskar S, Kulkarni V. A case of lingual thyroid presenting with severe hematemeses in pregnancy. *World J Nucl Med* 2016;15:134-6.

**Source of Support:** Nil, **Conflict of Interest:** None declared.