

Original article

^{18}F -Sodium Fluoride PET-CT Hybrid Imaging of the Lumbar Facet Joints: Tracer Uptake and Degree of Correlation to CT-graded Arthropathy

Marc C. Mabray, Marcel Brus-Ramer, Spencer C. Behr, Miguel H. Pampaloni, Sharmila Majumdar, William P. Dillon, Jason F. Talbott

Department of Radiology and Biomedical Imaging, University of California, San Francisco, California, USA

Abstract

We aim to evaluate ^{18}F -NaF uptake by facet joints with hybrid PET-CT technique. Specifically, we evaluate NaF uptake in the facet joints of the lower lumbar spine, and correlate with the morphologic grade of facet arthropathy on CT. 30 consecutive patients who underwent standard vertex to toes NaF PET-CT for re-staging of primary neoplastic disease without measurable or documented bony metastases were identified. Maximum (SUVmax) and average (SUVavg) standardized uptake values were calculated for each L3-4, L4-5, and L5-S1 facet joint ($n = 180$) and normalized to average uptake in the non-diseased femur. A Pathria grade (0-3) was assigned to each facet based upon the CT morphology. Spearman's rank correlation was performed for normalized SUVmax and SUVavg with Pathria grade. ANOVA was performed with Tukey-Kramer pairwise tests to evaluate differences in uptake between Pathria groups. Facet normalized SUVmax ($r = 0.31$, $P < 0.001$) and SUVavg ($r = 0.28$, $P < 0.001$) demonstrated a mild positive correlation with CT Pathria grade. There was a wide range of uptake values within each Pathria grade subgroup with statistically significant differences in uptake only between Pathria grade 3 as compared to grades 0, 1, and 2. In conclusion, NaF uptake and morphologic changes of the facet joint on CT are weakly correlated. Physiologic information provided by NaF uptake is often discrepant with structural findings on CT suggesting NaF PET may supplement conventional structural imaging for identification of pain generating facet joints. Prospective investigation into the relationship of facet joint NaF uptake with pain and response to pain interventions is warranted.

Keywords: Lumbar facet, sodium fluoride positron emission tomography, positron emission tomography-computed tomography, ^{18}F -sodium fluoride

Introduction

Lumbar facet syndrome is a major cause of morbidity in the United States, with the origin of lower back pain traced to the facet joints in up to 15-45% of cases.^[1] Severe facet joint degenerative changes are most common at the L4-5 and L5-S1 levels where they have been associated with significant back pain.^[2,3] The pathology of facet arthropathy is similar to other

joints, including cartilage loss and subchondral bone exposure.^[4] Characteristic radiographic features of facet joint arthropathy involve both degenerative and proliferative changes including narrowing of the facet joint space, subarticular bone erosion, subchondral cystic formation, osteophyte formation, and hypertrophy of the articular process.^[5] Unfortunately, commonly employed radiographic studies that reflect static structural changes, including computed tomography (CT), show poor correlation to measures of pain relief following diagnostic facet injections.^[6,7]

Noninvasive imaging techniques are needed to more accurately identify patients who will benefit from interventional therapies for facet syndrome. Increased stress on the facet joints results in physiologic changes in the underlying bone that precede the morphological

Access this article online

Quick Response Code:



Website:
www.wjnm.org

DOI:
10.4103/1450-1147.174698

Address for correspondence:

Dr. Marc C. Mabray, 505 Parnassus Ave M391, San Francisco - 94143, California, USA. E-mail: marc.mabray@ucsf.edu

changes demonstrated by radiographic techniques.^[4] Techniques that reflect bone turnover and remodeling may be able to reveal these pathologic changes more closely. Technetium-99m methylene diphosphonate (Tc-99m MDP) bone scintigraphy has identified sites of increased bone turnover in patients with knee osteoarthritis and pain.^[8,9] Similarly, Tc-99m MDP planar scintigraphy and single photon emission computed tomography (SPECT) have shown increased uptake corresponding to areas of abnormality in the spine including the site of facet osteoarthritis.^[10-14] ¹⁸F-sodium fluoride (NaF) is a positron emission tomography (PET) radiopharmaceutical that has been shown to reflect bone turnover, and may identify physiologic changes in the facet joint not reflected by simple structural abnormalities seen on CT and magnetic resonance imaging (MRI).^[15] Thanks to the inherent physical characteristics of the positron and the higher spatial and temporal resolution provided by PET imaging systems, NaF has been shown to compare favorably with conventional Tc-99m MDP planar or SPECT imaging to assess metabolic bone changes.^[15] PET-computed tomography (PET-CT) hybrid imaging has the added advantage of highly accurate anatomic localization of bony pathology.

NaF is incorporated into the bone at sites of remodeling with high metabolic activity via hydroxyl ion exchange triggered by osteoblast and osteoclast activity.^[16] NaF PET, therefore, preferentially localizes in sites of greater bone remodeling and increased perfusion. Although limited, current published data evaluating NaF PET in the site of lower back pain suggest that NaF uptake may identify sites of pain and inflammation in the spine and sacroiliac joints.^[17-20] Despite these data, to our knowledge, no study has specifically correlated NaF uptake in the facet joints to pathologic CT findings using hybrid PET-CT technique. The aim of our study was to evaluate normalized NaF uptake in facet arthropathy of the lumbar spine, and to correlate this to the CT findings in the same areas. We hypothesize that NaF uptake will be observed in the setting of CT arthropathy, but that the correlation with morphologic findings may be variable, representative of a wide array of pathophysiological abnormalities with different degrees of structural alterations. Such findings would serve as enticing preliminary data to suggest that physiologic information added by NaF PET would potentially complement conventional structural imaging modalities and inspire prospective study with clinical outcome assessment.

Materials and Methods

Patients

This study was performed with the Institutional Review Board's approval including a waiver of informed

consent. Thirty consecutive patients who underwent ¹⁸F-NaF PET-CT imaging over a 3-year period from 2011 to 2014 for cancer restaging were retrospectively identified at our institution for this cross-sectional study. Exclusion criteria included prior spinal instrumentation, lumbar spine fracture, or evidence (documented or measurable) of metastatic osseous disease.

Imaging protocol

Whole body volumetric PET-CT images were obtained using either a biograph 16 (high resolution) PET-CT scanner (Siemens Medical Solutions, Knoxville, TN, USA) with an integrated PET and 16-multiple detector computed tomography (MDCT) scanner or a Discovery VCT PET/CT scanner (General Electric Healthcare, Waukesha, WI, USA) with an integrated PET and 64-MDCT scanner. Images were acquired from head to toe approximately 60 min following the intravenous (IV) administration of 160 MBq (4.32 mCi) of ¹⁸F-NaF. CT images were used for attenuation correction of PET images.

Measurements of NaF facet uptake and CT Pathria grade

Attenuation-corrected PET and CT images were transferred to a commercially available GE Advantage Workstation (version 4.5, General Electric Healthcare, Waukesha, WI, USA) for review and analysis. Standardized uptake value maximum (SUVmax) and mean standardized uptake value average (SUVavg) within the bilateral L3-L4, L4-L5, and L5-S1 facet joints were measured on PET images using a volumetric region of interest (ROI) encompassing the entire facet joint. Care was taken to exclude adjacent disc and nonfacet osseous structures from the ROI. Facet uptake was normalized relative to mean ¹⁸F-NaF uptake (SUVavg) in the mid femur, measured with an ROI placed on the normal appearing mid-femoral diaphysis, encompassing both the cortex and the marrow space. Facet and femur ROI determination was performed by SB, a radiologist with fellowship training in both nuclear medicine and abdominal imaging, and by MBR, a 5th year radiology resident. Facet arthropathy was graded on CT images at the same levels, using the Pathria classification (Grade 0-3) of facet osteoarthropathy.^[21] Briefly, Pathria Grade 0 = normal facet; Grade 1 = narrowing of facet joint; Grade 2 = joint space narrowing plus sclerosis or hypertrophy; and Grade 3 = severe osteoarthritis with narrowing, sclerosis, and osteophytes. This process generated data points for 180 facet joints with normalized SUVmax, SUVavg, and Pathria grade for each joint. Pathria grading was performed by JFT, a fellowship-trained neuroradiologist, and MBR, a 5th year radiology resident. Pathria graders were blinded to NaF PET results.

Statistical analysis

Statistical analysis was performed with R statistical software package (R Foundation for Statistical Computing, Vienna, Austria).^[22] The mean age, range, and standard deviation were calculated for the included patients. Spearman’s rank correlation was performed for normalized SUVmax with Pathria grade and for normalized SUVavg with Pathria grade to evaluate the degree of correlation of facet ¹⁸F-NaF uptake and facet morphologic abnormality. Data points were then separated, based on the Pathria grade. The mean, standard deviation, 95% confidence interval, range, and skew of the normalized SUVmax and normalized SUVavg were calculated for each Pathria grade. One-way analysis of variance (ANOVA) was then performed with Tukey-Kramer pairwise tests to evaluate statistically significant differences in SUVmax between the Pathria grades. One-way ANOVA was then performed with Tukey-Kramer pairwise tests to evaluate statistically significant differences in SUVavg between the Pathria grades. *P* < 0.05 was considered statistically significant.

Results

Patient characteristics and Pathria morphology grade

Patient characteristics are summarized in Table 1. Thirty patients (with age range 60-86 years, mean age 71 ± 7 years) with 180 analyzed facet joints were included in this study. Out of the 30 patients, 29 were males. The older male predominance in the patients results from the fact that NaF PET imaging at our institution is primarily used for restaging prostate cancer patients. None of the included patients had evidence of osseous metastatic disease, prior spinal instrumentation, or evidence of fracture involving the lumbar spine. Of the 180 facet joints analyzed, there were 16 Pathria Grade 0, 68 Pathria Grade 1 (mild), 49 Pathria Grade 2 (moderate), and 47 Pathria Grade 3 (severe) facet joints.

Correlation of facet Pathria morphologic grade and ¹⁸F-NaF uptake

Facet normalized SUVmax and Pathria grade demonstrated mild positive correlation (*r* = 0.31, *P* < 0.001). Facet normalized SUVavg and Pathria grade also demonstrated mild positive correlation (*r* = 0.28, *P* < 0.001). The correlation is depicted in Figure 1.

Table 1: Patient characteristics

Patient characteristics (n=30)	
Mean age (years)	71.47
Age range (years)	60-86
Age standard deviation (years)	7.67
Male: Female	29:1

Facet ¹⁸F-NaF uptake by Pathria morphologic grade

The mean, standard deviation, 95% confidence interval, range, and skew of normalized SUVmax for each Pathria grade are presented in Table 2. These results are depicted graphically in a box plot in Figure 2. The mean, standard deviation, 95% confidence interval, range, and skew of normalized SUVavg for each Pathria grade are presented in Table 2. These results are depicted graphically in a box plot in Figure 3. A wide range of normalized SUVmax and SUVavg was observed within each Pathria grade, with a positive skew reflecting the multiple high values encountered. The box plots [Figures 2 and 3]

Table 2: Facet NaF uptake values sorted by CT Pathria grade. Note the wide range of uptake values within each group and the positive skew demonstrating the presence of high uptake values within each Pathria subgroup. ANOVA with Tukey-Kramer pairwise comparisons only demonstrated statistically significant differences between the Pathria Group 3 SUVmax and SUVavg and the Pathria Group 0 and 1 SUVmax and SUVavg after post hoc correction

Normalized facet ¹⁸ F-NaF uptake by pathria grade				
Pathria grade	0 (n=16)	1 (n=68)	2 (n=49)	3 (n=47)
Mean SUVmax	4.92	5.99	7.10	9.01
(95% CI)	(4.27-5.57)	(5.33-6.66)	(5.70-8.50)	(7.45-10.57)
SUVmax range	3.21-7.20	2.33-16.31	2.87-30.40	3.33-30.38
SUVmax skew	+0.50	+1.39	+3.08	+1.83
Mean SUVavg	2.55	3.13	3.31	4.09
(95% CI*)	(2.21-2.89)	(2.85-3.40)	(2.81-3.81)	(3.60-4.58)
SUVavg range	1.88-3.93	1.44-7.38	1.48-9.20	1.77-9.82
SUVavg skew	+0.88	+1.00	+1.65	+1.22

*CI: Confidence interval; SUVmax: Standardized uptake value maximum; SUVavg: Standardized uptake value average, ANOVA: Analysis of variance

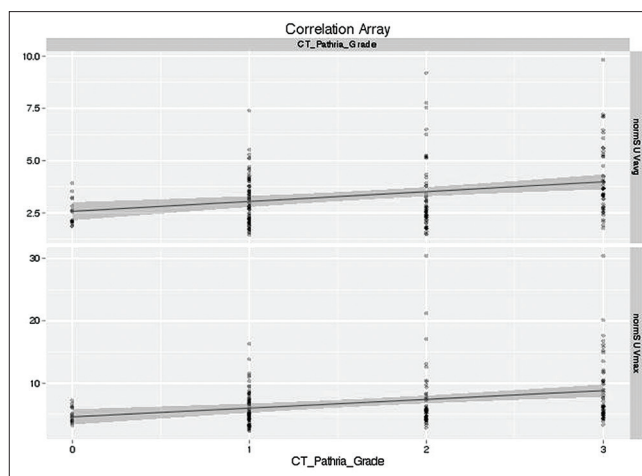


Figure 1: Correlation of facet normalized SUVavg (top) and facet normalized SUVmax (bottom) to CT Pathria grade. There was a mild positive correlation of CT Pathria grade to normalized SUVmax (*r* = 0.31, *P* < 0.001) and normalized SUVavg (*r* = 0.28, *P* < 0.001)

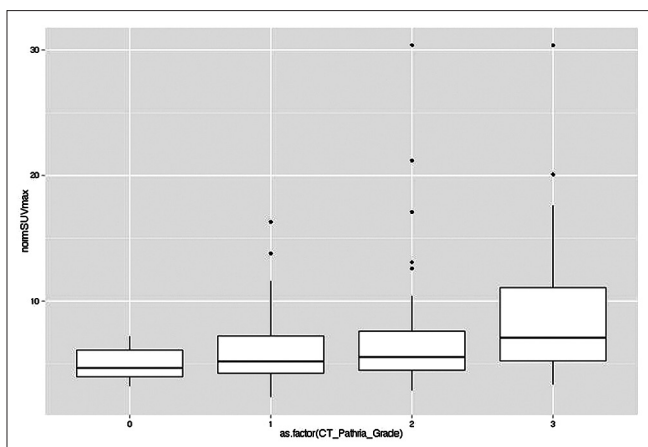


Figure 2: Box plot of normalized SUVmax by Pathria grade. The center of the box represents the mean, the horizontal line in the box represents the median, the box depicts the interquartile range, and the vertical lines extend to the less of the maximum value or 1.5 times the interquartile range. Dots represent points outside the interquartile range of 1.5 times

depict multiple high values within Pathria Groups 1, 2, and 3 that are greater than 1.5 times the interquartile range (represented as points).

ANOVA of normalized SUVmax by Pathria grade (F -statistics = 6.53, $P < 0.001$) with Tukey-Kramer pairwise tests yielded statistically significant differences in normalized SUVmax when comparing Pathria Grade 3 facet joints to Pathria Grade 0 ($P < 0.001$), Pathria Grade 1 ($P < 0.001$), and Pathria Grade 2 ($P = 0.02$) facet joints. None of the pairwise comparisons between Pathria Grades 0, 1, and 2 were statistically significant.

ANOVA of normalized SUVavg by Pathria grade (F -statistic = 6.24, $P < 0.001$) with Tukey-Kramer pairwise tests yielded statistically significant differences in normalized SUVavg when comparing Pathria Grade 3 facet joints with Pathria Grade 0 ($P < 0.001$), Pathria Grade 1 ($P < 0.001$), and Pathria Grade 2 ($P = 0.009$) facet joints. None of the pairwise comparisons between Pathria Grades 0, 1, and 2 were statistically significant.

Discussion

We have retrospectively evaluated whether increased ¹⁸F-NaF (NaF) PET uptake in lumbar facet joints correlates to structural changes of the joint as evaluated with the Pathria morphologic CT-grading scale on hybrid PET-CT exams. First, we established a successful method for measuring normalized NaF uptake volumetrically within the facet joint. Using this technique, we have identified a weak positive correlation between NaF uptake and Pathria CT morphologic grade of facet arthropathy. Within each Pathria grade

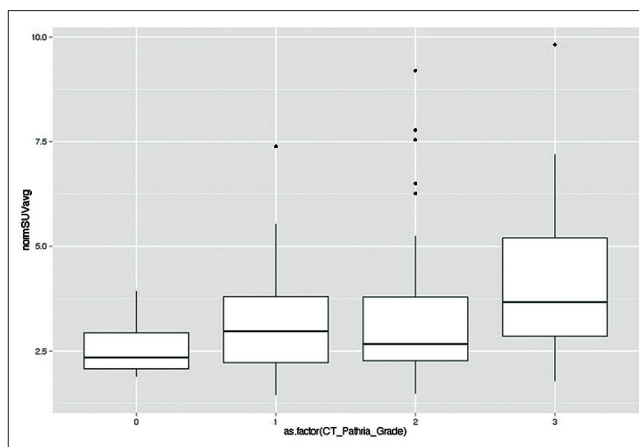


Figure 3: Box plot of normalized SUVavg by Pathria grade. The center of the box represents the mean, the horizontal line in the box represents the median, the box depicts the interquartile range, and the vertical lines extend to the less of the maximum value or 1.5 times the interquartile range. Dots represent points outside of the interquartile range of 1.5 times

subgroup, we observed a wide range of NaF uptake values with positive skew. While facet osteoarthritis, as evidenced on CT, often corresponded to joints with elevated tracer uptake, we did observe increased NaF uptake in the absence of gross structural abnormalities of the facet joints [Figure 4]. Moreover, some facet joints with advanced morphologic grades on CT had normal or minimally elevated tracer uptake [Figure 4]. Overall, these data suggest that NaF uptake reflects metabolic changes within the skeletal portion of the joint that are not consistently reflected on CT. Given the known physiologic mechanisms underlying NaF uptake in bone, along with the present results, present data suggest that future prospective studies are warranted to determine if NaF complements standard imaging modalities for lower back pain by identifying pain-generating facet joints, as information provided with NaF may not be entirely redundant with that obtained from morphologic classification with conventional techniques.

Facet arthropathy has increasingly been identified as a significant source of back pain.^[1-3] However, identifying the pain-generating facet joint is limited by the overlapping dermatomal representation of zygapophysial joints at adjacent levels as well as numerous distinct anatomic sites in the surrounding spine and paraspinal tissues.^[1,6,7] Clinical identification of relevant pain generators in the lower back may require a laborious and expensive trial and error process including invasive or minimally invasive techniques such as intra-articular facet blocks or medial branch nerve blocks.^[1,6,7] Ideally, noninvasive imaging techniques would reliably demonstrate facet joints that are pain generators; however, morphologic criteria using radiographic and standard MRI techniques

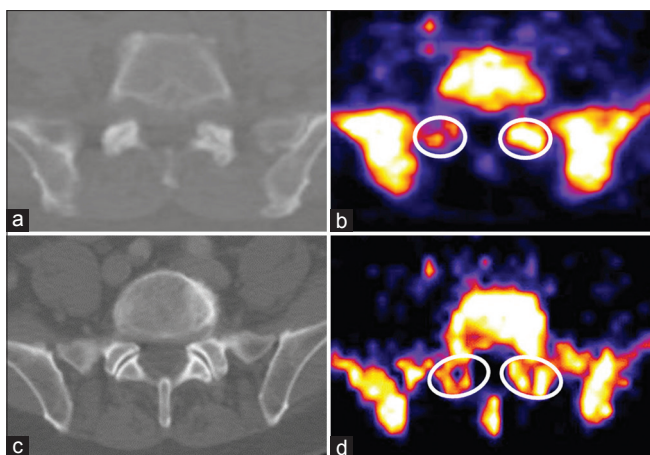


Figure 4: Discrepant results between CT Pathria grade of facet arthropathy and NaF PET uptake with hybrid PET-CT imaging.

(a) Axial CT demonstrates symmetric bilateral L5-S1 facet arthropathy with joint space narrowing and facet sclerosis consistent with Pathria Grade 2 osteoarthritis (b) Axial NaF PET image at the same level in the same patient shows discrepant tracer uptake with asymmetric increased signal in the left L5-S1 joint compared with the right (c) Axial CT in a different patient demonstrates symmetric bilateral normal morphologic appearance of the L5-S1 facet joints (Pathria Grade 0), whereas the corresponding NaF PET at the same level for this patient (d) shows asymmetric increased uptake in the left L5-S1 facet joint. White circles in B and D approximate the ROI utilized for NaF SUV uptake measurements. NaF PET images (b and d) are pseudocolored using a “fire” lookup table

alone have proved insufficiently sensitive to changes underlying the active sites of pain.^[6,7] Physiologic bone imaging may provide additional information that proves to be clinically relevant in facet-related pain management. NaF uptake identifies areas of active bone remodeling while morphologic changes identified on CT represent the downstream effects of chronic stress and remodeling.^[4,5,15,16] In light of the pathophysiologic mechanisms underlying facet arthropathy and the wide range of observed NaF facet uptake demonstrated herein, the present data suggest that tracer uptake may correlate to active degenerative facet pathology. In some cases, NaF uptake may precede more advanced morphologic abnormalities. Patients with minimal morphologic abnormalities in the facet joints on CT but high NaF uptake are likely to have abnormal stress, remodeling, and hyperemia at affected facet joints. Present data build upon the very limited literature, evaluating the role of NaF PET-CT in facet arthropathy.^[18-20] Future studies aimed at exploring whether facet NaF uptake can accurately identify sites of pain generation and the sites that will respond to minimally invasive techniques such as intra-articular facet blocks, medial branch blocks, and ablative procedures are underway.

This initial study should be considered a pilot for NaF PET-CT hybrid imaging of the facet joints, aiming to stimulate future efforts to investigate its role in facet syndrome and back pain in general. The study has

several limitations. This is an observational retrospective study with a relatively small patient size. Moreover, because NaF PET-CT clinical applications are presently largely limited to cancer staging, our cohort primarily comprised older male patients with nonmetastatic prostate cancer and this introduced potential biases. Also, clinical records regarding symptoms of lower back pain were not available for this patient population and thus, imaging findings were not correlated to clinical symptomatology. Nonetheless, the targeted goal of this study was purely to investigate the relationship of CT structural abnormality at the facet joints with NaF uptake using hybrid PET-CT imaging, and to this end present data are revealing. Pursuing prospective studies with radioactive PET tracers for the diagnosis of facet syndrome must be considered carefully as radiation exposure associated with diagnostic imaging has become an increasingly important consideration for clinical decision-making. By demonstrating that NaF-PET and CT data are not redundant modalities with respect to the state of the facet joint, present data help validate future prospective studies utilizing NaF-PET to investigate the potential complementary role of this modality in patients with facet syndrome. Such prospective studies in a more diverse lower back pain population are needed to evaluate the relationship of NaF uptake to pain metrics and guidance of pain interventions.

To summarize, we have developed a method for volumetrically measuring normalized NaF uptake within the lumbar facet joint and have identified a wide range of NaF uptake values within each CT Pathria grade with an overall mild positive correlation between Pathria grade and NaF uptake values. Our data suggest that while NaF radiopharmaceutical uptake and morphologic changes of the facet joint are weakly correlated, physiologic information afforded by NaF uptake is often discrepant with structural findings on CT. Thus, NaF PET may supplement conventional structural imaging for identification of pain-generating facet joints. Present data support moving ahead with further prospective investigation to clarify the relationship between facet joint NaF uptake with facetogenic pain and response to pain interventions.

Acknowledgment

MCM and MBR contributed equally to this manuscript and are considered co-first authors. MCM was supported by an NIH T32 training grant (5T32EB001631-10).

References

1. Cohen SP, Raja SN. Pathogenesis, diagnosis, and treatment of lumbar zygapophysial (facet) joint pain. *Anesthesiology* 2007;106:591-614.

2. Suri P, Hunter DJ, Rainville J, Guermazi A, Katz JN. Presence and extent of severe facet joint osteoarthritis are associated with back pain in older adults. *Osteoarthritis Cartilage* 2013;21:1199-206.
3. Suri P, Dharamsi AS, Gaviola G, Isaac Z. Are facet joint bone marrow lesions and other facet joint features associated with low back pain? A pilot study. *PM R* 2013;5:194-200.
4. Eisenstein SM, Parry CR. The lumbar facet arthrosis syndrome. Clinical presentation and articular surface changes. *J Bone Joint Surg Br* 1987;69:3-7.
5. Gellhorn AC, Katz JN, Suri P. Osteoarthritis of the spine: The facet joints. *Nat Rev Rheumatol* 2013;9:216-24.
6. Revel ME, Listrat VM, Chevalier XJ, Dougados M, N'Guyen MP, Vallee C, *et al.* Facet joint block for low back pain: Identifying predictors of a good response. *Arch Phys Med Rehabil* 1992;73:824-8.
7. Jackson RP, Jacobs RR, Montesano PX. 1988 Volvo award in clinical sciences. Facet joint injection in low-back pain. A prospective statistical study. *Spine (Phila Pa 1976)* 1988;13:966-71.
8. Naslund JE, Odenbring S, Naslund UB, Lundberg T. Diffusely increased bone scintigraphic uptake in patellofemoral pain syndrome. *Br J Sports Med* 2005;39:162-5.
9. McCrae F, Shouls J, Dieppe P, Watt I. Scintigraphic assessment of osteoarthritis of the knee joint. *Ann Rheum Dis* 1992;51:938-42.
10. McDonald M, Cooper R, Wang MY. Use of computed tomography-single-photon emission computed tomography fusion for diagnosing painful facet arthropathy. Technical note. *Neurosurg Focus* 2007;22:E2.
11. Kanmaz B, Collier BD, Liu Y, Uzum F, Uygur G, Akansel G, *et al.* SPET and three-phase planar bone scintigraphy in adult patients with chronic low back pain. *Nucl Med Commun* 1998;19:13-21.
12. Ryan RJ, Gibson T, Fogelman I. The identification of spinal pathology in chronic low back pain using single photon emission computed tomography. *Nucl Med Commun* 1992;13:497-502.
13. Ryan PJ, Evans PA, Gibson T, Fogelman I. Chronic low back pain: Comparison of bone SPECT with radiography and CT. *Radiology* 1992;182:849-54.
14. Ryan PJ, Evans P, Gibson T, Fogelman I. Osteoporosis and chronic back pain: A study with single-photon emission computed tomography bone scintigraphy. *J Bone Miner Res* 1992;7:1455-60.
15. Grant FD, Fahey FH, Packard AB, Davis RT, Alavi A, Treves ST. Skeletal PET with ¹⁸F-fluoride: Applying new technology to an old tracer. *J Nucl Med* 2008;49:68-78.
16. Blau M, Ganatra R, Bender MA. ¹⁸F-fluoride for bone imaging. *Semin Nucl Med* 1972;2:31-7.
17. Strobel K, Fischer DR, Tamborrini G, Kyburz D, Stumpe KD, Hesselmann RG, *et al.* ¹⁸F-fluoride PET/CT for detection of sacroiliitis in ankylosing spondylitis. *Eur J Nucl Med Mol Imaging* 2010;37:1760-5.
18. Lim R, Fahey FH, Drubach LA, Connolly LP, Treves ST. Early experience with fluorine-18 sodium fluoride bone PET in young patients with back pain. *J Pediatr Orthop* 2007;27:277-82.
19. Ovadia D, Metser U, Lievshitz G, Yaniv M, Wientroub S, Even-Sapir E. Back pain in adolescents: Assessment with integrated ¹⁸F-fluoride positron-emission tomography-computed tomography. *J Pediatr Orthop* 2007;27:90-3.
20. Gamie S, El-Maghraby T. The role of PET/CT in evaluation of Facet and Disc abnormalities in patients with low back pain using (18) F-Fluoride. *Nucl Med Rev Cent East Eur* 2008;11:17-21.
21. Pathria M, Sartoris DJ, Resnick D. Osteoarthritis of the facet joints: Accuracy of oblique radiographic assessment. *Radiology* 1987;164:227-30.
22. Team RC. R: A language and Environment for Statistical Computing. Vienna, Austria: R Foundation for Statistical Computing; 2014.

How to cite this article: Mabray MC, Brus-Ramer M, Behr SC, Pampaloni MH, Majumdar S, Dillon WP, *et al.* ¹⁸F-sodium fluoride PET-CT hybrid imaging of the lumbar facet joints: Tracer uptake and degree of correlation to CT-graded arthropathy. *World J Nucl Med* 2016;15:85-90.

Source of Support: Nil. **Conflict of Interest:** None declared.