

Case report

Unusual Dipyridamole-induced Aberrant Conduction in the Absence of Myocardial Ischemia

Roberto Ricca-Mallada^{1,2}, Federico Ferrando-Castagnetto^{1,3}, Rodolfo Ferrando³, Fernando Mut²

¹Department of Cardiology, University Cardiovascular Center, Clinical Hospital, School of Medicine, Republic University,

²Department of Nuclear Medicine, Asociación Española Primera de Socorros Mutuos, ³Department of Nuclear Medicine, Centro Asistencial del Sindicato Médico, Montevideo, Uruguay

Abstract

We report two patients referred to 2 day stress-rest single photon emission computed tomography for diagnosis of ischemia who elicited a transient left bundle branch block during dipyridamole intravenous infusion. The conduction disturbance disappeared after aminophylline infusion and became permanent during follow-up. Possible mechanisms underlying this unusual phenomenon in the absence of myocardial ischemia are discussed.

Keywords: Dipyridamole, single photon emission computed tomography, transient left bundle branch block

Introduction

Vasodilators as adenosine and dipyridamole are useful and safe alternatives to exercise stress during the evaluation of coronary artery disease by myocardial perfusion single photon emission computed tomography (SPECT).^[1]

Vascular smooth muscle and endothelial cells produce endogenous adenosine during spontaneous or induced myocardial ischemia, binding primarily to A₂ membrane receptors. Net result is a coronary vasodilation mediated by adenylate cyclase.

Dipyridamole indirectly produces vasodilation by inhibiting the reuptake of endogenous adenosine into platelets, erythrocytes, and endothelial cells; the resulting increased extracellular concentration of adenosine stimulates coronary vasodilation.^[2] While

electrophysiologic effects of adenosine and dipyridamole at the atrial and atrioventricular (AV) node have been fully demonstrated, their effects on His-Purkinje conduction have not been reported.^[3,4]

We describe two patients exhibiting intermittent left bundle branch block (LBBB) during dipyridamole intravenous infusion. At 1 year of follow-up, both patients developed permanent LBBB.

Case Reports

Case 1

A 54-year-old hypertensive, diabetic, hyperuricemic, and dyslipidemic female patient was referred to Tc-99m 2 methoxy-isobutyl-isonitrile (99mTc-MIBI) gated-SPECT with pharmacologic stress to evaluate induced ischemia. She presented a 4-month history of nonanginal chest pain, sometimes superimposed to functional class II (NYHA) dyspnea. She was on

Address for correspondence:

Dr. Roberto Ricca-Mallada, Department of Cardiology, University Cardiovascular Center, Clinical Hospital, Avda. Italia s/n Zip Code 11600, Montevideo, Uruguay.
E-mail: cardiofisiologia@gmail.com

Access this article online

Quick Response Code:



Website:
www.wjnm.org

DOI:
10.4103/1450-1147.207281

This is an open access article distributed under the terms of the Creative Commons Attribution-NonCommercial-ShareAlike 3.0 License, which allows others to remix, tweak, and build upon the work non-commercially, as long as the author is credited and the new creations are licensed under the identical terms.

For reprints contact: reprints@medknow.com

How to cite this article: Ricca-Mallada R, Ferrando-Castagnetto F, Ferrando R, Mut F. Unusual dipyridamole-induced aberrant conduction in the absence of myocardial ischemia. World J Nucl Med 2017;16:243-6.

standard-dose aspirin, atorvastatin, allopurinol, thiazides, and enalapril, discontinuing atenolol 48 h before the stress test. A 2-day stress-rest SPECT protocol was performed. The recommendations of the European Association of Nuclear Medicine were followed for preparation, image acquisition, and processing.^[5] After 0.56 mg/kg dipyridamole infusion and MIBI injection (8 minutes after starting the protocol), the patient installed a transient LBBB without changes in the heart rate (85 bpm) [Figure 1a and b]. The conduction disturbance disappeared after aminophylline infusion (2-min later MIBI infusion). Poststress gated-SPECT images revealed no perfusion defects [Figure 1c-e]. Resting and poststress cavity volumes and left ventricular ejection fraction (LVEF) were within normal limits. During 1 year of follow-up, she remained free of other symptoms, but she developed permanent LBBB.

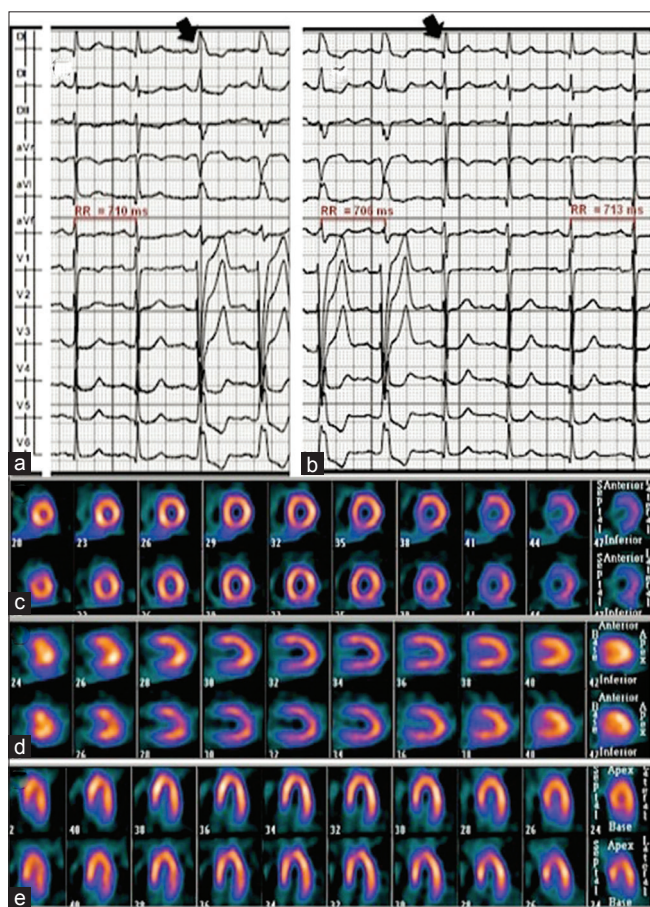


Figure 1: Electrocardiography tracings obtained during dipyridamole infusion (a) and after endovenous aminophylline (b). The appearance and disappearance of left bundle branch block occurring at a sinus rate of 85 bpm (RR interval: 710 ms) are indicated by black arrows. Atrioventricular conduction remained unchanged in both conditions. Note intermittent left bundle branch block. Poststress and resting gated-single photon emission computed tomography images during 2 days stress-test protocol in short (c), long vertical (d) and long horizontal axis (e) showed no myocardial perfusion defects

Case 2

A 71-year-old female patient, obese, hypertensive, dyslipidemia, sedentary, with a history of anginal chest pain in the last year, was referred to pharmacological stress ^{99m}Tc -MIBI gated-SPECT to detect coronary heart disease. She was on aspirin, enalapril, and clonazepam. We followed the same protocol as in Case 1. Early after dipyridamole infusion, she presented mild chest pain and installed a transient LBBB without changes in the heart rate (68 bpm) [Figure 2a]. With aminophylline infusion, normal ventricular conduction was restored. Poststress images revealed homogeneous myocardial perfusion [Figure 2b-d]; resting and poststress cavity volumes and LVEF were also normal. After this, the attending physician added atenolol 50 mg/day. During 1-year of follow-up, the patient not required hospitalization or other diagnostic procedures, but she developed permanent LBBB.

Discussion

Both adenosine and dipyridamole are usually associated with mild reversible adverse effects and very low frequency of severe complications such as sustained ventricular arrhythmias (0.81 per 10,000), death from myocardial infarction (MI), or nonfatal MI (<0.1%).^[6,7] The P-R interval prolongation had an incidence of 2-7% during vasodilator myocardial perfusion SPECT and is usually reversed through selective adenosine competitive antagonism produced by endovenous aminophylline.^[7] In turn, advanced AV block induced by dipyridamole is very rare.^[8]

Both in Cases 1 and 2, the RR intervals did not shorten progressively before the development of LBBB. So, tachycardia-dependent (phase 3) aberrancy in response to vasodilation was ruled out as a possible diagnosis. Furthermore, SPECT images showed no perfusion defects that could explain ischemic-induced conduction abnormalities. These findings, associated with the reversibility of QRS changes after aminophylline administration, suggests that the aberrant conduction was the effect of exogenous dipyridamole. To the best of our knowledge, this is the first report of nonrate-dependent LBBB induced by dipyridamole infusion. However, it seems quite difficult to find a rationale for this uncommon physiological effect in the described clinical settings. First, both cases showed the absence of clinical, electrocardiographic (ECG) or imaging findings suggestive of myocardial ischemia in the anterior descending coronary artery territory. Second, large case series has not described sustained changes on ventricular conduction induced by dipyridamole; this fact is clinically relevant due to the potential influence of this phenomenon on image interpretation. Finally and most importantly, experimental research in animal models repeatedly failed to demonstrate alterations of

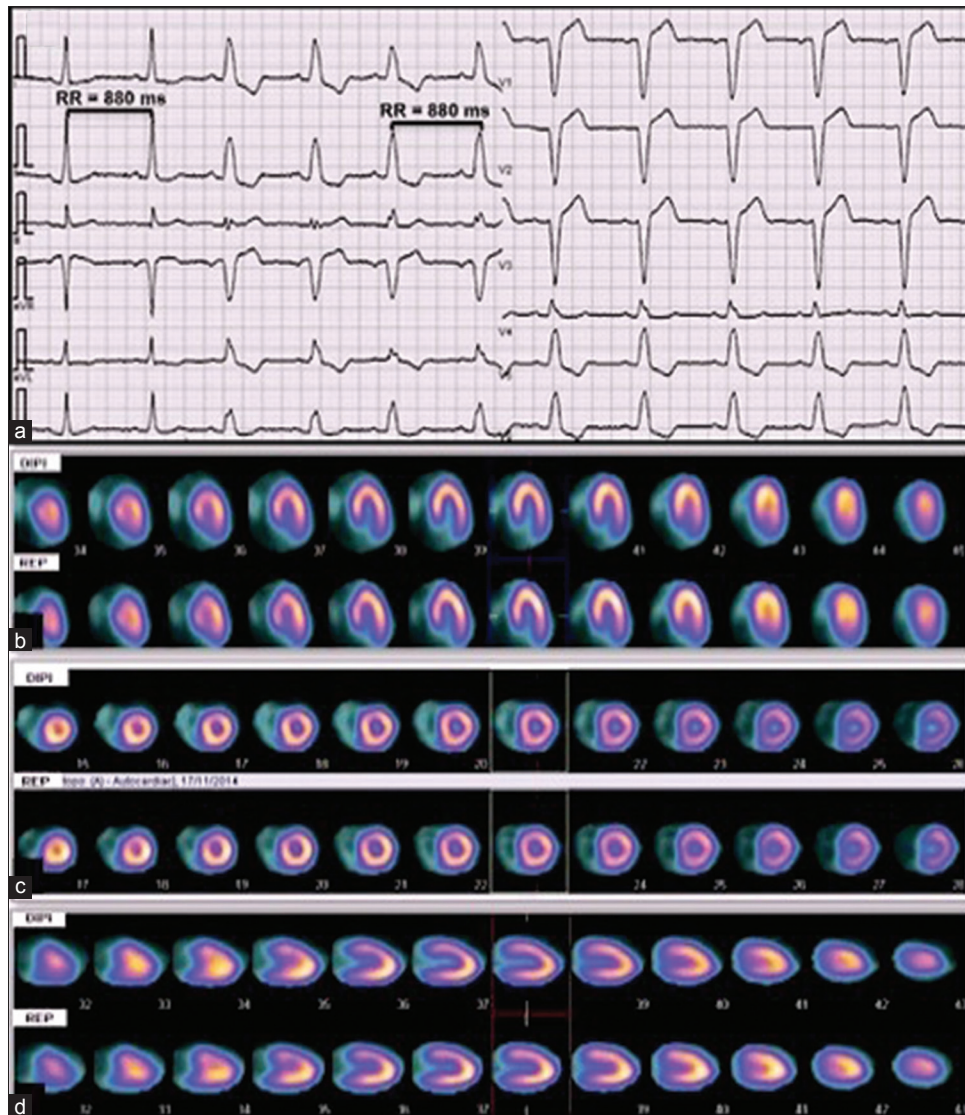


Figure 2: (a) Development of left bundle branch block during dipyridamole infusion without previous modifications in heart rate (see similar RR intervals before and after left bundle branch block morphology). Poststress and resting gated-single photon emission computed tomography images during 2 days stress-test protocol in short (b), long vertical (c) and long horizontal axis (d) showed no perfusion defects

His-Purkinje conduction time induced by endogenous adenosine release. In fact, although elevated adenosine levels may account for a major proportion of reversible AV conduction delay associated with impaired blood supply to the AV node,^[8,9] bundle branch conduction times were not significantly altered.

Nunain *et al.*^[10] found that therapeutic doses of adenosine (6 mg and 12 mg bolus) shortened the atrial but not the ventricular duration of the monophasic action potential in 19 patients undergoing routine diagnostic electrophysiology studies. Bubinski *et al.*^[4] specifically evaluated the physiological effects of endovenous dipyridamole in 24 patients during intracardiac electrophysiological studies, measuring parameters before and 5 min following infusion of dipyridamole (dose: 0.5 mg/kg). These investigators

found that dipyridamole increased sinus node automaticity and reduced atrial, atrioventricular nodal, and ventricular refractory periods, and prolonged intra-atrial and atrioventricular nodal conduction but did not produce significant modifications in His-Purkinje conduction times. However, some patients may have anatomical features that make them vulnerable to LBBB. In this way, both patients developed a permanent LBBB in the 1-year follow-up.

Adenosine may not directly affect ventricular myocytes although it exerts pronounced anti- β -adrenergic effects in the myocardium mediated by A1A receptors and reducing intracellular levels of cAMP. Adenosine attenuates the catecholamine-dependent increase in inward L-type Ca^{2+} current (ICaL), the delayed rectifier potassium current, and chloride current (ICl).

In addition, adenosine attenuates I_{CaL} and transient inward current (I_{ti})-dependent afterdepolarization and triggered activity.^[8]

In our two-cases experience, this unusual and nonsustained aberrant conduction during myocardial perfusion SPECT did not alter the safety of vasodilator stress protocol. Furthermore, although LBBB is a known cause of septal artifacts frequently resembling a true perfusion defect, none of our patients exhibited this finding, possibly due to the short duration of the conduction disturbance. We believe that the transient development of LBBB during dipyridamole infusion may predict the development of permanent LBBB.

Financial support and sponsorship

Nil.

Conflicts of interest

There are no conflicts of interest.

References

- Zaret BL, Beller GA. Clinical Nuclear Cardiology: State of the Art and Future Directions. 3rd ed. Philadelphia: Elsevier Mosby; 2005. p. 233-53.
- Feldman RL, Nichols WW, Pepine CJ, Conti CR. Acute effect of intravenous dipyridamole on regional coronary hemodynamics and metabolism. *Circulation* 1981;64:333-44.
- Kabell G, Buchanan LV, Gibson JK, Belardinelli L. Effects of adenosine on atrial refractoriness and arrhythmias. *Cardiovasc Res* 1994;28:1385-9.
- Bubinski R, Markiewicz K, Cholewa M, Górski L, Gawor Z, Kus W. Electrophysiologic effects of intravenous dipyridamole. *Int J Cardiol* 1989;24:327-35.
- Hesse B, Tägil K, Cuocolo A, Anagnostopoulos C, Bardiés M, Bax J, *et al.* EANM/ESC procedural guidelines for myocardial perfusion imaging in nuclear cardiology. *Eur J Nucl Med Mol Imaging* 2005;32:855-97.
- Lette J, Tatum JL, Fraser S, Douglas Miller D, Waters DD, Heller G, *et al.* Safety of dipyridamole testing in 73,806 patients: The multicenter dipyridamole safety study. *J Nucl Cardiol* 1999;1:3-17.
- Cerqueira MD, Verani MS, Schwaiger M, Heo J, Iskandrian AS. Safety profile of adenosine stress perfusion imaging: Results from the Adenoscan Multicenter Trial Registry. *J Am Coll Cardiol* 1994;23:384-9.
- Mustafa SJ, Morrison RR, Teng B, Pelleg A. Adenosine receptors and the heart: Role in regulation of coronary blood flow and cardiac electrophysiology. *Handb Exp Pharmacol* 2009;193:161-88.
- Belardinelli L, Mattos EC, Berne RM. Evidence for adenosine mediation of atrioventricular block in the ischemic canine myocardium. *J Clin Invest* 1981;68:195-205.
- Nunain SO, Garratt C, Paul V, Debbas N, Ward DE, Camm AJ. Effect of intravenous adenosine on human atrial and ventricular repolarisation. *Cardiovasc Res* 1992;26:939-43.