

Original article

Prostate-Specific Antigen and Prostate-Specific Antigen Kinetics in Predicting ^{18}F -Sodium Fluoride Positron Emission Tomography-Computed Tomography Positivity for First Bone Metastases in Patients with Biochemical Recurrence after Radical Prostatectomy

James Yoon, Leslie Ballas¹, Bhushan Desai, Hossein Jadvar

Departments of Radiology and ¹Radiation Oncology, Keck School of Medicine, University of Southern California, Los Angeles, CA, USA

Abstract

We evaluated the association between serum prostate specific antigen (PSA) level and kinetics to predict ^{18}F -sodium fluoride positron emission tomography-computed tomography (^{18}F -NaF PET-CT) positivity for first bone metastases in men with biochemical recurrence after radical prostatectomy. All ^{18}F -NaF PET-CT scans that were performed at our institution during 2010–2014 were queried to find patients who demonstrated biochemical recurrence after radical prostatectomy. Records were reviewed to obtain data on PSA levels and kinetics at the time of ^{18}F -NaF PET-CT and pathologic features of the prostatectomy specimen, which were then used for receiver operating characteristic (ROC) analysis to determine predictability for ^{18}F -NaF PET positivity. Thirty-six patients met our inclusion criteria. Of these, 8 (22.2%) had positive ^{18}F -NaF PET-CT scans. Mean values for PSA, PSA doubling time (PSADT), and PSA velocity (PSAV) were 2.02 ng/ml (range: 0.06–11.7 ng/ml), 13.2 months (range: 1.11–60.84), and 1.28 ng/ml/year (range: 0.1–5.28) for ^{18}F -NaF PET-CT negative scans, and 4.11 ng/ml (range: 0.04–14.38 ng/ml), 8.9 months (range: 0.7–27.8), and 9.06 ng/ml/year (range: 0.04–50.2) for ^{18}F -NaF PET-CT positive scans, respectively ($P = 0.07, 0.47, \text{ and } 0.02$, respectively, for PSA, PSADT, and PSAV). ROC analysis for ^{18}F -NaF PET-CT positivity resulted in area under the curve (AUC) values of 0.634 for PSA, 0.598 for PSADT, and 0.688 for PSAV. ROC analysis with combined models gave AUC values of 0.723 for a combination of PSA and PSADT, 0.689 for a combination of PSA and PSAV, and 0.718 for grouping of PSA, PSADT, and PSAV. There was no significant association between ^{18}F -NaF PET-CT positivity and primary tumor Gleason score, TN staging, and status of surgical margins. ^{18}F -NaF PET-CT detected first-time osseous metastases in 22.2% of our patients with biochemical recurrence after prostatectomy with the PSA level range ≤ 11.7 ng/ml. PSAV was statistically significant in predicting ^{18}F -NaF PET-CT positivity. ROC analysis demonstrated higher AUCs when PSA was combined with PSA kinetics parameters.

Keywords: ^{18}F -sodium fluoride, cancer, positron emission tomography, prostate, prostate-specific antigen

Address for correspondence:

Dr. Hossein Jadvar, Department of Radiology, University of Southern California, 2250 Alcazar Street, CSC 102, Los Angeles, CA 91107, USA.
E-mail: jadvar@med.usc.edu

Access this article online

Quick Response Code:



Website:
www.wjnm.org

DOI:
10.4103/1450-1147.207286

This is an open access article distributed under the terms of the Creative Commons Attribution-NonCommercial-ShareAlike 3.0 License, which allows others to remix, tweak, and build upon the work non-commercially, as long as the author is credited and the new creations are licensed under the identical terms.

For reprints contact: reprints@medknow.com

How to cite this article: Yoon J, Ballas L, Desai B, Jadvar H. Prostate-specific antigen and prostate-specific antigen kinetics in predicting ^{18}F -sodium fluoride positron emission tomography-computed tomography positivity for first bone metastases in patients with biochemical recurrence after radical prostatectomy. World J Nucl Med 2017;16:229-36.

Introduction

Prostate cancer continues to be the most common cancer and the second leading cause of cancer death in men in the United States. Bone is the primary site for prostate cancer metastases.^[1] About 15% of patients who are treated for primary prostate carcinoma with radical prostatectomy develop biochemical recurrence with median actuarial time to metastases of 8 years from the time of prostate-specific antigen (PSA) level elevation.^[2] In postprostatectomy patients, biochemical recurrence is defined by serum PSA value >0.2 ng/ml confirmed by 2 consecutive measurements.^[3] An elevated or rising PSA trend is often the first indicator of local recurrence and/or metastases. Treatment option for patients with biochemical recurrence hinges on detection and localization of sites of disease. Patients with local recurrence in the prostatectomy surgical bed may be candidates for salvage local therapy, while those men with metastatic disease may receive systemic treatment.

Imaging evaluation plays an important role in this clinical setting. Conventional imaging includes contrast-enhanced computed tomography (CT) of the chest, abdomen, and pelvis; ^{99m}Tc-based bone scintigraphy (BS); and increasingly multiparametric magnetic resonance imaging (mMRI) of the pelvis. However, these imaging studies may be insufficient in detecting lesions with adequate sensitivity and specificity.^[4] This has stimulated the investigation of other imaging modalities including hybrid positron emission tomography-CT (PET-CT) with a variety of biologically relevant radiotracers in prostate cancer.^[5] The most common PET radiotracer is ¹⁸F-fluorodeoxyglucose (FDG) that tracks glucose metabolism in tumors. However, FDG PET-CT is useful in only a small fraction of patients with biochemical recurrence.^[6] The role of other PET radiotracers such as those targeted to the gastrin-releasing peptide receptor, prostate-specific membrane antigen, and androgen receptor need further investigation. Radiotracers targeted to lipogenesis pathway (e.g., ¹¹C-acetate, ¹⁸F- or ¹¹C-choline) can be useful in this clinical setting with a diagnostic performance that depends on serum PSA level and kinetics.^[7-14] These studies have largely been limited to Europe, with limited availability in the United States despite Food and Drug Administration (FDA) approval for ¹¹C-choline for the imaging evaluation of biochemical recurrence. The use of ¹¹C-choline is, however, restricted in that it has a 20 min half-life, necessitating the presence of an on-site cyclotron and a strict chain of delivery from radiochemical synthesis to injection and imaging. More recently, the FDA approved the amino acid radiotracer, ¹⁸F-anti-1-amino-3-¹⁸F-fluorocyclobutyl-1-carboxylic acid (¹⁸F-Fluciclovine) for the imaging evaluation of men with biochemical recurrence after prostatectomy.^[15] However, the clinical adoption and other important issues

such as availability, accessibility, and reimbursement will take some time to evolve.

There has been renewed interest in ¹⁸F-sodium fluoride (¹⁸F-NaF) as a PET radiotracer for detection of osseous metastases. ¹⁸F-NaF has favorable properties as a radiotracer for bone imaging; it accumulates in bone rapidly and clears quickly from the circulation, allowing for a high bone-to-background uptake ratio within a short time. PET-CT also allows for high spatial resolution and quantitation. Studies investigating ¹⁸F-NaF PET to detect osseous metastasis have demonstrated a significant competitive advantage over ^{99m}Tc-based BS (planar and single-photon emission CT) in identifying osseous metastases in prostate cancer that impacts management.^[16-19] A major bolstering in the use of ¹⁸F-NaF PET was when the United States Centers for Medicare and Medicaid Services (CMS) announced on February 7, 2011, to reimburse for ¹⁸F-NaF PET through the coverage with evidence development (CED) program managed by the National Oncologic PET Registry (NOPR) to assess the effect of ¹⁸F-NaF PET on referring physicians' intended management of patients with known or suspected bone metastases.^[20] However, later on, December 15, 2015, the CMS issued another decision memorandum stating that there was insufficient evidence to allow for ¹⁸F-NaF PET reimbursement and recommended further continuation of CED through the NOPR for another 24 months.^[21]

The National Comprehensive Cancer Network Guidelines state that bone scans and CT may be considered in patients when PSA fails to fall to undetectable levels or when serum PSA increases to detectable levels on 2 or more subsequent determinations, though ^{99m}Tc-based BS is rarely positive in asymptomatic patients with PSA <10 ng/ml.^[22] Gomez *et al.* found that BS was unlikely to be positive in patients with a serum PSA of <7 ng/ml with biochemical recurrence after radical prostatectomy, whereas a PSA of ≥20 ng/ml was typically associated with suspicious positive findings on BS.^[23] The aim of this study was to determine the serum PSA level and kinetics, in addition to other clinical and pathologic factors, that may be predictive of ¹⁸F-NaF PET-CT positivity for first bone metastases in men with biochemical recurrence after radical prostatectomy.

Patients and Methods

As a part of this Institutional Review Board-approved study, all ¹⁸F-NaF PET-CT scans that were performed at our institution between 2010 and 2014 were retrospectively queried to find patients who had undergone radical prostatectomy with biochemical recurrence. We excluded patients who had known metastatic disease, based on conventional imaging, at the time of ¹⁸F-NaF PET-CT to obtain a cohort of 36 patients (mean age: 68.5;

range: 51.0–83.4 years) for whom ¹⁸F-NaF PET-CT was being explored to determine first osseous metastases.

Patients underwent ¹⁸F-NaF (mean 10.5 mCi, 388.5 MBq) PET-CT scans. Each hybrid PET-CT (Biograph Duo LSO; Siemens, Erlangen, Germany) was performed 1 h after intravenous (IV) administration of the radiotracer. Low-dose helical CT transmission scan (pitch 0.8, 50 mAs, 120 kVp) was performed first. No oral or IV contrast material was used. PET was then performed with 3 min per bed position from the top of the head to the feet. Raw CT data were reconstructed into 5 mm thick section of transverse images, and reformatted sagittal and coronal CT images were generated. CT-based attenuation-corrected PET images were reconstructed and viewed on a high-resolution colored monitor. PET and CT images could be viewed on a continuous fusion scale from PET only to CT only images using image fusion software (E-soft; Siemens).

The electronic medical records of the patients were reviewed to obtain information on serum PSA level at the time of ¹⁸F-NaF PET-CT, additional PSA values necessary for the calculation of PSA kinetics, pathologic features of the prostatectomy specimen, and other follow-up radiologic studies performed to corroborate the ¹⁸F-NaF PET-CT findings. ¹⁸F-NaF PET-CT interpretations included only those positive (higher than normal bone background activity) findings that did not represent physiologic or benign conditions taking into account the findings on the concurrent CT. The timing of PET-CT in relation to PSA level and any treatment after scan results were at the discretion of the treating physician and the patient. PET-CT scans were interpreted by experienced nuclear medicine radiologists who were not blinded to patients' demographics, laboratory, radiologic, or pathologic results.

The calculation of PSA doubling time (PSADT) incorporated all detectable PSA values measured within 1 year prior to the ¹⁸F-NaF PET-CT to 30 days after the ¹⁸F-NaF PET-CT. Patients with only one PSA measurement were excluded from analysis. PSADT was calculated as the natural log of 2 divided by the

slope of log PSA level divided by time in months. PSA velocity (PSAV) was calculated as the slope of the linear regression of PSA levels over time in years.^[24] Receiver operating characteristic (ROC) analysis for ¹⁸F-NaF PET positivity was performed using PSA, PSADT, and PSAV as independent variables. ROC analysis was also performed using combined models with (1) PSA and PSADT, (2) PSA and PSAV, and (3) PSA, PSADT, and PSAV.

Results

Nine of 36 patients (25%) had received androgen deprivation therapy at some time during the course of their treatment after radical prostatectomy, but none were receiving androgen deprivation therapy at the time of the ¹⁸F-NaF PET-CT. Serum PSA values were dated between 0 and 8.6 weeks (mean 2.6 weeks) of the ¹⁸F-NaF PET-CT. There was a mean of 6.98 years (range: 0.27–14.61 years) from the date of prostatectomy to the time of the ¹⁸F-NaF PET-CT. Tables 1 and 2 list the parameters for patients with positive and negative ¹⁸F-NaF PET-CT scans, respectively.

Of the 36 patients, 8 (22.2%) had positive ¹⁸F-NaF PET-CT scans, 7 were confirmed as true positive with subsequent studies on either ¹⁸F-NaF PET-CT or conventional imaging [Table 1]. Mean values for PSA, PSADT, and PSAV were 2.02 ng/ml (range: 0.06–11.7 ng/ml), 13.2 months (range: 1.11–60.84), and 1.28 ng/ml/year (range: 0.1–5.28) for ¹⁸F-NaF PET-CT negative scans, respectively. Mean values for PSA, PSADT, and PSAV and 4.11 ng/ml (range: 0.04–14.38 ng/ml), 8.9 months (range: 0.7–27.8), and 9.06 ng/ml/year (range: 0.04–50.2) for ¹⁸F-NaF PET-CT positive scan, respectively. Statistical comparison between the corresponding PSA parameters for negative and positive ¹⁸F-NaF PET-CT yielded probabilities of 0.07 for serum PSA level, 0.47 for PSADT, and 0.02 for PSAV. The lowest serum PSA level with positive scan and highest serum PSA level with negative scan were 0.04 ng/ml and 11.70 ng/ml, respectively. Figure 1 is an illustrative example of a patient with positive ¹⁸F-NaF PET-CT.

Table 1: Patients with positive ¹⁸F-sodium fluoride positron emission tomography scans

Patient number	PSA (ng/ml)	PSADT (months)	PSAV (ng/ml/year)	Primary tumor Gleason score	Surgical margin	Radiotherapy (adjuvant)	Radiotherapy (salvage)	T-stage
1	0.04	2.216	0.130	7	Positive	No	No	pT2c
2	0.12	20.027	0.042	7	Negative	No	No	pT3a
3	1.3	2.415	1.974	9	Negative	No	Yes	pT2b
4	2.48	0.706	50.240	9	Positive	No	Yes	pT3a
5	4.33	7.769	3.119	7	Unknown	No	Yes	pT3a
6	4.42	3.584	3.678	7	Negative	No	No	pT3a
7	5.83	27.847	1.508	7	Negative	No	No	pT2b
8	14.38	6.492	11.757	8	Positive	No	Yes	pT3a

PSA: Prostate-specific antigen; PSADT: Prostate-specific antigen doubling time; PSAV: Prostate-specific antigen velocity

Table 2: Patients with negative ¹⁸F-sodium fluoride positron emission tomography scans

Patient number	PSA (ng/ml)	PSADT (months)	PSAV (ng/ml/year)	Primary tumor Gleason score	Surgical margin	Radiotherapy (adjuvant)	Radiotherapy (salvage)	T-stage
1	0.06	3.63	0.10	7	Negative	No	No	pT2c
2	0.11	6.02	0.10	7	Negative	No	No	pT3b
3	0.18	1.11	0.78	7	Negative	No	No	pT2c
4	0.18	3.95	0.27	8	Negative	No	No	pT2c
5	0.36	2.95	1.04	9	Negative	No	No	pT2c
6	0.39	10.10	0.24	-	Negative	No	No	pT3b
7	0.49	6.31	0.37	7	Negative	No	Yes	pT3a
8	0.5	2.09	1.30	8	Negative	No	No	pT2c
9	0.73	4.05	1.11	8	Negative	No	Yes	pT3a
10	0.8	2.32	1.23	7	Unknown	Yes	No	pT3b
11	0.97	19.33	0.38	7	Negative	No	No	pT2C
12	1	2.13	2.22	7	Positive	No	Yes	pT2c
13	1.08	60.84	0.17	7	Positive	No	No	pT3a
14	1.26	1.67	2.28	7	Negative	No	Yes	pT3b
15	1.29	10.73	0.76	8	Positive	Yes	No	pT3b
16	1.29	11.75	0.72	7	Negative	No	Yes	pT3a
17	1.4	3.75	1.63	7	Negative	No	Yes	pT3b
18	1.53	7.79	1.02	8	Negative	No	No	pT3a
19	1.6	4.33	1.41	7	Positive	Yes	No	pT3a
20	1.92	28.14	0.50	8	Negative	No	No	pT3a
21	2.1	2.78	2.73	7	Negative	No	No	pT2c
22	2.79	36.39	0.61	6	Unknown	No	Yes	pT3a
23	2.84	9.45	1.50	9	Positive	Yes	No	pT3b
24	2.88	39.43	0.57	-	Unknown	No	No	-
25	4.31	22.90	1.34	7	Positive	No	No	pT2b
26	6.32	8.41	4.36	7	Positive	Yes	No	pT3a
27	6.59	6.57	5.28	7	Negative	No	Yes	pT3a
28	11.7	51.78	1.81	7	Positive	Yes	No	pT3b

PSA: Prostate-specific antigen; PSADT: Prostate-specific antigen doubling time; PSAV: Prostate-specific antigen velocity

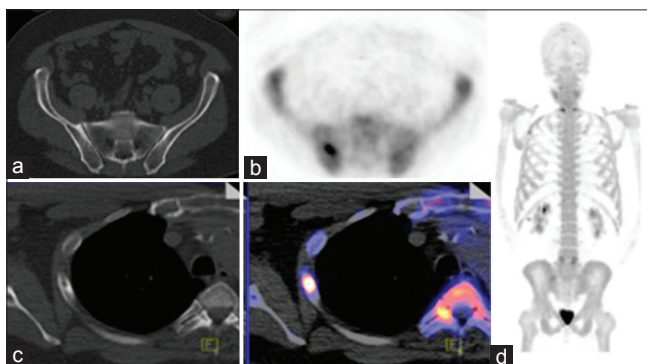


Figure 1: Illustrative example of a patient with positive ¹⁸F-sodium fluoride positron emission tomography-computed tomography (patient 1 in Table 1; PSA = 0.04 ng/ml, PSA doubling time = 2.216 months, PSA velocity = 0.13 ng/ml/year). Note the abnormally increased uptake of the ¹⁸F-sodium fluoride in a right lateral rib (b) and in right ilium corresponding to subtle sclerosis on computed tomography. No other suspicious lesions were seen (a: Axial computed tomography, b: Axial ¹⁸F-sodium fluoride positron emission tomography, c: Axial computed tomography [left], fused ¹⁸F-sodium fluoride positron emission tomography-computed tomography [right], d: ¹⁸F-sodium fluoride positron emission tomography maximum intensity projection image)

ROC analysis for ¹⁸F-NaF PET positivity resulted in area under curve (AUC) values of 0.634 for PSA [Figure 2],

0.598 for PSADT [Figure 3], and 0.688 for PSAV [Figure 4]. ROC analysis with combined models gave AUC values of 0.723 for PSA and PSADT [Figure 5], 0.689 for PSA and PSAV [Figure 6], and 0.718 for PSA, PSADT, and PSAV [Figure 7]. There was no association found between ¹⁸F-NaF PET positivity and primary tumor Gleason score, primary TN staging, and status of surgical tumor margins.

Discussion

Detection and localization of early metastatic disease in patients with biochemical recurrence after definitive local therapy for primary prostate cancer is clinically important for selecting an appropriate course of management. In many patients, however, conventional imaging is negative or inconclusive, particularly in those patients with relatively low serum PSA levels.^[4,25] A retrospective study of 142 postprostatectomy patients with PSA rise to 1 ng/ml who underwent evaluation with combination of pelvic mMRI ± whole-body or bone MRI, standard BS, chest-abdomen-pelvis CT, FDG PET-CT, or ¹⁸F-NaF PET-CT found that 75% of patients with positive imaging findings and 60% patients with negative

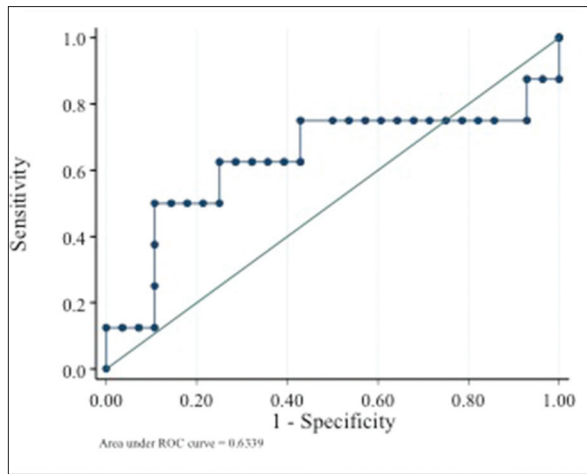


Figure 2: Positron emission tomography positivity prediction using serum PSA level. Area under the curve = 0.6339, 95 confidence interval: (0.35, 0.92), $P > 0.4$

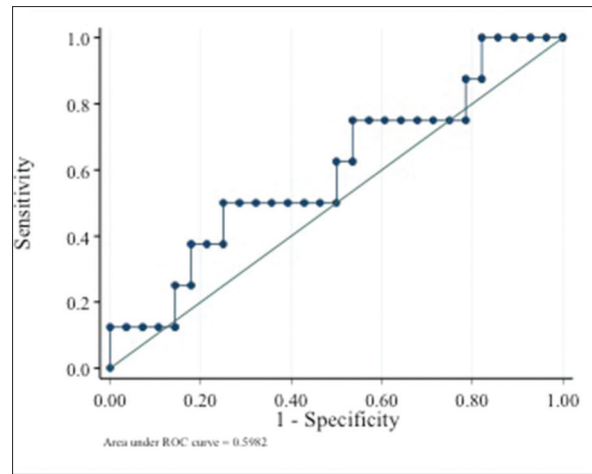


Figure 3: Positron emission tomography positivity prediction using PSA doubling time. Area under the curve = 0.5982, 95 confidence interval: (0.36, 0.84), $P > 0.4$

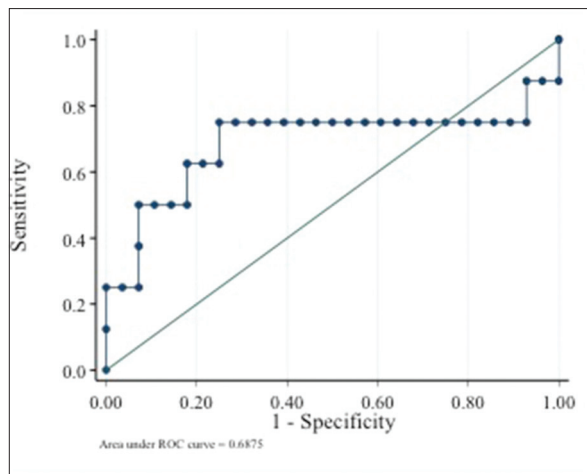


Figure 4: Positron emission tomography positivity prediction using PSA velocity. Area under the curve = 0.6875, 95 confidence interval: (0.40, 0.98), $P = 0.2$

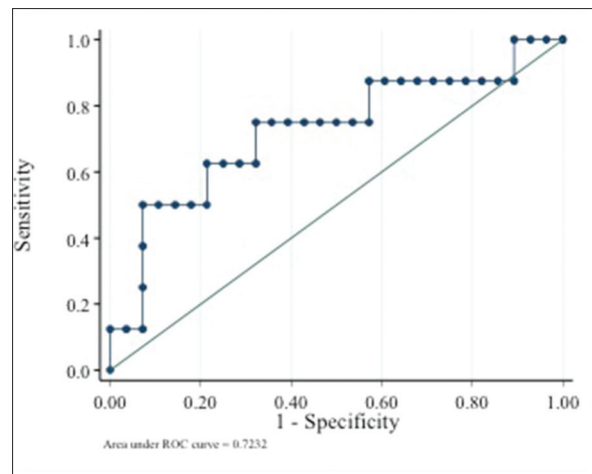


Figure 5: Positron emission tomography positivity prediction using PSA and PSA doubling time. Area under the curve = 0.7232, 95 confidence interval: (0.49, 0.95), $P = 0.06$

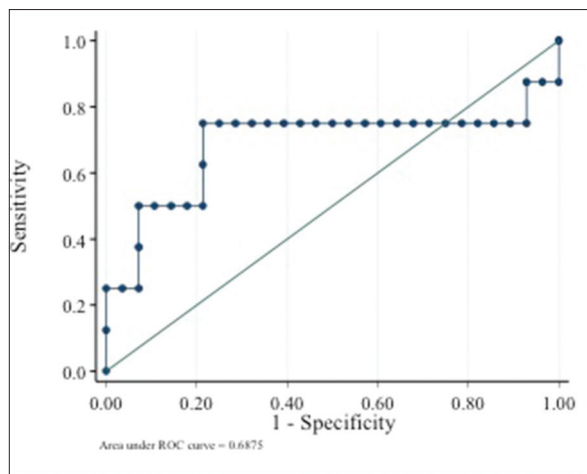


Figure 6: Positron emission tomography positivity prediction using PSA and PSA velocity. Area under the curve = 0.6875, 95 confidence interval: (0.40, 0.98), $P = 0.2$

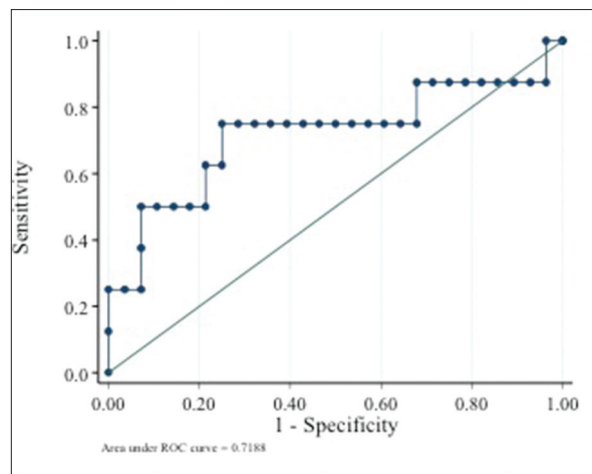


Figure 7: Positron emission tomography positivity prediction using PSA, PSA doubling time, and PSA velocity. Area under the curve = 0.7188, 95 confidence interval: (0.46, 0.97), $P = 0.1$

imaging received treatment (radiation, hormones, or chemotherapy).^[26] This investigation suggested that at low serum PSA levels, many postprostatectomy patients with negative imaging finding would still receive some type of treatment, despite potential side effects and uncertainty on outcome. Conversely, when sites of disease can be localized, then it is reasonable to presume that patients will receive tailored treatment (aligned with the concept personalized or precision medicine) with disease sites that can be monitored objectively during and after treatment. This strategy also allows for use of novel therapies in oligometastatic disease taking into account patient's overall underlying risk (low-risk patients: Stage T1c, T2a, and PSA level ≤ 10 ng/ml and Gleason score ≤ 6 ; intermediate-risk: stage T2b or Gleason score of 7 or PSA level > 10 and ≤ 20 ng/ml; and high-risk: Stage T2c or PSA level > 20 ng/ml or Gleason score ≥ 8) that may ultimately lead to overall improved patient outcome.^[27,28] In addition, economic modeling studies suggest that a diagnostic technology capable of accurately identifying localized versus metastatic disease in men with biochemical recurrence after radical prostatectomy would be cost-effective in comparison to current conventional work-up.^[29]

Dotan *et al.* found in an investigation of 330 patients with biochemical recurrence (defined as PSA level ≥ 0.4 ng/ml) after radical prostatectomy that positivity on conventional BS was associated with increasing serum PSA level; 4% for PSA levels 0–10, 36% for PSA levels 10.1–20, 50% for PSA levels 20.1–50, and 79% for PSA levels above 50 ng/ml.^[30] In multivariate analysis, only PSA slope (odds ratio [OR], 2.71; $P = 0.03$), PSAV (OR, 0.93; $P = 0.003$), and trigger PSA (OR, 1.022; $P < 0.001$) predicted a positive BS. Similar results were reported by Moreira *et al.* that in both castrate-sensitive cases and cases after androgen deprivation therapy, more aggressive and advanced disease were identified by higher PSA levels, higher PSAV, and shorter PSADT with higher BS positivity.^[24]

We found first-time suspicious osseous metastases in 22.2% of our patients with PSA relapse. Patients with positive scans were found to have higher mean PSA values, shorter mean PSADT, and higher mean PSAV. However, PSAV turned out to be the only statistically significant parameter for predicting ¹⁸F-NaF PET-CT positivity. Combining PSA level with PSADT or PSA level with PSADT and PSAV resulted in higher predictability for a positive ¹⁸F-NaF PET-CT than any single variable independently. Particularly in patients with serum PSA level of < 10 ng/ml, we observed positive findings in seven out of eight ¹⁸F-NaF PET-CT scans. This suggested that ¹⁸F-NaF PET-CT may be useful in patients with low PSA values that would typically be excluded

from undergoing conventional BS on the basis of serum PSA level alone.

Our results with ¹⁸F-NaF as the PET radiotracer in this clinical setting mirrors similar observation with other PET radiotracers, with relatively robust published evidence on ¹¹C-choline and ¹⁸F-fluorocholine.^[31,32] Castellucci *et al.* concluded that PSA, PSADT, and PSAV could each be independent predictors of ¹¹C-choline positivity, with PSA kinetics having particular importance in patients with very low PSA values.^[12] Using ¹⁸F-fluorochlorine PET, Graute *et al.* determined optimal threshold values of a PSA > 1.74 ng/ml and PSAV > 1.27 ng/ml/year.^[13] In a recent systematic review and meta-analysis of 18 articles that employed ¹¹C-choline or ¹⁸F-fluorocholine PET-CT in the imaging evaluation of patients with biochemical recurrence of prostate cancer, positive findings suspicious for disease sites were noted in 1219 of 2213 (54.9%) patients. In these studies, the mean of the mean restaging PSA levels was 3.6 ± 2.7 ng/ml (range: 0.5–10.7 ng/ml).^[33] Treglia *et al.* performed a systematic review of 14 articles on choline PET-CT in restaging prostate cancer that focused specifically on the association between PSA level and kinetics on lesion detection. A positive association was noted with increasing PSA level, decreasing PSADT, and increasing PSAV.^[34] Similar results have also appeared for the recently developed ⁶⁸gallium prostate-specific membrane antigen PET-CT with a systematic review and meta-analysis demonstrating detection rates that increase with increasing PSA level and shorter PSADT.^[35]

The observation of increasing probability of potential lesion detection on PET-CT, regardless of the radiotracer, with increasing PSA level or abnormal PSA kinetics is likely reflective of the underlying burden of disease, especially in castrate-sensitive clinical state. Our study focused on detection of suspicious positive findings in bone as demarcated on ¹⁸F-NaF PET-CT for which subsequent imaging studies or clinical impression and management decision of the treating physician were used as a proxy for verification. Histologic confirmation for suspicious visualized positive lesions was impractical due to ethical and economical reasons. Further investigation should incorporate a larger prospective cohort to corroborate the preliminary findings of this study.

Conclusions

Our results suggest that in the setting of biochemical recurrence postprostatectomy, ¹⁸F-NaF PET-CT may be useful for detection and localization of first bone metastases in men with serum PSA levels lower than 10 ng/ml and with increasing PSAV.

Acknowledgments

We would like to acknowledge the support of the United States National Institute of Health, National Cancer Institute grants R01-CA111613 and P30-CA014089. The authors thank the statistical help of Lingyun Ji and Dr. Susan Groshen.

Financial support and sponsorship

We would like to acknowledge the support of the United States National Institute of Health, National Cancer Institute grants R01-CA111613 and P30-CA014089.

Conflicts of interest

There are no conflicts of interest.

References

- American Cancer Society. Cancer Facts and Figures 2015. Atlanta, GA: American Cancer Society; 2015.
- Pound CR, Partin AW, Eisenberger MA, Chan DW, Pearson JD, Walsh PC. Natural history of progression after PSA elevation following radical prostatectomy. *JAMA* 1999;281:1591-7.
- Cookson MS, Aus G, Burnett AL, Canby-Hagino ED, D'Amico AV, Dmochowski RR, et al. Variation in the definition of biochemical recurrence in patients treated for localized prostate cancer: The American Urological Association Prostate Guidelines for Localized Prostate Cancer Update Panel report and recommendations for a standard in the reporting of surgical outcomes. *J Urol* 2007;177:540-5.
- Kane CJ, Amling CL, Johnstone PA, Pak N, Lance RS, Thrasher JB, et al. Limited value of bone scintigraphy and computed tomography in assessing biochemical failure after radical prostatectomy. *Urology* 2003;61:607-11.
- Hricak H, Schöder H, Pucar D, Lis E, Eberhardt SC, Onyebuchi CN, et al. Advances in imaging in the postoperative patient with a rising prostate-specific antigen level. *Semin Oncol* 2003;30:616-34.
- Jadvar H, Desai B, Ji L, Conti PS, Dorff TB, Groshen SG, et al. Prospective evaluation of ¹⁸F-NaF and ¹⁸F-FDG PET/CT in detection of occult metastatic disease in biochemical recurrence of prostate cancer. *Clin Nucl Med* 2012;37:637-43.
- Vees H, Buchegger F, Albrecht S, Khan H, Husarik D, Zaidi H, et al. ¹⁸F-choline and/or ¹¹C-acetate positron emission tomography: Detection of residual or progressive subclinical disease at very low prostate-specific antigen values (<1 ng/mL) after radical prostatectomy. *BJU Int* 2007;99:1415-20.
- Giovacchini G, Picchio M, Parra RG, Briganti A, Gianolli L, Montorsi F, et al. Prostate-specific antigen velocity versus prostate-specific antigen doubling time for prediction of ¹¹C choline PET/CT in prostate cancer patients with biochemical failure after radical prostatectomy. *Clin Nucl Med* 2012;37:325-31.
- Castellucci P, Fuccio C, Rubello D, Schiavina R, Santi I, Nanni C, et al. Is there a role for ¹¹C-choline PET/CT in the early detection of metastatic disease in surgically treated prostate cancer patients with a mild PSA increase <1.5 ng/mL? *Eur J Nucl Med Mol Imaging* 2011;38:55-63.
- Mamede M, Ceci F, Castellucci P, Schiavina R, Fuccio C, Nanni C, et al. The role of ¹¹C-choline PET imaging in the early detection of recurrence in surgically treated prostate cancer patients with very low PSA level <0.5 ng/mL. *Clin Nucl Med* 2013;38:e342-5.
- Giovacchini G, Picchio M, Parra RG, Briganti A, Gianolli L, Montorsi F, et al. Prostate-specific antigen velocity versus prostate-specific antigen doubling time for prediction of ¹¹C choline PET/CT in prostate cancer patients with biochemical failure after radical prostatectomy. *Clin Nucl Med* 2012;37:325-31.
- Castellucci P, Fuccio C, Nanni C, Santi I, Rizzello A, Lodi F, et al. Influence of trigger PSA and PSA kinetics on ¹¹C-Choline PET/CT detection rate in patients with biochemical relapse after radical prostatectomy. *J Nucl Med* 2009;50:1394-400.
- Graute V, Jansen N, Ubleis C, Seitz M, Hartenbach M, Scherr MK, et al. Relationship between PSA kinetics and [¹⁸F] fluorocholine PET/CT detection rates of recurrence in patients with prostate cancer after total prostatectomy. *Eur J Nucl Med Mol Imaging* 2012;39:271-82.
- Spick C, Polanec SH, Mitterhauser M, Wadsak W, Anner P, Reiterits B, et al. Detection of bone metastases using ¹¹C-acetate PET in patients with prostate cancer with biochemical recurrence. *Anticancer Res* 2015;35:6787-91.
- FDA Approves New Diagnostic Imaging Agent to Detect Recurrent Prostate Cancer. Available from: <http://www.fda.gov/NewsEvents/Newsroom/PressAnnouncements/ucm503920.htm>. [Last accessed on 2016 Jul 25].
- Oldan JD, Hawkins AS, Chin BB. (18) F sodium fluoride PET/CT in Patients with prostate cancer: Quantification of normal tissues, benign degenerative lesions, and malignant lesions. *World J Nucl Med* 2016;15:102-8.
- Even-Sapir E, Metser U, Mishani E, Lievshitz G, Lerman H, Leibovitch I. The detection of bone metastases in patients with high-risk prostate cancer: ^{99m}Tc-MDP Planar bone scintigraphy, single- and multi-field-of-view SPECT, ¹⁸F-fluoride PET, and ¹⁸F-fluoride PET/CT. *J Nucl Med* 2006;47:287-97.
- Hughes CT, Nix JW. Role of sodium fluoride PET imaging for identification of bony metastases in prostate cancer patients. *Curr Urol Rep* 2015;16:31.
- Hillner BE, Siegel BA, Hanna L, Duan F, Shields AF, Coleman RE. Impact of ¹⁸F-fluoride PET in patients with known prostate cancer: Initial results from the National Oncologic PET Registry. *J Nucl Med* 2014;55:574-81.
- Available from: <http://www.cancerpetregistry.org/status.htm>. [Last accessed on 2016 Jul 30].
- Decision Memo for Positron Emission Tomography (NaF-18) to Identify Bone Metastasis of Cancer (CAG-00065R2). Available from: <https://www.cms.gov/medicare-coverage-database/details/nca-decision-memo.aspx?NCAId=279>. [Last accessed on 2016 Jul 30].
- NCCN Guidelines Version 3. 2016, Prostate Cancer; 2016. Available from: https://www.nccn.org/professionals/physician_gls/pdf/prostate.pdf. [Last accessed on 2016 Jul 30].
- Gomez P, Manoharan M, Kim SS, Soloway MS. Radionuclide bone scintigraphy in patients with biochemical recurrence after radical prostatectomy: When is it indicated? *BJU Int* 2004;94:299-302.
- Moreira DM, Cooperberg MR, Howard LE, Aronson WJ, Kane CJ, Terris MK, et al. Predicting bone scan positivity after biochemical recurrence following radical prostatectomy in both hormone-naive men and patients receiving androgen-deprivation therapy: Results from the SEARCH database. *Prostate Cancer Prostatic Dis* 2014;17:91-6.
- Okotie OT, Aronson WJ, Wieder JA, Liao Y, Dorey F, DeKERNION JB, et al. Predictors of metastatic disease in men with biochemical failure following radical prostatectomy. *J Urol* 2004;171 (6 Pt 1):2260-4.
- Vargas HA, Martin-Malburet AG, Takeda T, Corradi RB, Eastham J,

- Wibmer A, *et al.* Localizing sites of disease in patients with rising serum prostate-specific antigen up to 1ng/ml following prostatectomy: How much information can conventional imaging provide? *Urol Oncol* 2016. pii: S1078-143930107-7.
27. Bernard B, Gershman B, Karnes RJ, Sweeney CJ, Vapiwala N. Approach to oligometastatic prostate cancer. *Am Soc Clin Oncol Educ Book* 2016;35:119-29.
 28. D'Amico AV, Whittington R, Malkowicz SB, Schultz D, Blank K, Broderick GA, *et al.* Biochemical outcome after radical prostatectomy, external beam radiation therapy, or interstitial radiation therapy for clinically localized prostate cancer. *JAMA* 1998;280:969-74.
 29. Barocas DA, Bensink ME, Berry K, Musa Z, Bodnar C, Dann R, *et al.* Economic evaluation of diagnostic localization following biochemical prostate cancer recurrence. *Int J Technol Assess Health Care* 2014;30:345-53.
 30. Dotan ZA, Bianco FJ Jr., Rabbani F, Eastham JA, Fearn P, Scher HI, *et al.* Pattern of prostate-specific antigen (PSA) failure dictates the probability of a positive bone scan in patients with an increasing PSA after radical prostatectomy. *J Clin Oncol* 2005;23:1962-8.
 31. Jadvar H. Positron emission tomography in prostate cancer: Summary of systematic reviews and meta-analysis. *Tomography* 2015;1:18-22.
 32. Yu CY, Desai B, Ji L, Groshen S, Jadvar H. Comparative performance of PET tracers in biochemical recurrence of prostate cancer: A critical analysis of literature. *Am J Nucl Med Mol Imaging* 2014;4:580-601.
 33. von Eyben FE, Kairemo K. Acquisition with (11)C-choline and (18)F-fluorocholine PET/CT for patients with biochemical recurrence of prostate cancer: A systematic review and meta-analysis. *Ann Nucl Med* 2016;30:385-92.
 34. Treglia G, Ceriani L, Sadeghi R, Giovacchini G, Giovanella L. Relationship between prostate-specific antigen kinetics and detection rate of radiolabelled choline PET/CT in restaging prostate cancer patients: A meta-analysis. *Clin Chem Lab Med* 2014;52:725-33.
 35. Perera M, Papa N, Christidis D, Wetherell D, Hofman MS, Murphy DG, *et al.* Sensitivity, specificity, and predictors of positive ⁶⁸Ga-prostate-specific membrane antigen positron emission tomography in advanced prostate cancer: A systematic review and meta-analysis. *Eur Urol* 2016. pii: S0302-283830293-7.