

Case Report

FDG PET/CT in Detection of Metastatic Involvement of Heart and Treatment Monitoring in Non-Hodgkin's Lymphoma

Kanhaiyalal Agrawal, Bhagwant Rai Mittal, Kuruva Manohar, Raghava Kashyap, Anish Bhattacharya, Subhash Varma¹

Departments of Nuclear Medicine and PET, and ¹Internal Medicine, Postgraduate Institute of Medical Education and Research, Chandigarh, India

Abstract

Cardiac metastasis occurs in up to a quarter of patients with metastatic cancer and is seen most commonly in melanoma and lymphoma. Metastatic involvement of the heart and pericardium may go unrecognized until autopsy. We describe a patient of non-Hodgkin's lymphoma detected to have involvement of right atrium on F-18 FDG PET/CT and monitoring of response to chemotherapy.

Keywords: Cardiac metastases, FDG PET/CT, lymphoma, response evaluation

Introduction

Cardiac metastasis is not uncommon. The clinical findings of cardiac metastasis are often non-specific. On the other hand it is important to detect early any metastasis to life threatening sites like heart, brain, spinal cord, etc; so that prompt therapeutic interventions could be made to reduce morbidity and mortality. FDG PET/CT is widely used in the diagnostic evaluation and staging of different malignant tumors. The technique has also proven to be extremely useful in treatment monitoring.

Case Report

A 73-year-old female patient presented with abdominal pain and swelling in right infra clavicular region. Abdominal ultrasonography was normal. Upper GI endoscopy revealed whitish plaques in the esophagus

with bulging papillae in second part of duodenum, which raised the suspicion of GI malignancy. FNAC from the right infraclavicular swelling was suggestive of reactive lymphoid hyperplasia. Whole body MRI revealed one T2 hyperintense lesion in right thyroid lobe, two solid nodules in right breast and a few well-defined, rounded, hyperintense lesions in head of both the humeri and D12-L2 vertebral bodies. Thyroid scan showed cold nodule in the right lobe of thyroid gland. Due to indeterminate nature of the lesions, F18-FDG PET/CT was performed [Figure 1]. Maximum intensity projection (A) of F18-FDG PET/CT study revealed intensely FDG-avid soft tissue mass in the right breast tissue, FDG avid cervical, right supraclavicular, right axillary, mediastinal and abdominal lymph nodes. Intense FDG uptake in a filling defect of size 2.6 × 2.0 cm in the right atrium (arrow) was also noticed (A). Transaxial fused PET/CT image (C) showed intensely FDG avid right atrial lesion (arrow) and soft tissue density in the right breast. Overall features of PET scan were suggestive of lymphoma or primary in right breast with metastases. Biopsy from the right supraclavicular lymph node was positive for diffuse large B-cell lymphoma (DLBCL). Repeat PET/CT scan (B) after two cycles of chemotherapy (R-CHOP) showed complete resolution of FDG avidity in the breast, heart and bone lesions. Mild FDG uptake was

Access this article online

Quick Response Code:



Website:
www.wjnm.org

DOI:
10.4103/1450-1147.98746

Address for correspondence:

Dr. B.R. Mittal, Department of Nuclear Medicine, Postgraduate Institute of Medical Education and Research, Chandigarh – 160012, India.
E-mail: brmittal@yahoo.com

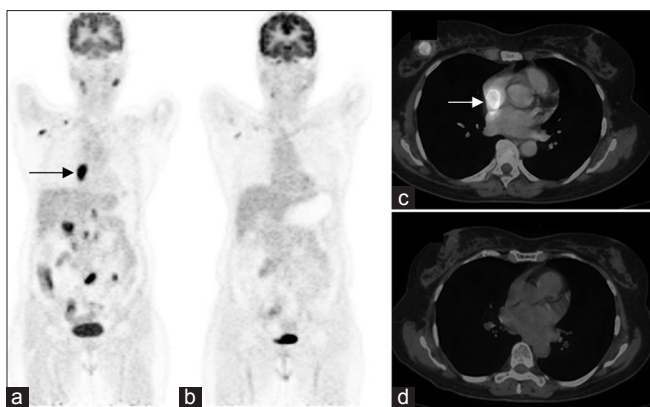


Figure 1: F18-FDG PET/CT study (a) maximum intensity projection showing intensely FDG-avid soft tissue mass in the right breast tissue, FDG avid cervical, right supraclavicular, right axillary, mediastinal and abdominal lymph nodes. Intense FDG uptake (arrow) in the region of right atrium is also noticed. Transaxial-fused PET/CT image (c) showed intensely FDG avid right atrial lesion (arrow) and soft tissue density in the right breast. Repeat PET/CT scan (b) after 2 cycles of chemotherapy showing complete resolution of FDG avidity in the breast, heart and bone lesions. Mild FDG uptake is noted in a few cervical and right axillary lymph nodes suggestive of significant metabolic response. Transaxial-fused PET/CT image after two cycles of chemotherapy (d) also showed complete resolution of FDG avidity in the breast and heart

noted in a few cervical and right axillary lymph nodes suggestive of significant metabolic response. Transaxial fused PET/CT image after two cycles of chemotherapy (D) also showed complete resolution of FDG avidity in the breast and heart.

Cardiac metastasis occurs in up to a quarter of patients with metastatic cancer and is seen most commonly in melanoma and lymphoma.^[1] Often, the diagnosis is not made until autopsy. Secondary cardiac lymphomas are found in approximately 10–30% of lymphoma patients in autopsy studies.^[2] Most cases are B-cell lymphomas and present with cardiac involvement fairly late in the course of the disease.^[3] Metastases to the heart and pericardium are generally associated with a poor prognosis.^[4-6] Overall, cardiac lymphoma remains a difficult diagnosis. Serial PET has been suggested to be more accurate than MRI and echocardiography for

assessing cardiac lymphoma regression.^[7] In literature a few case reports have shown the pattern of involvement of metastatic involvement of the heart in non-Hodgkin's lymphoma.^[8,9] We describe a unique case where FDG PET allowed early diagnosis, prompt treatment and monitor response to chemotherapy of cardiac lesion, thus leading to the resolution of heart lesion before the occurrence of any cardiac complications.

References

1. Reynen K, Kockeritz U, Strasser RH. Metastasis to the heart. *Ann Oncol* 2004;15:375-81.
2. Nascimento AF, Winters GL, Pinkus GS. Primary cardiac lymphoma: clinical, histologic, immunophenotypic, and genotypic features of 5 cases of a rare disorder. *Am J Surg Pathol* 2007;31:1344-50.
3. Lim ZY, Grace R, Salisbury JR, Creamer D, Jayaprakasam A, Ho AY, et al. Cardiac presentation of ALK positive anaplastic large cell lymphoma. *Eur J Haematol* 2005;75:511-4.
4. Lam KY, Dickens P, Chan AC. Tumors of the heart. A 20-year experience with a review of 12,485 consecutive autopsies. *Arch Pathol Lab Med* 1993;117:1027-31.
5. Mukai K, Shinkai T, Tominaga K, Shimosato Y. The incidence of secondary tumors of the heart and pericardium: a 10-year study. *Jpn J Clin Oncol* 1988;18:195-201.
6. Park SM, Shim CY, Choi D, Lee JH, Kim SA, Choi EY, et al. Coronary sinus obstruction by primary cardiac lymphoma as a cause of dyspnea due to significant diastolic dysfunction and elevated filling pressures. *J Am Soc Echocardiogr* 2010;23:682. e5-7.
7. Mato AR, Morgans AK, Rouillet MR, Bagg A, Glatstein E, Litt HI, et al. Primary cardiac lymphoma: Utility of multimodality imaging in diagnosis and management. *Cancer Biol Ther* 2007;6:1867-70.
8. Römer W, Garbrecht M, Fuchs C, Schwaiger M. Images in cardiovascular medicine. Metabolic imaging identifies non-Hodgkin's lymphoma infiltrating heart. *Circulation* 1998;97:2577-8.
9. Julian A, Wagner T, Ysebaert L, Chabbert V, Payoux P. FDG PET/CT leads to the detection of metastatic involvement of the heart in non-Hodgkin's lymphoma. *Eur J Nucl Med Mol Imaging* 2011;38:1174.

How to cite this article: Agrawal K, Mittal BR, Manohar K, Kashyap R, Bhattacharya A, Varma S. FDG PET/CT in Detection of Metastatic Involvement of Heart and Treatment Monitoring in Non-Hodgkin's Lymphoma. *World J Nucl Med* 2012;11:33-4.

Source of Support: Nil. **Conflict of Interest:** None declared.

Announcement

"QUICK RESPONSE CODE" LINK FOR FULL TEXT ARTICLES

The journal issue has a unique new feature for reaching to the journal's website without typing a single letter. Each article on its first page has a "Quick Response Code". Using any mobile or other hand-held device with camera and GPRS/other internet source, one can reach to the full text of that particular article on the journal's website. Start a QR-code reading software (see list of free applications from <http://tinyurl.com/yzlh2tc>) and point the camera to the QR-code printed in the journal. It will automatically take you to the HTML full text of that article. One can also use a desktop or laptop with web camera for similar functionality. See <http://tinyurl.com/2bw7fn3> or <http://tinyurl.com/3ysr3me> for the free applications.