

Cerebellar metastasis from serous adenocarcinoma of the ovary mimicking pilocytic astrocytoma

Vivek Tandon, Kanwaljeet Garg, A. K. Mahapatra

Department of Neurosurgery, All India Institute of Medical Sciences, New Delhi, India

ABSTRACT

Serous adenocarcinoma of the ovary rarely can present with solitary solid -cystic cerebellar metastasis, mimicking pilocytic astrocytoma. A middle aged women, who underwent total abdominal hysterectomy with bilateral salpingoophorectomy and adjuvant chemotherapy for ovarian adenocarcinoma, presented to us with the history of headache, vomiting, and imbalance. Contrast enhanced magnetic resonance imaging (MRI) showed solitary cerebellar, solid cystic lesion with cyst lining and solid portion enhancing on contrast which was mimicking pilocytic astrocytoma and there was no perilesional edema. Gross total excision of the cerebellar lesion was done followed by resolution of her symptoms. Histopathology showed metastatic adenocarcinoma consistent with the primary ovarian carcinoma. In patients of ovarian carcinoma, presenting with features of raised intracranial pressure [ICP] thorough investigations must be done to rule out metastasis. Solitary metastasis of the cerebellum because of ovarian carcinoma may mimic pilocytic astrocytoma.

Key words: Cerebellar metastases, ovarian cystadenocarcinoma, pilocytic astrocytoma

Introduction

Among gynecological malignancies, ovarian cancer is a major cause of morbidity and mortality.^[1] Survival has increased with platinum based chemotherapy; therefore, rarely, brain metastases can be seen in epithelial ovarian cancers, its incidence ranges from 0.29 to 5%. Other reasons for increasing incidence of brain metastases can be better imaging techniques and poor penetration of chemotherapy agents across blood brain barrier. Central Nervous System (CNS) metastases in cases of epithelial ovarian cancer is believed to occur via hematogenous seeding through Virchow – Robin perivascular spaces, through retrograde lymphatic spread in the case of meningeal involvement, or by direct invasion after bony involvement.^[2] Ovarian metastasis mimicking pilocytic astrocytoma is extremely rare.

Case Report

This 38-year-old lady underwent total abdominal hysterectomy with bilateral salpingoophorectomy one and a half year back. Biopsy was serous adenocarcinoma. Adjuvant cisplatin based chemotherapy was given. She presented to us with history of four months of headache, raised intracranial pressure and right side cerebellar symptoms and signs. Magnetic Resonance Imaging (MRI) brain revealed solitary right sided cerebellar SOL with solid – cystic component, which was hypo on T1W1 images and hyper on T2W1 images. Solid component along with cyst wall showed contrast enhancement. There was no perilesional edema [Figure 1a-c]. Workup for any other site of metastases was negative. Right sided retromastoid sub occipital craniotomy with gross total excision of the tumor was done. Histopathological report was consistent with ovarian adenocarcinoma. Till the last follow-up, after six months of surgery, she had improvement in symptoms and no evidence of recurrence.

Discussion

Our patient had presented after 18 month of previous surgery and adjuvant chemotherapy for serous adenocarcinoma of the ovary. The median interval from the diagnosis of epithelial ovarian carcinoma (EOC) to CNS metastasis manifestation is 21.5 months (range, 0-126 months). However, in 4% of patients, CNS metastasis may present earlier or concomitantly at the time of diagnosis of the ovarian carcinoma.^[3,4]

Most reports have shown that majority of patients (>80%) with CNS metastasis have Federation of Gynaecology and

Access this article online

Quick Response Code:



Website:

www.asianjns.org

DOI:

10.4103/1793-5482.103720

Address for correspondence:

Dr. Vivek Tandon, Room No. 8, 6th Floor, Department of neurosurgery, Cardioneurosciences centre, All India Institute of Medical Sciences, Ansari nagar, New Delhi – 110029, India. E-mail: drtdandonvivek@gmail.com

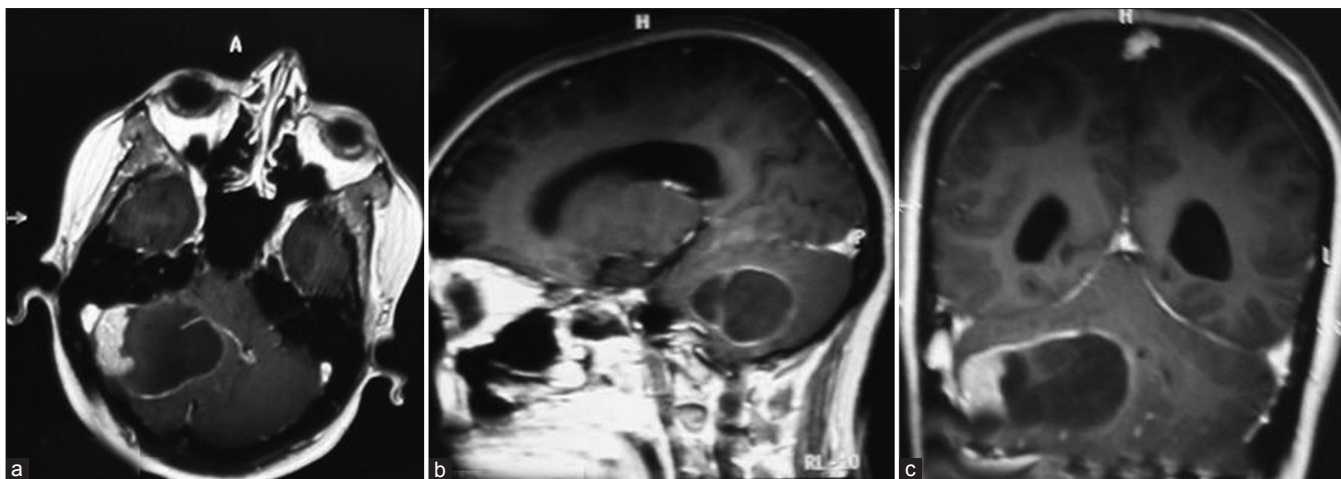


Figure 1a-c: Contrast enhanced MRI images of axial, sagittal and coronal sections of the case showing solid-cystic tumor. Solid portion and lining of the tumor is seen enhancing with the contrast there was no perilesional edema

Obstetrics (FIGO) stage III and IV tumors.^[2,3] The most common type of EOC is the serous type. Cohen *et al.*^[5] had also reported that 24% patients in their series had serous histology.

In about 65% patients, EOC synchronous brain metastases is present with extra cranial disease, while one third may have isolated CNS lesion. Single metastatic lesion in brain was reported in 43% of patients and multiple lesions in 50.1%, while meningeal involvement was seen in 6.3%.^[3]

Brain secondaries usually present with headache which may resemble tension headache and may be associated with features of raised intracranial pressure. Clinical features are variable depending upon the location of metastases. All patients of EOC who develop neurologic deficits must be suspected and evaluated for metastasis of the brain. Contrast enhanced MRI is the imaging modality of choice. Brain metastases are characterized by multiple lesions, typically at grey white junction, profuse perilesional edema, and relatively smooth margin. Our patient in contrast, had a right cerebellar solid cystic lesion, cyst walls and solid components showed enhancement of contrast; surprisingly, there was no perilesional edema or other synchronous sites of disease spread and hence it became difficult to diagnose it conclusively on the basis of MRI scan to be a case of metastases. Patient was unable to afford MR spectroscopy.

Therapeutic options need to be tailored accordingly after considering the age of the patient, status of the primary disease, extra cranial spread, site and number of lesions in brain and performance status of the patient. Treatment of brain metastases may not result in cure but with proper treatment, life expectancy, and quality of life may improve. Treatment options include offering no treatment to patients with widespread metastatic disease, to radical resection in solitary metastasis followed by adjuvant whole brain radiotherapy. Pothuri *et al.*^[6] in their retrospective review have

concluded that surgery followed by Whole Brain Radiation Therapy (WBRT) may result in prolonged survival (median survival, 18 months) in patients with solitary lesions. The median survival time of patients with surgery alone was comparable with that achieved with WBRT alone (6.9 months and 5.3 months, respectively).^[2,5]

Patients with multiple metastases in brain with or without extra cranial disease are offered WBRT with or without chemotherapy. The median survival time with WBRT alone was 3-6 months (range 1.5-27 months).^[2,5] Role of surgery in these patients with multiple intracranial metastases is controversial. However, if all metastatic lesions can be completely resected, then survival is improved and may be comparable to patients undergoing surgery for solitary metastases.

Stereotactic radiosurgery (SRS) by a linear accelerator or gamma knife offers a different treatment option. Radiation Therapy Oncology Group (RTOG) trial showed no significant difference in survival among patients treated with WBRT or WBRT plus SRS (median survival 5.7 months vs. 6.3 months $P=0.13$).^[7] SRS is considered valuable in treatment of patients with solitary metastases who are unable to tolerate surgery or their lesions are inaccessible.

Objective responses and survival benefits in patients with EOC secondaries to chemotherapy has been observed.^[8] Platinum based regime (cisplatin or carboplatin) are known to show good response.^[8]

Conclusion

In this case report, we have described an unusual case of ovarian carcinoma presenting with solitary solid cystic metastases in cerebellum, mimicking low grade astrocytoma. Such patients may cause diagnostic dilemma. They have improved survival and quality of life after complete resection followed by WBRT. Patients with multiple metastases have

a poorer prognosis and can benefit from WBRT and /or systemic chemotherapy. SRS has a role in solitary lesions, where either patient is unlikely to tolerate surgery or lesion is inaccessible.

References

- Greenlee RT, Hill-Harmon MB, Murray T, Thun M. Cancer statistics, 2001. *CA Cancer J Clin* 2001;51:15-36.
- Kumar L, Barge S, Mahapatra AK, Thulker S, Rath GK, Kumar S, *et al.* Central nervous system metastases from primary epithelial ovarian cancer. *Cancer Control* 2003;10:244-53.
- Pectasides D, Aravantinos G, Fountzilas G, Kalofonos C, Efstathiou E, Karina M, *et al.* Brain metastases from epithelial ovarian cancer. The Hellenic Cooperative Oncology Group (HeCOG) experience and review of the literature. *Anticancer Res* 2005;25:3553-8.
- Kaminsky-Forreth MC, Weber B, Conroy T, Spaeth D. Brain metastases from epithelial ovarian carcinoma. *Int J Gynecol Cancer* 2000;10:366-71.
- Cohen ZR, Suki D, Weinberg JS, Marmor E, Lang FF, Gershenson DM, *et al.* Brain metastases in patients with ovarian carcinoma: prognostic factors and outcome. *J Neurooncol* 2004;66:313-25.
- Pothuri B, Chi DS, Reid T, Aghajanian C, Venkatraman E, Alektiar K, *et al.* Craniotomy for central nervous system metastases in epithelial ovarian carcinoma. *Gynecol Oncol* 2002;87:133-7.
- Andrews DW, Scott CB, Sperduto PW, Flanders AE, Gaspar LE, Schell MC, *et al.* Whole brain radiation therapy with or without stereotactic radiosurgery boost for patients with one to three brain metastases: Phase III results of the RTOG 9508 randomised trial. *Lancet* 2004;363:1665-72.
- Cooper KG, Kitchener HC, Parkin DE. Cerebral metastases from epithelial ovarian carcinoma treated with carboplatin. *Gynecol Oncol* 1994;55:318-23.

How to cite this article: Tandon V, Garg K, Mahapatra AK. Cerebellar metastasis from serous adenocarcinoma of the ovary mimicking pilocytic astrocytoma. *Asian J Neurosurg* 2012;7:141-3.

Source of Support: Nil, **Conflict of Interest:** None declared.

Author Help: Reference checking facility

The manuscript system (www.journalonweb.com) allows the authors to check and verify the accuracy and style of references. The tool checks the references with PubMed as per a predefined style. Authors are encouraged to use this facility, before submitting articles to the journal.

- The style as well as bibliographic elements should be 100% accurate, to help get the references verified from the system. Even a single spelling error or addition of issue number/month of publication will lead to an error when verifying the reference.
- Example of a correct style
Sheahan P, O'leary G, Lee G, Fitzgibbon J. Cystic cervical metastases: Incidence and diagnosis using fine needle aspiration biopsy. *Otolaryngol Head Neck Surg* 2002;127:294-8.
- Only the references from journals indexed in PubMed will be checked.
- Enter each reference in new line, without a serial number.
- Add up to a maximum of 15 references at a time.
- If the reference is correct for its bibliographic elements and punctuations, it will be shown as CORRECT and a link to the correct article in PubMed will be given.
- If any of the bibliographic elements are missing, incorrect or extra (such as issue number), it will be shown as INCORRECT and link to possible articles in PubMed will be given.