

CASE REPORT

Giant cavernous hemangiomas of the brain

Amit Agrawal, Pankaj Banode¹, Samarth Shukla²Department of Neurosurgery, MM Institute of Medical Sciences & Research, Mullana (Ambala), Haryana ¹Department of Surgery, ²Department of Pathology, Datta Meghe Institute of Medical Sciences, Sawangi (M), Wardha, Maharashtra, India

ABSTRACT

Cavernous angiomas or hemangiomas or cavernomas are benign, vascular malformations of the central nervous system and classified as occult vascular brain lesions, usually present in adulthood. With the advent of computed tomography and magnetic resonance imaging, these lesions are increasingly recognized in children. We report two cases of pediatric brain cavernomas where the children presented with recurrent seizures. Imaging findings were suggestive of giant cavernous hemangioma. The lesions were excised completely and the patients recovered well without deficits with good control of seizures.

Key words: Cavernous hemangioma, epilepsy, giant, magnetic resonance imaging

Introduction

Cavernous angiomas or hemangiomas or cavernomas are benign, vascular malformations of the central nervous system and classified as occult vascular brain lesions, usually present in adulthood.^[1,2] With the advent of computed tomography (CT) and magnetic resonance imaging (MRI), these lesions are increasingly recognized in children.^[2,3] We report two cases of giant cavernous hemangioma^[3] in children and review the relevant literature.

Case Reports

Case-1

A 14-year-old male child presented with the history of multiple episode of generalized tonic-clonic seizures and headache of 3-month duration. There was no history of focal weakness. His general and systemic examination was unremarkable. Neurologically, he was conscious, alert, and oriented to time, place, and person. Cranial nerves were normal. Motor and sensory examination was normal and there were no focal neurological deficits. Blood investigations were normal. CT

scan brain plain showed well-defined lesions (4.2 × 4.5 cm size) with areas of hyperdensity inside in left temporoparietal region with mass effect [Figure 1a]. With these findings, a diagnosis of cavernous hemangioma with seizures was made. The patient underwent left temporoparietal craniotomy and complete excision of the lesion including surrounding gliotic tissue [Figure 1b]. The patient was receiving Tab. Phenytoin 150 mg once at night time that was continued. The child was doing well at one-year follow-up without any recurrence of seizures.

Case-2

A 10-year-old female child presented with the history of multiple episode of generalized tonic-clonic seizures and headache of 6-month duration. There was no history of focal weakness. Her general and systemic examination was unremarkable. Neurologically, she was conscious, alert, and oriented to time, place, and person. Cranial nerves were normal. Motor and sensory examination was normal and there were no focal neurological deficits. Blood investigations were normal. CT scan brain plain showed deep-seated calcified lesion in the left frontal lobe. MRI brain T1, T2, and FLAIR images showed deep-seated heterogeneous lesion in the left frontal lobe [Figure 2a and b]. Digital subtraction angiography was normal. With these findings, a diagnosis of cavernous hemangioma with intractable seizures was made. The patient underwent left frontal craniotomy and complete excision of the lesion (5×4 cm size) including surrounding gliotic tissue [Figure 2c]. Histopathology confirmed the diagnosis of cavernoma [Figure 3]. The patient was receiving Tab. Phenytoin 150 mg once at night time that was continued. The child was doing well at 9-month follow-up without any recurrence of seizures.

Discussion

The cavernous angiomas are encountered more commonly in

| Access this article online | |
|---|----------------------------------|
| Quick Response Code: | Website: www.asianjns.org |
|  | DOI: 10.4103/1793-5482.106660 |

Address for correspondence:

Dr. Amit Agrawal, Professor of Neurosurgery, MM Institute of Medical Sciences & Research, Maharishi Markandeshwar University, Mullana-Ambala, 133203, Haryana, India. E-mail: dramitagrawal@gmail.com

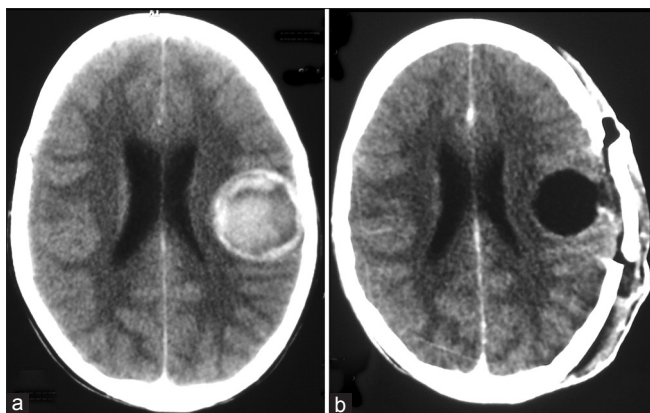


Figure 1: (a) CT scan brain plain showing well-defined lesion in left temporoparietal region with evidence of hemorrhage, (b) Follow-up CT scan showing complete excision

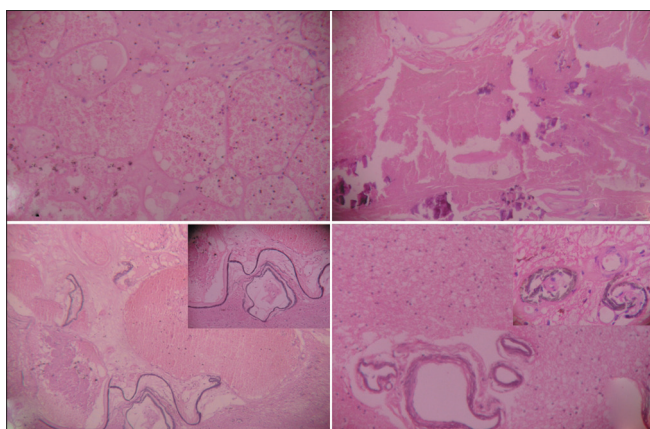


Figure 3: Photomicrograph of the specimen showing giant cavernous angioma with large ectatic endothelium-lined variable size vascular channels without mural muscular or elastic fibers embedded within a matrix of collagenous tissue. Also note the associated gliosis, calcification, and hemosiderin deposition in the surrounding neural parenchyma

adults in the third to fifth decade, and found most frequently in the white matter of the supratentorial compartment.^[4-7] Although the size of these lesions usually ranges from 9 to 20 mm,^[8] giant lesions also have been reported in the literature.^[1,3] As in adults, in children also, most commonly these lesions present with focal or generalized seizures followed by intracerebral bleeding from the cavernous angioma and focal deficits.^[4,6-9] However, these rare lesions can be clinically silent and it is attributed to their location in “silent” cortical areas, particularly in frontal lobe.^[1,6] Giant cavernomas have similar features as of average-sized cavernomas in clinical, surgical, or histopathological presentation, although these may differ radiologically.^[3] Giant cavernous angioma histologically consists of large ectatic endothelium-lined variable size vascular channels without mural muscular or elastic fibers embedded within a matrix of collagenous tissue lacking any neuronal elements.^[1,10] There is associated gliosis and hemosiderin deposition in the surrounding neural parenchyma and also there may be

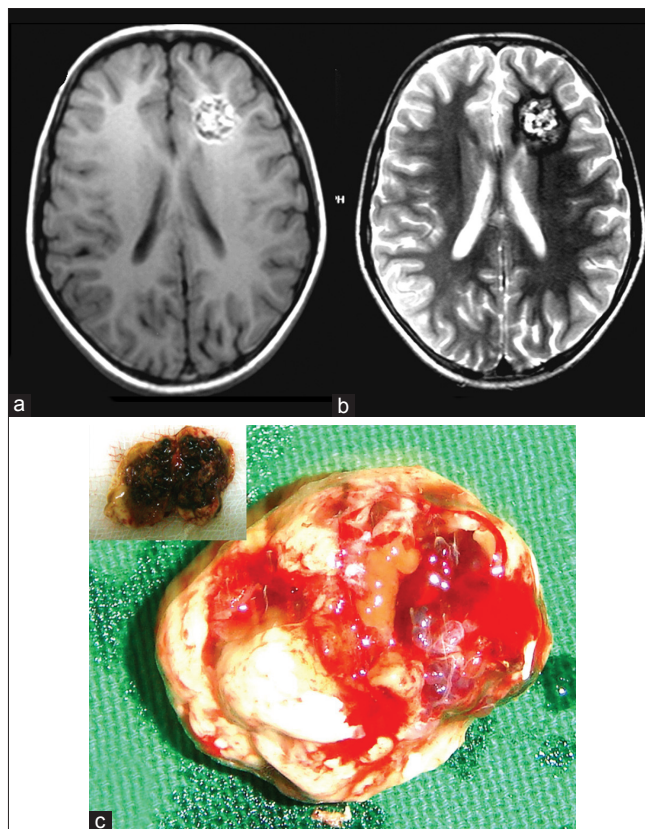


Figure 2: (a) and (b) MRI T1W, T2W axial images showing reticulated core of mixed signal representing blood in various states of degradation, note the hypointense halo due to hemosiderin on T2 W image (b), (c) Photograph of completely excised lesion with surrounding gliotic tissue

non-specific features such as calcification or thrombosis.^[11] Magnetic resonance is the investigation of choice for the diagnosis as well as for follow up of these lesions.^[1,2,4,8,12-14] As in present case, cavernous hemangiomas appear as a reticulated core of mixed signal representing blood in various states of degradation surrounded by a hypointense halo due to hemosiderin on T2-weighted MRI images [Figures 2 and 3].^[13,14] Complete extirpation of the lesion including giant cavernomas is the best treatment if the lesion is favorably located.^[1-4,6-9,12] It has been reported that following lesionectomy, the seizure outcome is excellent with improvement in seizure control majority of the cases^[5,6,8,9]; however, in patients with intractable seizures, the outcome may be less favorable.^[6]

References

1. de Andrade GC, Prandini MN, Braga FM. [Giant cavernous angioma: report of two cases]. *Arq Neuropsiquiatr* 2002;60:481-6.
2. Buckingham MJ, Crone KR, Ball WS, Berger TS. Management of cerebral cavernous angiomas in children presenting with seizures. *Childs Nerv Syst* 1989;5:347-9.
3. van Lindert EJ, Tan TC, Grotenhuis JA, Wesseling P. Giant cavernous hemangiomas: Report of three cases. *Neurosurg Rev* 2007; 30:83-92.
4. Seifert V, Trost HA, Dietz H. Cavernous angiomas of the supratentorial

- compartment. *Zentralbl Neurochir* 1989;50:89-92.
5. Giulioni M, Acciarri N, Padovani R, Frank F, Galassi E, Gaist G. Surgical management of cavernous angiomas in children. *Surg Neurol* 1994;42:194-9.
 6. Moran NF, Fish DR, Kitchen N, Shorvon S, Kendall BE, Stevens JM. Supratentorial cavernous haemangiomas and epilepsy: A review of the literature and case series. *J Neurol Neurosurg Psychiatry* 1999;66:561-8.
 7. Pozzati E, Padovani R, Morrone B, Finizio F, Gaist G. Cerebral cavernous angiomas in children. *J Neurosurg* 1980;53:826-32.
 8. Zamorano L, Matter A, Saenz A, Buciu R, Diaz F. Interactive image-guided resection of cerebral cavernous malformations. *Comput Aided Surg* 1997;2:327-32.
 9. Giulioni M, Acciarri N, Padovani R, Galassi E. Results of surgery in children with cerebral cavernous angiomas causing epilepsy. *Br J Neurosurg* 1995;9:135-41.
 10. Simard JM, Garcia-Bengochea F, Ballinger WE Jr, Mickle JP, Quisling RG. Cavernous angioma: a review of 126 collected and 12 new clinical cases. *Neurosurgery* 1986;18:162-72.
 11. McCormick WF. The pathology of vascular ("arteriovenous") malformations. *J Neurosurg* 1966;24:807-16.
 12. Maggi G, Aliberti F, Ruggiero C, Pittore L. Cerebral cavernous angiomas in critical areas. Reports of three cases in children. *J Neurosurg Sci* 1997;41:353-7.
 13. Rigamonti D, Drayer BP, Johnson PC, Hadley MN, Zabramski J, Spetzler RF. The MRI appearance of cavernous malformations (angiomas). *J Neurosurg* 1987;67:518-24.
 14. Sage MR, Brophy BP, Sweeney C, Phipps S, Perrett LV, Sandhu A, *et al.* Cavernous haemangiomas (angiomas) of the brain: clinically significant lesions. *Australas Radiol* 1993;37:147-55.

How to cite this article: Agrawal A, Banode P, Shukla S. Giant cavernous hemangiomas of the brain. *Asian J Neurosurg* 2012;7:220-2.

Source of Support: Nil, **Conflict of Interest:** None declared.