

CASE REPORT

Air embolism related to removal of Mayfield head pins

Hesham El-Zenati, Jafar Faraj, Ghaya Ibrahim Al-Rumaihi¹

Department of Anesthesia/ICU Pain and Palliative Care, ¹Department of Neurosurgery, Hamad Medical Corporation, PO Box 3050, Doha, Qatar

ABSTRACT

Venous air embolism (VAE) may be fatal and frequently carries high neurologic, respiratory, and cardiovascular morbidity. Its occurrence during anesthesia is challenging to the anesthesiologists in terms of early discovery and management. VAE during neurosurgical procedures especially in the sitting position is well known and usually prepared for it; however, VAE might happen unexpectedly as in this patient's case. A young patient underwent an exploratory pterional craniotomy for resection of subdural hematoma and head pins were used to stabilize the head. The surgery and anesthesia were uneventful; however, he developed a sudden cardiovascular collapse at the end of surgery and immediately after removal of the Mayfield pins.

Key words: Air embolism, head pins, Mayfield, neurosurgery

Introduction

Venous air embolism (VAE) is a predominantly iatrogenic complication that occurs when atmospheric gas is introduced into the systemic venous system, this medical condition was mostly associated with neurosurgical procedures conducted in the sitting position and to a lesser extent in surgeries on neck and lumbar spine.^[1] The association of VAE and Mayfield head pins in adult patients is very rare and might be underreported as the medical literature is scarce in this matter. Here we are describing a possible incidence of VAE after removal of head pins in an otherwise uneventful surgery and anesthesia.

Case Report

A 33 year old male after 2 weeks of the first surgery (burr hole) for subdural hematoma, he was presented again to ED with headache for 4 days, GCS 15, general condition good,

hemodynamically stable, no neurological deficit. He was admitted to High Dependency Unit for close observation.

All laboratory investigations were normal including CT scan, MRI, MRA, and cerebral angiography.

Under general anesthesia and invasively monitored, using Mayfield head pins, left pterional craniotomy approach and left temporal lobe subdural hematoma was evacuated. The patient was hemodynamically stable during surgery.

At the conclusion of surgery and immediately after removal of head pins, the blood pressure suddenly dropped from 144/94 mmHg to 60/30 mmHg and heart rate from 70 to 50 and associated with drop of the ETCO₂ from 32 to 27 mmHg, managed with O₂ 100%, Ephedrine 30 mg and IV fluid, his vital signs returned to normal values within 1-2 min. By the end of surgery, the endotracheal tube was removed and he was fully awake. Follow up CT scan showed clear brain and clinically with no neurological deficit.

Discussion

The application of the three prongs Mayfield head pins [Figure 1] is commonly used in neurosurgery to keep the head secured during the procedure; however, its use in the young pediatric population is generally not recommended because of the thinness of the skull and the risk of intracranial injury. In the older pediatric population, there are risks of skull fracture, epidural hematoma, and scalp laceration and air embolism.^[2-7] In adult patients, the reports of complications related to a three-prong head holder such as skull fracture and epidural hematoma^[8] specially air embolism are very rare;^[4,8] however,

Access this article online

Quick Response Code:



Website:

www.asianjns.org

DOI:

10.4103/1793-5482.106662

Address for correspondence:

Dr. Hesham El-Zenati, ABHSA and IC, Specialist, Fellow Neuroanesthesia Department of Anesthesia/ICU, Pain and Palliative Care Hamad Medical Corporation, PO Box 3050, Doha, Qatar
 E-mail: helzenati@hmc.org.qa

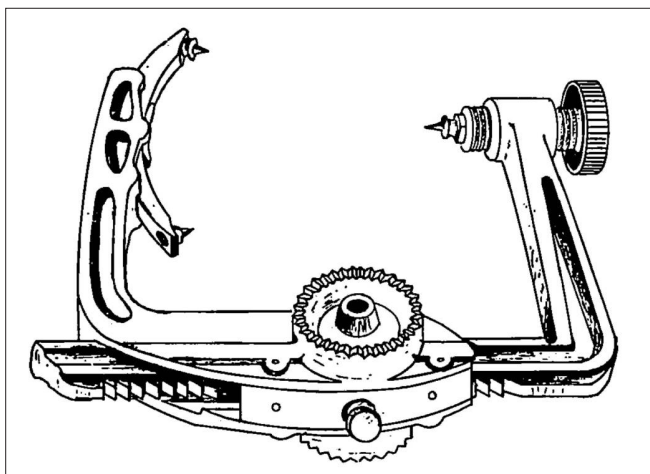


Figure 1: The three pins Mayfield Head clamp

it was long back noted that serious complications related to head pins may occur including air embolism.^[2]

The possibility of air embolism comes from the fact that the air is entrained to the venous diploic system and scalp veins at the site of the pins when they are removed and the head is at a higher level of the heart.

In our patient, we could not find any other good explanation for this sudden cardiovascular collapse except for the possibility of venous air embolism. The general management usually recommends the above mentioned one, i.e., Fi O₂ 100%, inotropes, and fluid load. Other measures such as discontinuation of N₂O (we don't use it in our Neuroanesthesia unit), manual occlusion of both jugular veins and head down position to reduce further sucking of air into the system

or aspiration of air through central venous line are all recommended too.

In the first surgery for this patient, Horse shoe was used otherwise we could have suspected the head pins as the cause of the second subdural hematoma.

References

1. Mirski MA, Lele AV, Fitzsimmons L, Toung TJ. Diagnosis and Treatment of Vascular Air Embolism. *Anesthesiology* 2007;106:164-77.
2. Baerts WD, de Lange JJ, Booij LH, Broere G. Complications of the Mayfield skull clamp, *Anesthesiology* 1984;61:460-1.
3. Grinberg F, Slaughter TF, McGrath BJ. Probable venous air embolism associated with removal of the Mayfield skull clamp. *Anesth Analg* 1995;80:1049-50.
4. Lee M, Rezai AR, Chou J. Depressed skull fractures in children secondary to skull clamp fixation devices. *Pediatr Neurosurg* 1994;21:174-7.
5. Pang D. Air embolism associated with wounds from a pin type head holder. Case report, *J Neurosurg* 1982;57:710-3.
6. Yan HJ. Epidural hematoma following use of a three-point skull clamp. *J Clin Neurosci* 2007;14:691-3.
7. Cabezedo JM, Gilsanz F, Vaquero J, Areitio E, Martinez R. Air embolism from wounds from a pin-type head-holder as a complication of posterior fossa surgery in the sitting position. *J Neurosurg* 1981;55:147-8.
8. Sade B, Mohr G. Depressed skull fracture and epidural hematoma: An unusual post-operative complication of pin headrest in an adult. *Acta Neurochir (Wien)* 2005;147:101-3.

How to cite this article: El-Zenati H, Faraj J, Al-Rumaihi GI. Air embolism related to removal of Mayfield head pins. *Asian J Neurosurg* 2012;7:227-8.

Source of Support: Nil, **Conflict of Interest:** None declared.