

CASE REPORT

Pearl in interhemispheric fissure: A rare phenomenon

Vivek Agarwal, Abhishek Vijayan, Vernon Velho, Rahul Mally

Department of Neurosurgery, Grant Medical College and Sir J. J. Group of Hospitals, Mumbai, India

ABSTRACT

Epidermoid cysts (Keratin pearls) are benign congenital lesions, found commonly in cerebello-pontine angle, suprasellar cistern, sylvian cistern, pineal region, but they are very rare in interhemispheric fissure. Approaching these lesions are challenging to neurosurgeons because of narrow and deep fissure with surrounding vital structures. The present study constitutes an analysis of interhemispheric epidermoid managed at our hospital in last 10 years (Jan 2001-Dec 2010). Total 187 cases of intracranial epidermoid operated in our institute; eight of them were interhemispheric epidermoid making about 4.27% of all epidermoids. The patients were presented with seizures (50%), headache (37%), and weakness (25%). On examination, the common findings were decreased Mini mental score (MMSE) in 50%, motor deficit in 25%, and decreased visual acuity in 25% of cases. All patients underwent craniotomy across the midline as per the location of the lesions. In seven patients, tumors were resected by interhemispheric approach but in one by transcortical. Lesion were excised with microscope and endoscopic assistance with measures to prevent spillage of epidermoid tissue while excision. Post excision tumor bed was irrigated with hydrocortisone diluted saline. All patients except one improved after surgery and non-developed chemical meningitis. One patient of parietal interhemispheric epidermoid with transcortical approach developed weakness in immediate post-operative period. Patients were followed for average 6.8 year without any recurrence. Interhemispheric epidermoids are rare tumors. Achieving safe complete excision without spillage is surgical goal to prevent chemical meningitis and recurrence. Endoscope assists in achieving complete excision so decrease incidence of chemical meningitis and recurrence

Key words: Epidermoid, chemical meningitis, interhemispheric

Introduction

Epidermoid cysts (Keratin pearls) are benign congenital lesions, found commonly in cerebello-pontine angle, suprasellar cistern, sylvian cistern, pineal region, but they are very rare in interhemispheric fissure.^[1] Approaching these lesions are challenging to neurosurgeons because of narrow and deep fissure with surrounding vital structures. We are reporting eight cases of interhemispheric epidermoid cysts operated in our hospital with emphasis on technical difficulties encountered.

Case Report

This study includes eight cases of epidermoid cyst, operated in Sir J.J. group of hospitals, Mumbai from 2000

to 2010. The patients were studied in terms of age and sex distribution, clinical presentation, site of tumor, management and complication with recurrence of the tumor.

Observation and Results

The present study constitutes an analysis of interhemispheric epidermoid managed at our hospital in the last 10 years (Jan 2001-Dec 2010). Total 187 cases of intracranial epidermoid operated in our institute; eight of them were interhemispheric epidermoid making about 4.27% of all epidermoids. The patients ranged from 16 years to 55 years of age with an average age of 31.11 years. There was male preponderance with male to female ratio of 2:1. The duration of symptoms ranged from 1 month to 20 years and common were seizures (50%), headache (37%), and weakness (25%). On examination, the common findings were decreased Mini mental score (MMSE) in 50%, motor deficit in 25%, and decreased visual acuity in 25% of cases.

Investigations

Computed tomography (CT) scan brain with contrast was done in 6 patients, which showed non enhancing, hypo dense lesion with irregular outline and specks of peripheral calcifications in two cases. Magnetic resonance imaging (MRI) was done in five cases, and was suggestive of non enhancing hypo intense lesion on T1W and hyper intense lesion on T2W

Access this article online

Quick Response Code:



Website:

www.asianjns.org

DOI:

10.4103/1793-5482.106663

Address for correspondence:

Dr. Vivek Agarwal, Department of Neurosurgery, Grant Medical College and Sir J. J. Group of Hospitals, Mumbai, India.
E-mail: neuro.vi@gmail.com

images with restriction pattern on diffusion studies. In one case, heterogeneous hypo intense lesion with area of hyper intensity to grey matter on both T1W and T2W images. This lesion was enhancing peripherally and turned out as infected epidermoid on histopathology.

Surgical Details with Technical Difficulties

All patients underwent craniotomy across the midline as per the location of the lesions. In seven patients, interhemispheric approach was taken to excise the lesion with retraction of right cerebral hemisphere from falx. But in one case of parietal epidermoid transcortical approach was taken because bridging veins were making retraction of cerebral hemisphere difficult [Table 1]. In one case, we encountered bleeding due to partial tear of bridging vein while tumor excision, we applied fibrin glue to achieve hemostasis instead of coagulation. In another two cases, space available even after retraction of cerebral hemisphere from falx was very small in comparison to lesion, so we used endoscope to remove the tumor from beginning. In rest of the cases, we used endoscope at the end of the procedure to remove the part of lesion not seen by microscope specially the part extending in to ventricles and crevices of cistern. In two cases, the part of the tumor capsule was adherent to anterior cerebral artery and was inseparable. Therefore, we left small tags of capsule over anterior cerebral artery and its branches. In all cases, on reaching the tumor surface, surrounding arachnoid was covered with cotton to avoid contamination with tumor tissue. Intratumoral debulking followed by dissection of the tumor capsule was done and post-excision tumor bed was

irrigated with hydrocortisone diluted fluid (100 mg in 500 ml fluid) till the returning fluid was clear. Perioperatively, patients were covered with steroid, which was gradually tapered off. In present series, total excision was achieved in 75% of cases and near-total in rest of the cases.

Functional Outcome

All the patients had shown neurological improvement post operatively except for one. The case where transcortical approach was taken had shown aggravation of left lower limb weakness which recovered over three months of follow-up. Seizures were controlled in all cases with anticonvulsant and in two cases the anticonvulsant was stopped after two years of seizure free follow-up, but the MMSE of the patients did not improve in follow-up. None of our interhemispheric epidermoid patient developed chemical meningitis in post operative period. Seven patients were in regular follow-up with average follow up of 6.8 years (follow-up ranged from 1 to 10 years). We have not encountered any recurrence during this period in any of the patient.

Discussion

Epidermoids are slow growing, benign congenital lesions constitute about 0.6-1.5% of all intracranial tumors.^[2] These tumors are believed to result from inclusion of the epithelial element within the neural groove. These inclusions may result in epidermoid cyst, dermoid cyst, or dermal sinus. The dermoid cysts are known for its midline location but epidermoids are common in lateral location. The lateral preferences of most of epidermoids are due to proliferation

Table 1: Site of tumors with approach and extent of excision

Part of fissure involved	No. of cases	Approach to tumor	Extent of excision T N/S
Anterior basal interhemispheric [Figure 1]	1	Interhemispheric	T
Anterior interhemispheric [Figures 2 and 3]	3	Interhemispheric	T-2, N-1
Fronto-parietal interhemispheric [Figure 4]	3	Interhemispheric	T-2, N-1
Parietal interhemispheric	1	Transcortical	T

T- Gross total excision; N- Near total excision; S – Subtotal excision

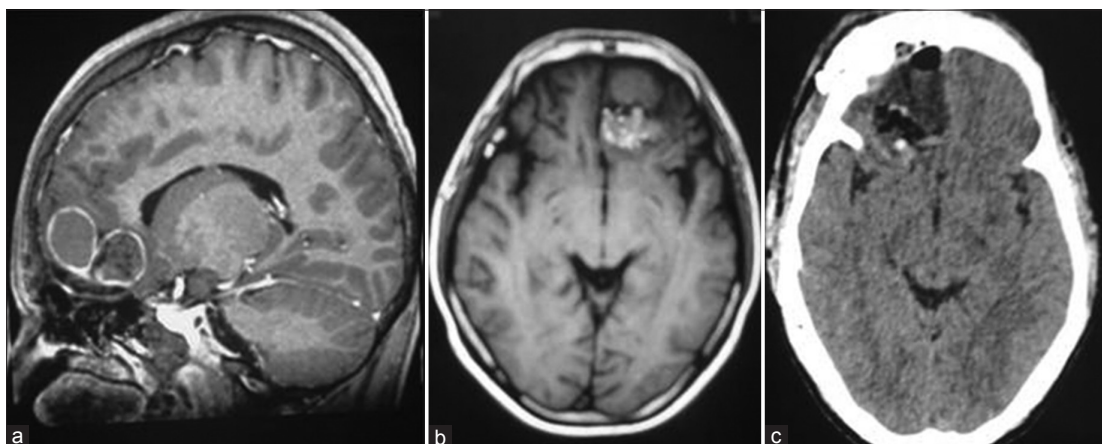


Figure 1: Anterior basal interhemispheric infected epidermoid

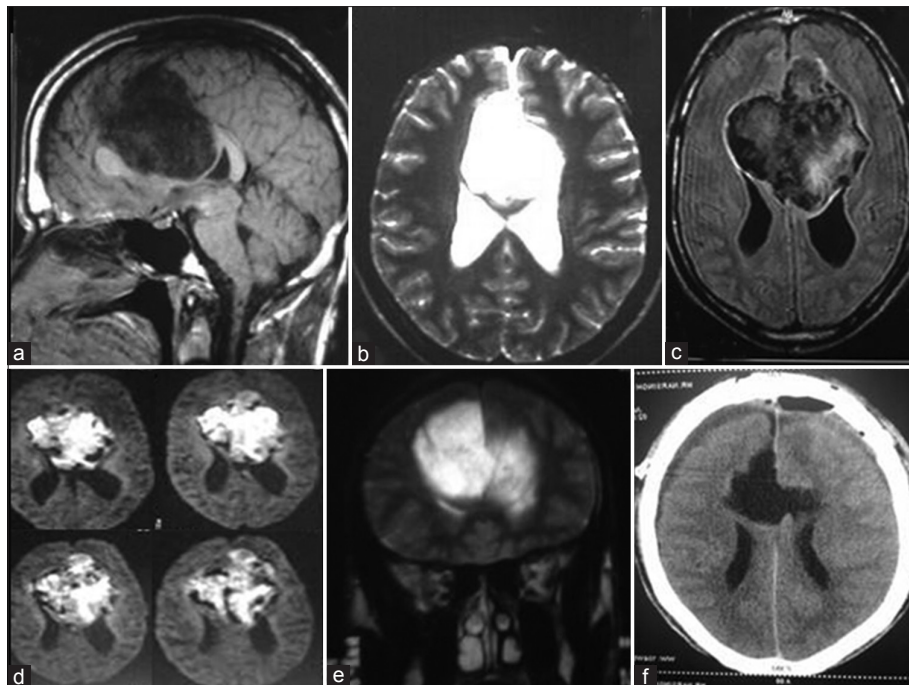


Figure 2: Anterior interhemispheric epidermoid

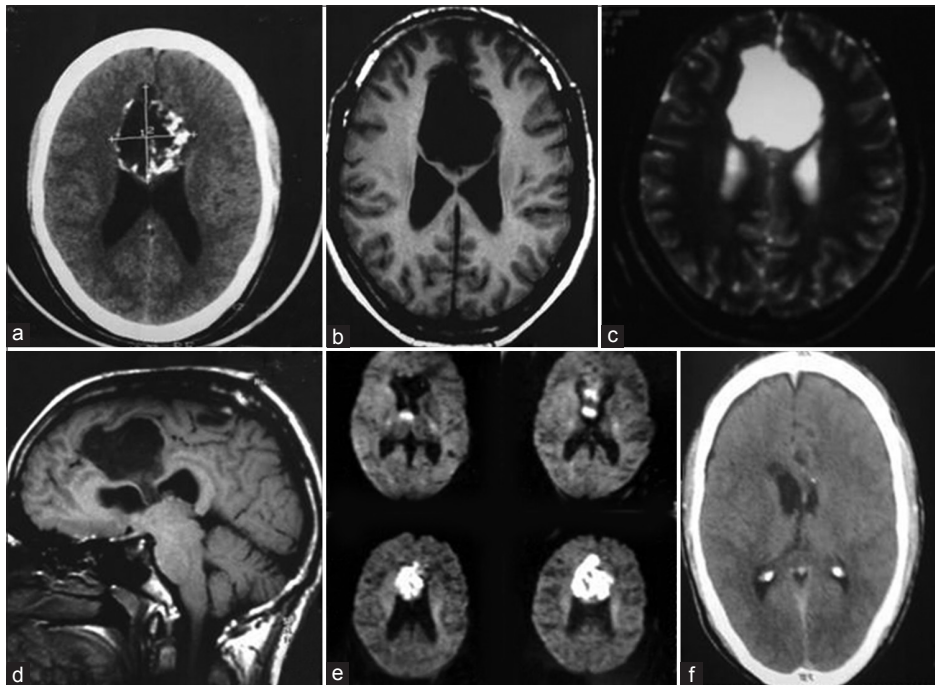


Figure 3: Interhemispheric epidermoid with intraventricular extension

of multipotential embryonic cell rests carried laterally with the migrating otic vesicle or developing neurovasculature.^[3] Therefore, interhemispheric epidermoids are very rare and till now total 34 case reports are available in literature to the best of our knowledge.^[4] Yassargil *et al.* described that majority of the epidermoids lie in one of the seven sites; anterosellar, parasellar, suprasellar, retrosellar/Cerebello-pontine angle, posterior fossa basal, intraventricular, mesencephalic/pineal but have not

included the interhemispheric.^[5] Common age of presentation in these tumors is between 30-40 years as seen in our series. In the present series, there was male predominance with male to female ratio 2:1 contrary to no gender preponderance in other series.^[6] These tumors are soft and slow growing so mould according to surrounding structures and seeps in the crevices of the cistern. Epidermoids grow and entrap rather than displace the neurovascular structures. Therefore, excision

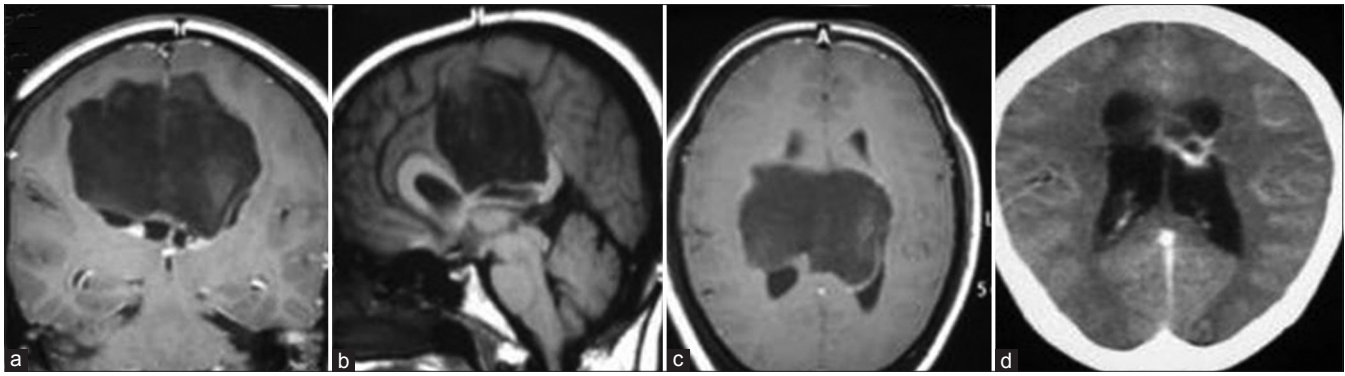


Figure 4: Fronto-parietal interhemispheric epidermoid

of these lesions which appears to be easy carries high chances of damage to nerves and vessels. Leak of epidermoid tissue from the capsule may results in inflammatory reaction with formation of thickened hyalinised and fibrous arachnoid membrane. This may lead to dense adhesions. If tumor capsule is adherent to neurovascular structures, it is preferable to leave a small tag of cyst lining rather than damaging vascular and neural structure like anterior cerebral artery or its branches in this region. Rupture or spillage of epidermoid tissue during excision may lead to severe chemical meningitis and up to 40% incidence is reported in various series. Complete isolation of the epidermoid from surrounding cistern with cotton, removal of the content followed by capsular dissection, gentle and complete removal of content without spillage, irrigation with diluted hydrocortisone fluid, and perioperative intravenous steroid reduce the chance of chemical meningitis.^[5,7,8] In our series, we have not encountered any case with chemical meningitis. The interhemispheric location of the lesion, bridging veins, proximity to the anterior cerebral arteries and motor cortex make their excision challenging. Bridging veins are of utmost importance as damage may lead to severe cerebral edema and infarct. We tried to save bridging veins either by changing the approach to transcortical or using endoscope. Even when bridging veins were partially damaged, we applied fibrin glue and surgical instead of coagulation. Common causes for recurrence in these tumors are incomplete tumor removal and spillage of tumor tissues in subarachnoid space. The growth of epidermoid tumors is one generation per month, essentially the turn over time of normal human skin. But re-excision of these lesions is difficult so effort should be made to achieve complete and safe excision. In all of our cases, we used endoscope after microscopic excision to remove residual tumor from crevices of the cistern and tumor bed was irrigated to clear the surrounding cistern. In spite of small tags of capsule left behind in two cases over the anterior cerebral

artery, we have not encountered any recurrence on average follow up of 6.4 years with annual MRI, but this may be short period of follow up for recurrence.

Conclusion

Interhemispheric epidermoids are rare tumors. Achieving safe complete excision without spillage is surgical goal to prevent chemical meningitis and recurrence. Endoscope assists in achieving complete excision so decrease the incidence of chemical meningitis and recurrence.

References

1. Baykal S, CaKir E, Akturk F, Sari A, Kuzevli K, Karakus M. Epidermoid tumor of the interhemispheric fissure. *Neurosurg Rev* 1997;20:63-6.
2. Ulrich J. Intracranial Epidermoids. A Study on Their Distribution and Spread. *J Neurosurg* 1964;21:1051-8.
3. McLendon RE. Epidermoid and Dermoid tumors: Pathology. In: Wilkins RH, Rengachary SS, editors. *Neurosurgery*. New York: McGraw-Hill; 1996. p. 959-63.
4. Bhat DI, Devi BI, Raghunath A, Somanna S, Chandramouli BA. Interhemispheric epidermoids-an uncommon lesion in an uncommon location: A report of 15 cases. *Neurol India* 2011;59:82-6.
5. Yarasgil MG, Abernathy CD, Sarioglu AC. Microsurgical treatment of intracranial dermoid and epidermoids tumors. *Neurosurgery* 1989;24:561-7.
6. Desai KI, Nadkarni TD, Fattepurkar SC, Goel AH. Pineal epidermoid cysts: A study of 24 cases. *Surg Neurol* 2006;65:124-9.
7. Samii M, Tatagiba M, Piquer J. Surgical treatment of epidermoid cysts of the cerebellopontine angle. *J Neurosurg* 1996;84:14-9.
8. Akar Z, Tanriover N, Tuzgen S, Kafadar AM, Kuday C. Surgical Treatment of Intracranial Epidermoid Tumors. *Neurol Med Chir* 2003;4:275-81.

How to cite this article: Agarwal V, Vijayan A, Velho V, Mally R. Pearl in interhemispheric fissure: A rare phenomenon. *Asian J Neurosurg* 2012;7:229-32.

Source of Support: Nil, **Conflict of Interest:** None declared.