

Automated end-to-side anastomosis to the middle cerebral artery with C-Port xA: A feasibility study on human cadavers

Marco Fontanella^{1,2}, Chiara Benevello², Pier Paolo Panciani^{1,2}, Gabriele Ronchetti¹, Susanna Bacigaluppi², Roberto Stefini¹, Giannantonio Spena¹, Diego Garbossa², Alessandro Ducati²

¹Department of Neuroscience, Division of Neurosurgery, University of Brescia, ²Department of Neuroscience, Division of Neurosurgery, University of Turin, Italy

ABSTRACT

Background: Anastomosis to the superficial temporal artery is suitable in patients with functional and structural impairment of the middle cerebral artery (i.e., complex aneurysms and skull base tumors), as either definitive treatment or an additional safety measure. A shorter occlusion time or a non-occlusive technique is expected to reduce the risk of cerebral ischemia following the procedure. In this cadaver study, we assessed the fitness of C-Port xA[®] device for use in superficial temporal artery (STA)–middle cerebral artery (MCA) bypass.

Materials and Methods: Seven fixed human head specimens were prepared through eight pterional craniotomies. The superficial temporal artery was dissected and the sylvian fissure was opened to access the MCA. The C-Port xA was tested on each of the eight exposures. We recorded the lengths of both donor and recipient vessel, the durations of the procedure and the craniotomy, and sylvian scissure opening sizes. The bypass was then assessed by pressure injection of methylene blue in the donor vessel.

Results: C-Port xA-assisted STA–MCA anastomosis was successfully accomplished in seven dissections. A minimum STA length of 7 cm, a sylvian scissure opening larger than 5 cm, and a craniotomy size of at least 6 × 6 cm appeared to be the requisites for a safe maneuverability of the device. The MCA occlusion time lasted in all cases less than 4.5 min, and we observed a clear improvement in time performance with growing experience.

Conclusions: The results suggest that the C-Port xA device is suitable for STA–MCA bypass. We experienced a shorter occlusion time and a shorter learning curve compared to conventional techniques. Further miniaturization and special adaptation of this device may allow a future application even to deeper intracranial vessels. Clinical trials will have to assess the long-term results and benefits of this minimal occlusive technique.

Key words: Automated end-to-side anastomosis, bypass, human cadavers, middle cerebral artery, superficial temporal artery

Introduction

Cerebral revascularization by extracranial–intracranial (EC–IC) bypass is primarily indicated in patients with intracranial steno-occlusive disease.^[1] Moreover, this technique plays

an important role in the treatment of cerebrovascular and neoplastic lesions when internal carotid artery (ICA) occlusion is required but the collateral flow is inadequate.^[2] Conventional neurosurgical bypass, minimally occlusive and non-occlusive techniques are the current tools for achieving the purpose.

Standard anastomosis is time-consuming and requires a middle cerebral artery (MCA) occlusion, usually from 20 to 45 min.^[2–4] On the other hand, the excimer laser-assisted non-occlusive anastomosis (ELANA) technique enables large-caliber bypass revascularization without temporary occlusion of the parent artery.^[5] Nevertheless, its morbidity and mortality rates are similar to those of conventional high-flow revascularization series, and a meticulous and costly procedure is required.^[6]

Several strategies aimed to improve the feasibility of the ELANA technique have been proposed.^[7,8] Recently, a distal anastomosis system, named C-Port xA[®] (Cardica, Inc., Redwood

Access this article online	
Quick Response Code:	Website: www.asianjns.org
	DOI: 10.4103/1793-5482.116377

Address for correspondence:

Dr. Pier Paolo Panciani, Department of Neuroscience, Division of Neurosurgery, University of Brescia, Italy. E-mail: pierpaolo.panciani@gmail.com

City, CA, USA), has been borrowed from coronary artery bypass surgery^[9] and tested in high-flow EC–IC anastomoses.^[1,10,11]

The aim of this study was to perform superficial temporal artery (STA)–MCA assisted bypasses on human cadavers and to analyze them in order to assess a possible use of the C-Port xA system in the current surgical practice.

Materials and Methods

Seven adult cadaveric specimens of both sexes were used to perform eight bypasses. The carotid and vertebral arteries were injected with red silicone, and the internal jugular veins with blue. The heads were fixed and preserved with formaldehyde, and were positioned in a holder system to simulate the setting of a standard fronto-temporal approach. Microsurgical dissections were performed under an operating microscope with a $\times 4$ to $\times 40$ magnification.

The heads were shaved so as to allow a wide clean access; then the skin flap was incised and fixed to prevent movements during the following procedure. The STA was identified and sharply dissected as long as possible in its highly variable anatomical course. The length of dissection was measured in each procedure. The artery diameter was also measured to verify the compatibility with the use of C-Port xA, as vessels thinner than 1.4 mm are not amenable to anastomosis using this device. Once the STA was isolated, the temporal muscle was dissected from the root of the zygomatic arch to the posterior frontal region. Standard pterional craniotomy was performed in every specimen, and its size was measured.

The dura mater was incised with a C shape, and the sylvian fissure was widely opened to prevent damage to the brain parenchyma during the deploying of the device. After recognition of the proximal MCA (M1), the segment between its first and second branches (M2) was identified, carefully dissected, and measured.

An STA–M2 mechanical anastomosis was created in all cases with the C-Port xA system. The latter device allows performing automated and rapid end-to-side anastomosis (it is designed for single use only). The system was prepared by activating the CO₂ cartridge that serves as the energy source. The STA was attached to the C-Port xA deployment device and cut between the two cartridge arms [Figure 1]. A small incision was then made on M2 wall to insert the anvil. Pressure over the system trigger activated the cartridge closure on M2 [Figure 2], followed by deployment of 13 staples which circumferentially connected the STA to M2 [Figure 3]. The anastomosis capacity was in every case assessed by injecting methylene blue in the STA through an insulin needle and checking the absence of any leakage.

Results

In all the specimens [Table 1], the STA diameters appeared large enough (more than 1.4 mm) to be positioned on the

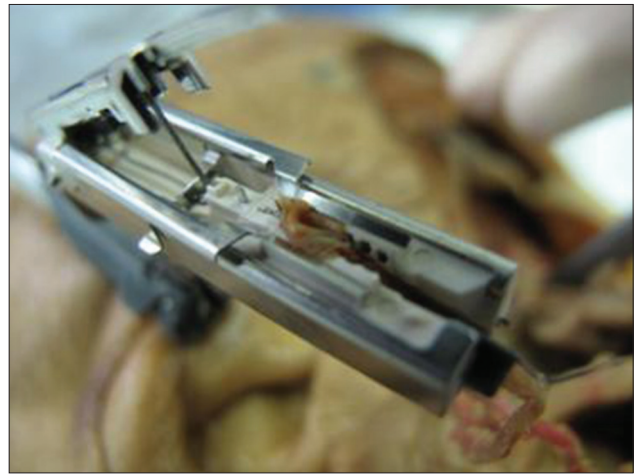


Figure 1: STA dissected and placed in the device guide

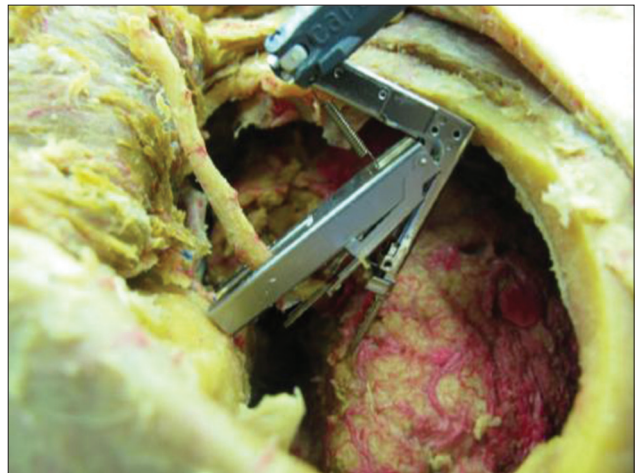

Figure 2: STA connected to M2 by C-Port xA® system

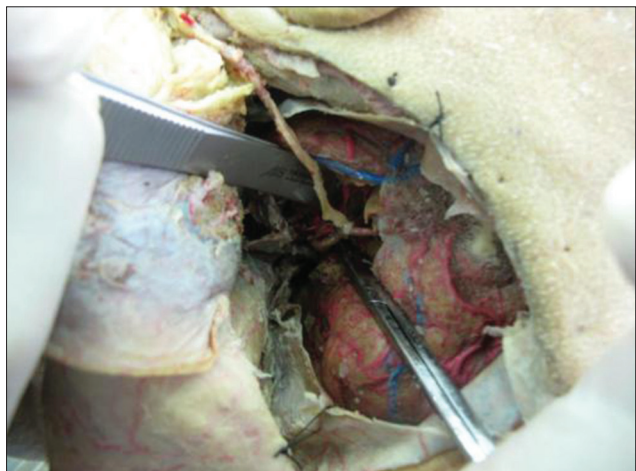


Figure 3: STA–MCA bypass performed using the device

cartridge and to allow the functioning of the C-Port xA system. The length of the STA dissected segment varied from 5 to 10 cm (mean 6.7 cm), depending on the different positions of the bifurcation and on the various skull shapes.

Table 1: Measurements obtained in the study

Specimen	Dissected STA (cm)	Length M2 (cm)	Sylvian fissure dissection (cm)	Craniotomy's size (cm)	Operative time
1	5	3	4	7×5	4'30"
2	7	2	5	7×8	4'20"
3	7	3	5	7×6	3'15"
4	10	3	5	6×8	3'30"
5	6	2	5	6×6	3'00"
6	6	2	5	7×10	2'30"
7	6	1,5	4	5×6	4'15"
8	6,5	2	5	7×8	2'30"

In case 7 the small craniotomy caused great difficulties during the procedure, as shown by the long operative time

In all but one case, the STA dissected part was longer than 6 cm and it was possible to link it to the M2 segment of MCA. In these cases, a 5-cm sylvian scissure opening allowed the system application without gross damage to the surrounding brain tissue. In the only specimen where the above STA critical length of 6 cm was not achieved, the artery did not reach the M2 segment and the anastomosis was then performed using a more distal and superficial cortical branch of MCA as the recipient vessel.

In all the exposures, the MCA M2 segment was easily accessible and allowed to use the C-Port xA. The length of the dissected M2 part ranged from 1.5 to 3 cm and its diameter appeared always larger than 1.3 mm, the minimum required for the device to work.

We deliberately performed craniotomies of different sizes to assess the feasibility of the procedure in relation to the available working space. The sizes ranged from a minimum of 5 × 5 cm to a maximum of 7 × 10 cm. The use of C-Port xA appeared functional with a craniotomy of at least 6 × 6 cm. The attempt made with a smaller access (5 × 5 cm) led to great difficulty in lodging the cartridge and poor maneuverability during the procedure. Moreover, the smaller craniotomy specimen was the only one requiring additional stitches once the C-Port xA procedure was finished, as in the other cases the anastomosis appeared immediately complete. The bypass procedure lasted in all the specimens less than 4 min and 30 sec, and the pressure injection of methylene blue in the donor vessel showed a final correct anastomosis in every case.

Discussion

In case of giant intracranial aneurysm rupture^[2,12,13] and of several skull base tumors, surgery may require the packaging of an EC-IC bypass. The standard technique is challenging and usually requires a long ICA occlusion time that frequently leads to neurological impairment.^[14] Therefore, a technique that may allow to reduce the surgical time, especially in elderly,^[15] could be really useful.

The C-Port xA system is relatively simple to use, and in this study allowed the creation of a complete STA-MCA anastomosis in all the human cadaver heads tested. In the totality of the specimens, it was possible to load the STA on the operating cartridge of the device. The M2 (7 cases) and distal MCA (1 case) as well appeared adequate recipient vessels for the procedure, with a sufficient length and a diameter larger than the minimum required for using the assisting device.

We found that a dissected STA of 7 cm or longer allowed to easily reach the ipsilateral M2 segment. In cases where the STA had a length of 6 cm, it was technically possible to connect it to M2, but with visible problems in the construct mobility and consequent stretch of the anastomosis, and probable lower safety of the procedure. In the only case with a 5-cm STA, it appeared impossible to link it to M2, but the C-Port xA system allowed anyway to perform a successful more distal anastomosis.

The minimum sylvian fissure dissection for a proper lodging of the working cartridge appeared to be 5 cm. In the STA-M2 bypass performed through a shorter sylvian opening (4 cm), damage to the cerebral tissue occurred. This study showed also that a large craniotomy (approximately 6 × 6 cm) is required for a better maneuverability of the device. In the specimen with a smaller craniotomy, in fact, it appeared difficult to lodge the cartridge in the correct way, leading to an incorrect anastomosis.

The C-Port xA assisted technique has a definite learning curve, with a performance time decreasing significantly with experience. The lengths of our assisted anastomoses were anyway markedly lower than those reported in the literature for traditional manual procedures. Therefore, the system allows to significantly reduce the time of occlusion during surgery.

The device used in our study can potentially be modified to get further improvements. A smaller system would simplify the use of other MCA branches as recipient vessels, as the STA length is not always sufficient to reach the M2 segment, and may lower the risk of collision with surrounding structures.

Further experience and studies are needed to clarify the real advantages of this procedure compared to the standard operation. As a matter of fact, data concerning long-patency rates and postoperative complications, as hyperperfusion syndrome or formation of *de novo* aneurysms, are required to assess the effectiveness of this technique.

Conclusions

The C-Port xA system seems to offer an easy and systematic solution to overcome the known technical difficulty of manual anastomosis. Due to shorter temporary occlusion times, this device might reduce the occurrence of ischemic stroke

in the territories of the operated arteries. Furthermore, the occlusion time and the overall final success of the procedure are less dependent on the operator's experience compared to conventional anastomoses.


References

- Hänggi D, Reinert M, Steiger HJ. C-Port Flex-A–assisted automated anastomosis for high-flow extracranial-intracranial bypass surgery in patients with symptomatic carotid artery occlusion: A feasibility study. *J Neurosurg* 2009;111:181-7.
- Jafar JJ, Russell SM, Woo HH. Treatment of giant intracranial aneurysms with saphenous vein extracranial-to-intracranial bypass grafting: Indications, operative technique, and results in 29 patients. *Neurosurgery* 2002;51:144-6.
- Mohit AA, Sekhar LN, Natarajan SK, Britz GW, Godke B. High-flow bypass grafts in the management of complex intracranial aneurysms. *Neurosurgery* 2007;60:105-22.
- Quiñones-Hinojosa A, Du R, Lawton MT. Revascularization with saphenous vein bypasses for complex intracranial aneurysms. *Skull Base* 2005;15:119-32.
- Langer DJ, Van Der Zwan A, Vajkoczy P, Kivipelto L, Van Doormaal TP, Tulleken CA. Excimer laser-assisted nonocclusive anastomosis. An emerging technology for use in the creation of intracranial-intracranial and extracranial-intracranial cerebral bypass. *Neurosurg Focus* 2008;24:E6.
- Vajkoczy P, Korja M, Czabanka M, Schneider UC, Reinert M, Lehecka M, *et al.* Experience in using the excimer laser-assisted nonocclusive anastomosis nonocclusive bypass technique for high-flow revascularization: Mannheim-helsinki series of 64 patients. *Neurosurgery* 2012;70:49-55.
- van Doormaal TP, van der Zwan A, Verweij BH, Biesbroek M, Regli L, Tulleken CA. Experimental simplification of the excimer laser-assisted nonocclusive anastomosis (ELANA) technique. *Neurosurgery* 2010;67:283-90.
- Alfieri A, Reinert M. Glue-enhanced excimer laser-assisted nonocclusive anastomosis: A laboratory investigation. *Eur Surg Res* 2011;46:32-7.
- Matschke KE, Gummert JF, Demertzis S, Kappert U, Anssar MB, Siclari F, *et al.* The cardica C-Port system: Clinical and angiographic evaluation of a new device for automated, compliant distal anastomoses in coronary artery bypass grafting surgery: A multicenter prospective clinical trial. *J Thorac Cardiovasc Surg* 2005;130:1645-52.
- Bregy A, Alfieri A, Demertzis S, Mordasini P, Jetzer AK, Khulen D, *et al.* Automated end-to-side anastomosis to the middle cerebral artery: A feasibility study. *J Neurosurg* 2008;108:567-74.
- Dacey RG, Zipfel GJ, Ashley WW, Chicoine MR, Reinert M. Automated, compliant, high-flow common carotid to middle cerebral artery bypass. *J Neurosurg* 2008;109:559-64.
- Paulo MS, Edgardo S, Fernando M, Pablo P, Alejandro T, Verónica V. Aneurysms of the middle cerebral artery proximal segment (M1). Anatomical and therapeutic considerations. Revision of A Series. Analysis of a series of the pre bifurcation segment aneurysms. *Asian J Neurosurg* 2010;5:57-63.
- Pagni CA, Fontanella M, Cossandi C, Griva F, Zullo N, Bradac GB. Therapeutic decisions and grading of subarachnoid hemorrhage. *Minerva Anesthesiol* 1998;64:159-62.
- Bacigaluppi S, Fontanella M, Manninen P, Ducati A, Tredici G, Gentili F. Monitoring techniques for prevention of procedure-related ischemic damage in aneurysm surgery. *World Neurosurg* 2011.
- Bradac GB, Bergui M, Fontanella M. Endovascular treatment of cerebral aneurysms in elderly patients. *Neuroradiology* 2005;47:938-41.

How to cite this article: Fontanella M, Benevello C, Panciani PP, Ronchetti G, Bacigaluppi S, Stefani R, *et al.* Automated end-to-side anastomosis to the middle cerebral artery with C-Port xA: A feasibility study on human cadavers. *Asian J Neurosurg* 2013;8:74-7.

Source of Support: Nil, **Conflict of Interest:** None declared.

Announcement



Download
**iPhone, iPad
application**

FREE

A free application to browse and search the journal's content is now available for iPhone/iPad. The application provides "Table of Contents" of the latest issues, which are stored on the device for future offline browsing. Internet connection is required to access the back issues and search facility. The application is Compatible with iPhone, iPod touch, and iPad and Requires iOS 3.1 or later. The application can be downloaded from <http://itunes.apple.com/us/app/medknow-journals/id458064375?ls=1&mt=8>. For suggestions and comments do write back to us.