

## CASE REPORT

# Large primary intraorbital hydatid cyst in elderly

Veeresh U. Mathad, Hukum Singh, Daljit Singh, Manoj V. Butte, M. Kaushik<sup>1</sup>

Departments of Neurosurgery and <sup>1</sup>Pathology, Maulana Azad Medical College and G.B. Pant Hospital, New Delhi, India

## ABSTRACT

We report a case of solitary, primary intraorbital hydatid cyst in an elderly female aged 80 years who presented with nontender, nonpulsatile proptosis of left eye with diminution of vision. MRI scan of the head and the orbits, revealed a retro-bulbar cyst. Surgical excision was performed by employing a lateral orbitotomy approach. Histopathology report confirmed hydatid cyst.

**Key words:** Hydatid cyst, lateral orbitotomy, proptosis

## Introduction

Hydatid disease (hydatidosis) is a zoonotic condition caused by the larva of *Echinococcus granulosus* or *Echinococcus multilocularis*. The incidence of orbital infestation is less than 1%. Most of the published literature has documented more prevalence in the younger patient. We report the first case in the world of orbital hydatid in a patient of 80 year age.

## Case Report

An 80-year-old female resident of Delhi was admitted to the hospital with 6 months history of proptosis of left eye and gradual diminution of vision in the same eye. The general physical examination showed no evidence of any neurocutaneous markers or swelling over the body. The neurological examination revealed proptosis of left eye with restricted movements in all directions. Visual acuity was only perception of light in left eye. There was no evidence of chemosis, redness in the eye. There was no bruit on auscultation.

Magnetic resonance imaging (MRI) brain and orbit revealed a well-margined cystic lesion in the left orbital apex. The lesion was located supero-laterally displacing optic nerve medially. The lesion was hypointense on T1 and

hyperintense on T2 image without any septations or scolex [Figure 1]. Approximate dimension of the lesion was 3 cm × 3 cm × 2 cm. There was mild rim enhancement after contrast administration. Based on the MRI the differential diagnosis of hydatid cyst, neurocysticercosis, dermoid, lipodermoid, mucocele, encephalocele, inclusion cyst, teratoma, hematocele, schwannoma and paraganglioma were considered. The serological test for hydatid and neurocysticercosis were negative. Erythrocyte sedimentation rate was 10 mm at the end of 1<sup>st</sup> h, total leukocyte count-5600/cmm, differential leukocyte count: P-70%, L-20%, M-5%, E-5%. Computed tomography (CT) scan of the chest and abdomen were unremarkable.

Patient underwent left lateral orbitotomy and gross total removal of cyst without rupture.

On macroscopic examination of the excised cyst wall a pearly white membranous tissue was appreciated, characteristic of hydatid cyst, measuring 3 cm × 3 cm and 0.2 cm thickness [Figure 2]. Histological examination of multiple longitudinal strips from the cyst wall revealed pale eosinophilic acellular laminated membranes lined by germinal epithelium, along with multiple scolices, confirming the diagnosis of ocular hydatid disease [Figure 3]. The scolices were seen to contain an array of refractile sickle-shaped hooklets.

The proptosis settled in the immediate post-operative period and there were some improvement in the eye movements. Patient had visual acuity of finger counting at 1 m at the time of discharge.

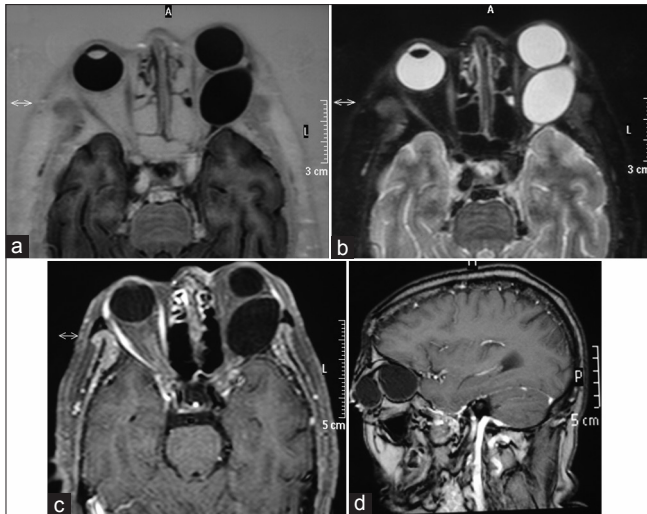
## Discussion

Orbital hydatid cyst is a rare condition. The causative organism of an orbital hydatid cyst is *E. granulosus* or *E. multilocularis*. The liver (60%) and lungs (20%)<sup>[1-3]</sup> are most commonly affected organs. Parasite can reach every organ or tissue in the body via the portal and systemic circulations.<sup>[4]</sup> The orbit is among

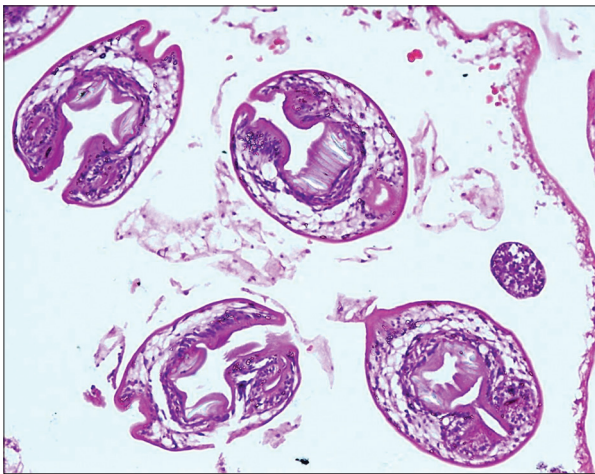
Access this article online	
Quick Response Code:	Website: www.asianjns.org
	DOI: 10.4103/1793-5482.121691

### Address for correspondence:

Dr. Veeresh U. Mathad, Room No. 607, 6<sup>th</sup> Floor NRDH, G.B. Pant Hospital, New Delhi, India. E-mail: veeresh.u.m@gmail.com



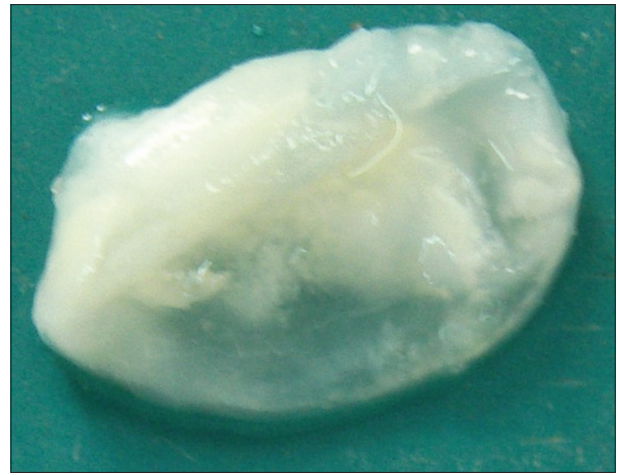
**Figure 1:** MRI orbit and brain showing the cystic lesion, almost of the same size as that of eye ball, located in the posterolateral part of the left orbit. (a) The cyst is hypointense in axial T1; (b) hyperintense in axial T2; (c) displacing the optic nerve medially and showing thin rim enhancement without scolex on axial T1 with contrast and; (d) sagittal T1 with contrast



**Figure 3:** Pale eosinophilic acellular laminated membrane bordered by paucicellular germinal epithelium, with scolices (center); note the refractile hooklets within the scolices (H and E, x200)

the uncommon sites of infestation. It has been stated that 1% of all hydatid cysts are localized in the orbit.<sup>[1,4,5]</sup> This is the first case presented that contains such a large diameter of the cyst, to the best of our our knowledge in an elderly patient.

The diagnostic work-up of orbital hydatid cyst includes, serological tests, orbital ultrasound, CT and MRI. Many serological tests can be used in diagnosis of Echinococcosis, but in orbital hydatidosis they usually give negative results.<sup>[6]</sup> The Cassoni's intradermal (ID) test, counter immune-electrophoresis, double diffusion test and indirect hemagglutination test have been used. The sensitivity of ID is 96% in liver, 90% in lung, whereas 77% in orbit, which is lower than other organs. This is due to integrity



**Figure 2:** Excised cyst showing the characteristic pearly white membranous appearance of cyst wall

of orbital cysts, lack of protoscolices and hence that the parasite remains encysted in the orbit. This makes the radiological examination more important for pre-operative diagnosis. Pre-operative diagnosis is important in order to avoid complications such as rupture during surgery, severe allergic and anaphylactic reactions, seeding, dissemination and recurrence of disease. On orbital ultrasonography cyst appears as unilocular, well circumscribed anechoic lesion with absent "water lily" sign.<sup>[7]</sup> On CT, lesion is hypodense, unilocular, well-defined, thin walled, homogenous mass with hyperdense rim and capsular enhancement seen.<sup>[8]</sup> On orbital MRI, cyst shows low intensity signal in T1, high intensity in T2 with contrast enhancement of capsule.<sup>[9]</sup> MRI is more superior to CT because it may give more detailed information about nature of cyst contents and its relationship to the surrounding structures.

The surgical removal without rupture is the only cure for orbital hydatid cyst, but this is not possible in all cases because of the anatomical complexity of orbital cavity, restricted area and thin wall of cysts. In our case, we removed the cyst without rupture, it was possible because of wide exposure by lateral orbitotomy (cyst was located superolaterally) and meticulous microsurgical dissection without much handling of the cyst wall. Two main approaches to expose the intraorbital lesion have been described-transcranial and extracranial. Each approach carries certain advantages and disadvantages. The factors dictating the most suitable approach are size of cyst, its anatomic location in orbit, its extension into the cranial cavity, patient's general condition, extent of disease and surgeon's familiarity with each surgical approach.

Transcranial approaches include-frontal craniotomy, fronto-temporal craniotomy, fronto-temporo-orbito-zygomatic approach. Transcranial approach is suitable for lesions with intracranial extension and superior lesions extending behind the optic nerve. Extracranial approaches include-lateral

orbitotomy (Kronlein-Berke approach), extended lateral orbitotomy and inferior orbitotomy. Lateral orbitotomy is the most commonly used approach to treat orbital hydatid cyst located in lateral compartment of orbit. Other less common procedures described in literature for orbital hydatid cyst are percutaneous treatment,<sup>[10]</sup> transmaxillary approach<sup>[11]</sup> for cyst located inferiorly in muscle cone, endo-cystectomy<sup>[12]</sup> with or without scolicalid agent, cryoextraction<sup>[13]</sup> of inner germinal layer and endoscopic endonasal approach.<sup>[4]</sup>

Per-operative instillation of various scolicalid solutions have been mentioned in the literature, but the safe solutions are 15% hypertonic saline, 30% hydrogen peroxide, 0.5% cetrimide, 0.5% silver nitrate or 95% ethanol. Scolicalid solution is instilled before opening the cavity to kill the daughter cysts and thus prevents anaphylactic reactions and further spread or seeding of cyst. If cyst accidentally ruptured, *in situ* irrigation with hypertonic saline should be performed. It is better to cover the area surrounding the cyst and exposed optic tissue with hypertonic saline soaked cottonoids before beginning the dissection and cyst removal. Chemotherapy with albendazole or mebendazole is used pre-operatively to reduce the size of big cyst, in cases of intraoperative rupture of cyst and in inoperable cases of Echinococcosis like multiple cerebral hydatid cysts.<sup>[14]</sup>

In the majority of reported cases age has a definitive role in determining the site of localization of hydatid cyst. Mean age of orbital hydatid cyst has been found to be 16 years. There is only one report of orbital hydatid encountered in a patient of 60 years.<sup>[15]</sup> Hostage seems to play a major role in organ localization, by altering the anatomical, physiological or immunological characteristics of the host, thus affecting the host-parasite relationship and favoring the cyst development in certain locations more than others.<sup>[14]</sup>

## References

1. Alparslan L, Kanberoğlu K, Peksayar G, Cokyüksel O. Orbital hydatid cyst: Assessment of two cases. *Neuroradiology* 1990;32:163-5.
2. Benjelloun A, Essodegui F, Ksiyer M. Orbital hydatid cyst. *Apropos of a case. Ann Radiol (Paris)* 1996;39:131-4.
3. Ghosh A, Saha S, Jha A, Chandra S. Orbital hydatid cyst - A rare case report. *Indian J Otolaryngol Head Neck Surg* 2008;60:191-3.
4. Turgut AT, Turgut M, Koşar U. Hydatidosis of the orbit in Turkey: Results from review of the literature 1963-2001. *Int Ophthalmol* 2004;25:193-200.
5. Ergün R, Okten AI, Yüksel M, Gül B, Evliyaoglu C, Ergüngör F, *et al.* Orbital hydatid cysts: Report of four cases. *Neurosurg Rev* 1997;20:33-7.
6. Gomez Morales A, Croxatto JO, Crovetto L, Ebner R. Hydatid cysts of the orbit. A review of 35 cases. *Ophthalmology* 1988;95:1027-32.
7. Hanioglu S, Saygi S, Yazar Z, Saltik G, Gürsel E. Orbital hydatid cyst. *Can J Ophthalmol* 1997;32:334-7.
8. Sperryn CW, Corr PD. CT evaluation of orbital hydatid disease: A review of 10 cases. *Clin Radiol* 1994;49:703-4.
9. Lerner SF, Gomez Morales A, Croxatto JO. Hydatid cyst of the orbit. *Arch Ophthalmol* 1991;109:285.
10. Akhan O, Bilgiç S, Akata D, Kiratli H, Ozmen MN. Percutaneous treatment of an orbital hydatid cyst: A new therapeutic approach. *Am J Ophthalmol* 1998;125:877-9.
11. Selçuklu A, Oztürk M, Külahlı I, Doğan H. Successful surgical management of an intraorbital hydatid cyst through a transmaxillary approach: Case Report. *Skull Base* 2003;13:101-15.
12. Cooney RM, Flanagan KP, Zehyle E. Review of surgical management of cystic hydatid disease in a resource limited setting: Turkana, Kenya. *Eur J Gastroenterol Hepatol* 2004;16:1233-6.
13. Nahri GE. A simplified technique for removal of orbital hydatid cysts. *Br J Ophthalmol* 1991;75:743-5.
14. Zahawi HM, Hameed OK, Abalkhail AA. The possible role of the age of the human host in determining the localization of hydatid cysts. *Ann Trop Med Parasitol* 1999;93:621-7.
15. Benazzou S, Arkha Y, Derraz S, El Ouahabi A, El Khamlichi A. Orbital hydatid cyst: Review of 10 cases. *J Craniomaxillofac Surg* 2010;38:274-8.

**How to cite this article:** Mathad VU, Singh H, Singh D, Butte MV, Kaushik M. Large primary intraorbital hydatid cyst in elderly. *Asian J Neurosurg* 2013;8:170-2.

**Source of Support: Nil, Conflict of Interest: None declared.**