

CASE REPORT

Giant cell tumor of the clivus with presence of epithelioid histiocytes

Amit Agrawal, Rajsekhar Gali¹, Vissa Shanthi², Baddukonda Appala Ramakrishna², Kuppli Venkata Murali Mohan²

Department of Neurosurgery, Narayana Medical College Hospital, Chinthareddypalem, Departments of ¹Oral and Maxillofacial Surgery, ²Department of Pathology, Narayana Dental College Hospital, Chinthareddypalem, Nellore, Andhra Pradesh, India

ABSTRACT

Giant cell tumor (GCT) is a benign neoplasm but locally aggressive tumor that uncommonly involves the skull bone. We report a case of a 62-year-old male presented with increasing headache and diplopia. Investigations were suggestive of an expanding mass lesion of the clivus. Histopathology was suggestive of diagnosed with GCT with abundant histiocytes.

Key words: Clivus, giant cell tumor, histiocytes, skull

Introduction

Giant cell tumor (GCT) is a benign neoplasm but locally aggressive tumor that uncommonly involves the skull bone (preferentially, the sphenoid and the temporal bones),^[1,2] with occasional instances of orbital, calvarial, and occipital bones involvement.^[3] In the present article, we report a case of GCT of the clivus and review the relevant literature.

Case Report

A 62-year-old male underwent transphenoidal biopsy of the sellar mass lesion and it was diagnosed as GCT. Now, he presented with an increasing in headache and diplopia of 3 months duration. He was a known diabetic controlled with medication. There was no history of hypertension. His general and systemic examination was normal. Neurological examination was normal, except bilateral 6th nerve paresis. Magnetic resonance imaging (MRI) of the brain showed a large well-defined hyperdense contrast-enhancing lesion involving the clivus. In view of the enlarging size of the

lesion and increase in headache, the patient was planned for resurgery [Figure 1]. The patient underwent extended bifrontal craniotomy and orbitomy, subfrontal approach, and decompression of the tumor. Postoperatively was uneventful, the headache improved but diplopia and 6th nerve paresis was persisting. Microscopically, the lesion is composed of multinucleated giant cells admixed with mononuclear stromal cells. The stromal cells are polygonal, and some of them are elongated spindle-shaped. The cells have vesicular round to oval nuclei with prominent nucleoli in some of them. Increased vascularity was noted in some areas of tumor. Few foci showed sheets of clear histiocytes having small round nuclei and clear cytoplasm. Bony trabeculae rimmed by osteoblasts are noted in some foci [Figures 2 and 3].

Discussion

Primary GCTs of the clivus are a rare lesion with only few reported cases in the literature.^[4-6] The clinical features of these tumors depend on the location of cranial lesion and symptoms vary in accordance with their actual location. GCT of the sphenoid can present with headache, visual field defects, blindness, diplopia, second through 8th cranial nerve dysfunction, endocrinopathy, and altered mental status;^[4-6] on the contrary, temporal bone tumors can present with pain behind the ear, deafness, and facial weakness.^[7] GCT is characterized by vascularized tissue that contains numerous cytologically benign multinucleated giant cells dispersed through plump, spindly, and/or ovoid cells.^[1,8] Nuclei of the cells are generally hypochromatic with inconspicuous nucleoli and uncommon mitotic figures.^[9] Presence of epithelioid histiocytes is rare in GCT and it was described in case of GCT of the tendon sheath, which was largely composed of epithelioid; histiocytes are very rare and in the reported case, the tumor was composed of cellular and hypocellular zones, cellular

Access this article online	
Quick Response Code:	Website: www.asianjns.org
	DOI: 10.4103/1793-5482.131078

Address for correspondence:

Dr. Amit Agrawal, Department of Neurosurgery, Narayana Medical College Hospital, Chinthareddypalem, Nellore - 524 003, Andhra Pradesh, India.
E-mail: dramitagrawal@gmail.com

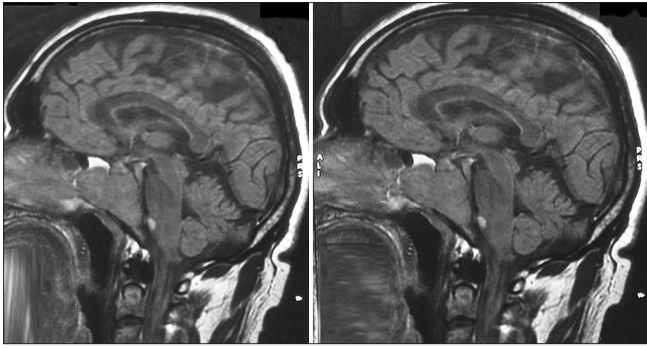


Figure 1: MRI of the brain showing extensive lesion involving the clivus

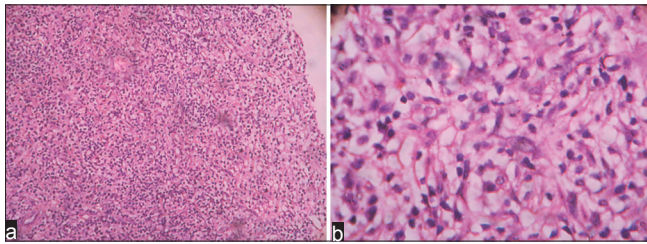


Figure 2: (a) Sheets of histiocytes with small round nuclei and clear cytoplasm (H and E, $\times 100$) and (b) Sheets of histiocytes with small round nuclei and clear cytoplasm (H and E, $\times 400$)

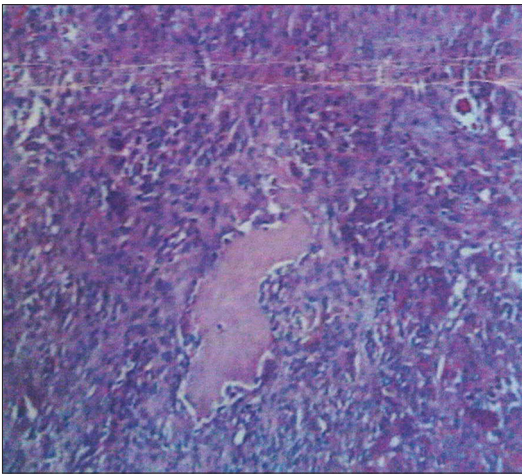


Figure 3: Tumor showing multiple osteoclast-like giant cells admixed with stromal cells (H and E, $\times 100$)

zone was composed of spindle cells and osteoclast-like giant cells, and the hypocellular zone was composed of epithelioid clear histiocytes, and it was suggested that the epithelioid histiocytes were the neoplastic cells.^[10] GCTs needs to be

differentiated from other lesion including chondrosarcoma and chordomas, aneurysmal bone cyst, giant cell reparative granuloma, “Brown tumor” of hyperparathyroidism, and fibrous dysplasia.^[9] Skull X-rays and angiography have been the traditional investigations for the diagnosis of the GCTs of the skull.^[3,9] Recently, computed tomography (CT) and MRI have been increasingly used for the diagnosis of these lesions, and the CT appearance of GCT is that of a homogeneous hyperdense mass highly enhancing after contrast administration.^[2,11] Bony erosions can also be demonstrated by CT scan examination,^[3,11] and the bone adjacent the lesion can appear hyperplastic in some cases.^[12] The treatment of choice of GCTs is complete surgical excision and if it can be achieved it is curative; however, as was seen in the present case, it may not always be feasible.^[9,11,12] Although controversial, in cases of unresectable tumors or with incomplete excision, radiotherapy remains the other option.^[2,4,7,9,11]

References

1. Dahlin DC. Caldwell lecture. Giant cell tumor of bone: Highlights of 407 cases. *AJR Am J Roentgenol* 1985;144:955-60.
2. Pai SB, Lalitha RM, Prasad K, Rao SG, Harish K. Giant cell tumor of the temporal bone: A case report. *BMC Ear Nose Throat Disord* 2005;5:8.
3. Vernet O, Ducrey N, Deruaz JP, de Tribolet N. Giant cell tumor of the orbit. *Neurosurgery* 1993;32:848-51.
4. Gupta R, Mohindra S, Mahore A, Mathuriya SN, Radotra BD. Giant cell tumour of the clivus. *Br J Neurosurg* 2008;22:447-9.
5. Zhang QH, Kong F, Yan B, Ni ZL, Lu HL. Endoscopic endonasal surgery for clival tumor. *Zhonghua Er Bi Yan Hou Tou Jing Wai Ke Za Zhi* 2007;42:7-10.
6. Zorlu F, Selek U, Soylemezoglu F, Oge K. Malignant giant cell tumor of the skull base originating from clivus and sphenoid bone. *J Neurooncol* 2006;76:149-52.
7. Pradhan S, Datta NR, Krishnani N, Ayyagari S, Tandon P. Giant cell tumour of the petrous bone. *Indian J Cancer* 1991;28:177-80.
8. Silvers AR, Som PM, Brandwein M, Chong JL, Shah D. The role of imaging in the diagnosis of giant cell tumor of the skull base. *AJNR Am J Neuroradiol* 1996;17:1392-5.
9. Wolfe JT 3rd, Scheithauer BW, Dahlin DC. Giant-cell tumor of the sphenoid bone. Review of 10 cases. *J Neurosurg* 1983;59:322-7.
10. Terada T. Giant cell tumor of the tendon sheath composed largely of epithelioid histiocytes. *Int J Clin Exp Pathol* 2012;5:374-6.
11. Findlay JM, Chiasson D, Hudson AR, Chui M. Giant-cell tumor of the middle cranial fossa. Case report. *J Neurosurg* 1987;66:924-8.
12. Watkins LD, Uttley D, Archer DJ, Wilkins P, Plowman N. Giant cell tumors of the sphenoid bone. *Neurosurgery* 1992;30:576-81.

How to cite this article: Agrawal A, Gali R, Shanthi V, Ramakrishna BA, Mohan KVM. Giant cell tumor of the clivus with presence of epithelioid histiocytes. *Asian J Neurosurg* 2014;9:48-9.
Source of Support: Nil, **Conflict of Interest:** None declared.