

A decade after International Subarachnoid Aneurysm Trial: Coiling as a first choice treatment in the management of intracranial aneurysms - Technical feasibility and early management outcomes

Gaurav Goel, Vipul Gupta, Swati Chinchure, Aditya Gupta, Gurmeen Kaur, Ajaya N. Jha

Department of Neurointervention surgery and Neurosurgery, Institute of Neurosciences, Medanta Hospital, Gurgaon, Haryana, India

ABSTRACT

Purpose: The technique of coiling has evolved in the last decade with evolution in both equipment and material. The preferable treatment of intracranial aneurysms at our center is endovascular coiling. We discuss the technical and management outcomes of consecutive patients treated with this approach and compare our results with a decade old International Subarachnoid Aneurysm Trial.

Materials and Methods: Between January 2006 and November 2011, a total of 324 aneurysms in 304 consecutive patients were treated. Endovascular treatment was done in 308 aneurysms (95.0%) in 288 patients while 16 patients (5%) underwent surgical clipping. Of the 308 aneurysms treated endovascularly, 269 (87.3%) were ruptured, and 39 (12.7%) were unruptured aneurysms.

Results: The endovascular coiling was feasible in all (99.6%) but 1 case. The immediate postoperative occlusion status was complete occlusion in 240 aneurysms (77.9%), neck remnant in 57 aneurysms (18.5%), and aneurysm remnant in 11 aneurysms (3.6%). Technical issues – with or without clinical effect – were encountered in 20 patients (6.9%). They included 18 thromboembolic events (6.2%) and intraprocedural aneurysmal rupture in 2 cases (0.7%). In “good grade” patients, H and H grade 1-3, a good outcome (modified Rankin score [mRS] 0-2) was in 87.6% patients while the bad outcome (mRS 3-5) was in 10.2% patients and mortality of 2.2%. In “bad grade” patients, H and H grade 3-5, a good outcome was in 29.2%, and bad outcome was in 41.7% patients with mortality was 29.1%. In the unruptured aneurysm group, the good outcome was seen in 97.7% and bad outcome in 2.3% with no mortality.

Conclusions: In the current era, the favorable results of coiling demonstrated in previous studies may be applicable to the larger proportion of patients. In our series of consecutively treated patients using latest advances, such as three-dimensional imaging and the interventional material, endovascular management as first choice was feasible in 95% of patients with good technical and management outcomes.

Key words: Aneurysm, coiling, management, subarachnoid hemorrhage

Access this article online

Quick Response Code:



Website:

www.asianjns.org

DOI:

10.4103/1793-5482.142733

Address for correspondence:

Dr. Vipul Gupta, Medanta Hospital, Sector-38, Gurgaon, Haryana, India. E-mail: drvipulgupta25@gmail.com

Introduction

The choice of treatment of intracranial aneurysms remains either surgical clipping or endovascular coiling. Traditionally, surgical clipping was considered the treatment of choice, but after the International Subarachnoid Aneurysm Trial (ISAT)^[1] (ISAT), there has been more trend toward coiling in many countries. ISAT trial showed an absolute risk reduction of 7.4% at the outset and a lower death rate at 1-year follow-up of endovascular coiling as compared to conventional surgical clipping. The long term follow-up of ISAT trial showed that

the early survival advantage was maintained up to 7 years and was significant.^[2] In recent times concluded trials like Barrow Ruptured Aneurysm Trial (BRAT) also concluded that outcomes of endovascular coiling were better than the surgical clipping.^[3] Two recent meta-analyses of all major randomized controlled trials comparing coiling and surgical clipping showed that the rate of poor outcome at 1-year was significantly lower in patients allocated to coil embolization.^[4,5]

However, there is limited data available on the technical feasibility and management outcomes of patient treated by endovascular coiling as the first choice.^[6,7] In the ISAT and BRAT trials only 39.8% and 62.3% percentage of patients respectively were treated by endovascular approach.^[1,3] Considerable advances have taken place in the technical performance of coils and catheters, in operator experience, technical expertise, and digital radiographic imaging systems, particularly three-dimensional angiography, which have all substantially improved since ISAT trial was started.^[8-14] There are very few studies which report results of endovascular coiling as the first approach in consecutive patients however these studies did not publish the management outcome with their approach.^[6,7] In particular, there has been no large series of endovascular management of intracranial aneurysm published from this part of the world.

In our hospital neurointervention unit is integrated as part of the neurosurgery team, and all patients are managed by the same treatment protocols. The preferable treatment of intracranial aneurysms at our center is endovascular coiling. Surgery is reserved for selected cases in which coiling is not possible or when subarachnoid hemorrhage is associated with large parenchyma hematoma. We discuss the technical and management outcomes of consecutive patients treated with this approach.

Materials and Methods

Patients

Between January 2006 and November 2011, a total of 324 aneurysms in 304 patients were treated by the team. The medical charts and angiograms of these patients were retrospectively evaluated. Endovascular treatment was done in 308 aneurysms (95.0%) in 288 patients while 16 patients (5%) underwent surgical clipping. Of the 308 aneurysms treated endovascular, 269 (87.3%) were ruptured, and 39 (12.7%) were unruptured aneurysms. Of 288 patients, 122 were male (42.4%) and 166 were female (57.6%). Mean age was 48.6 years (age range, 15-83 years) [Table 1].

The clinical status of the patients using the Hunt and Hess scale,^[15] the amount of blood on computed tomography (CT) according to the Fisher grade^[16] are summarized in Tables 2 and 3. Patients were evaluated by 4 vessel digital subtraction angiography as well as three-dimensional angiography to determine the presence and morphology of the aneurysms [Table 4]. The final outcome at discharge

Table 1: Patient and aneurysm characteristics

Patient characteristics	Number (%)
Mean age (years)±SD	48.6±12.02 years
Sex: Male/female	122 (42.4)/166 (57.6)
Total number of aneurysms treated	308
Number of aneurysms treated per patient	
1	268 (93.0)
2	20 (7.0)
3	0
Size of treated aneurysm	
Small (<5 mm)	173 (56.1)
Medium (5-15 mm)	126 (41.0)
Large (>15 mm)	9 (2.9)

SD – Standard deviation

Table 2: Clinical status of patients with aneurysms before endovascular coil treatment

Hunt and Hess grade (on admission)	Number of patients (%)
Unruptured	39 (13.5)
I	44 (15.3)
II	133 (46.2)
III	48 (16.7)
IV	22 (7.9)
V	2 (0.7)

Table 3: Amount of blood in the subarachnoid space quantified according to the Fisher grading scale

Fisher grading of SAH	Number of patients (%)
Unruptured	39 (13.5)
Grade 1	20 (6.9)
Grade 2	63 (21.8)
Grade 3	106 (36.8)
Grade 4	60 (20.8)

SAH – Subarachnoid hemorrhage

Table 4: Aneurysm location (308 aneurysms in 288 patients)

Location	Number
Anterior circulation	279
Anterior communicating artery	111
Posterior communicating artery	22
Paraclinoidal aneurysms	8
Middle cerebral artery	55
Internal carotid artery	57
Anterior choroidal artery	9
Pericallosal artery	17
Posterior circulation	29
Basilar artery	7
Posterior inferior cerebellar artery	11
Vertebral artery	5
Superior cerebellar artery	1
Posterior cerebral artery	5

was evaluated by using the modified Rankin score (mRS).^[17] A “good” outcome was defined as a mRS score of 0-2; a “poor” outcome was defined as a mRS score of 3-6. After the angiography, each case was discussed in a team including neurointervention and vascular neurosurgeon. If possible, endovascular management was preferred as the first choice for aneurysm occlusion.

Procedure

Endovascular treatment was performed within 2 days after the rupture in 182 cases (73.0%), between 2 and 7 days after the rupture in 44 cases (17.6%), and more than 1-week after the rupture in 23 cases (9.2%). All endovascular procedures were performed under general anesthesia. If possible, patients were extubated immediately after the procedure and were then monitored in intensive care unit. Daily monitoring for vasospasm was done by transcranial Doppler and in selected cases with CT perfusion. In cases of neurological deterioration due to vasospasm, intra-arterial dilatation with nimodipine was done.

Results

Technical outcome

The endovascular coiling was considered in 309 aneurysms. Out of the attempted 309 aneurysms it was feasible in all (99.6%), but 1 case. A case of anterior communicating artery aneurysm could not be coiled due to complex anatomy and instability of coil. Surgery was done in 16 cases. The reason for preferential surgical clipping in these cases was associated the hematoma, complex anatomy or a combination of both.

Anatomic results

The immediate postoperative occlusion status was complete occlusion in 240 aneurysms (77.9%), neck remnant in 57 aneurysms (18.5%), and aneurysm remnant in 11 aneurysms (3.6%) [Figures 1 and 2] [Table 5]. The balloon assistance was used in 50 cases (16.2%) [Figure 3], and an intracranial stent was placed in the parent vessel across the aneurysmal neck in 12 cases (3.9%) [Figure 4]. In 11 cases (3.5%) parent vessel occlusion was done [Table 6].

Procedural complications

Technical issues – with or without clinical effect – were encountered in 20 patients (6.9%). They included 18 thromboembolic events (6.2%) and intraprocedural aneurysmal rupture in 2 cases (0.7%) [Table 7]. In cases of thromboembolic events, heparin was given to raise the active clotting time to 300 s and intra-arterial Reopro (Abciximab) was given to dissolve the clot. In cases of aneurysm rupture, heparin was reversed, and coiling was continued till there was complete occlusion of the aneurysm. In all cases a DynaCT (angiographic CT) (AXIOM Artis FD Biplane Angiosuite; Siemens Medical Solutions, Forchheim, Germany) was performed. In both cases with intraoperative rupture, patient did not have any

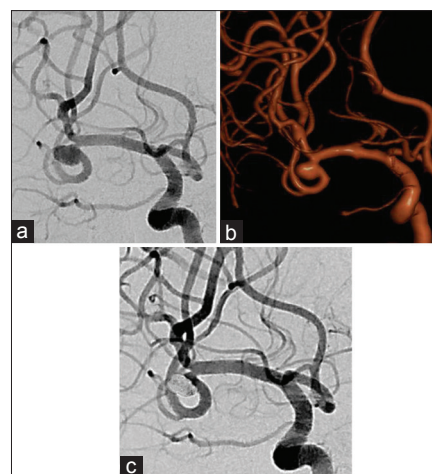


Figure 1: A 54-year-old lady with (a) ruptured right middle cerebral artery bifurcation aneurysm. (b) Three-dimensional rotational angiography assessment. (c) Complete occlusion of the aneurysm achieved

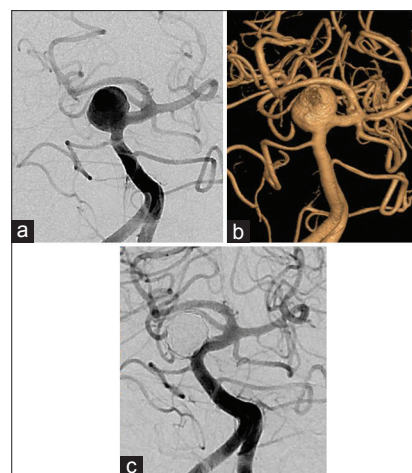


Figure 2: A 48-year-old man with (a) large broad neck ruptured mid basilar artery bifurcation aneurysm. (b) Three-dimensional rotational angiography assessment. (c) Complete occlusion of the aneurysm achieved

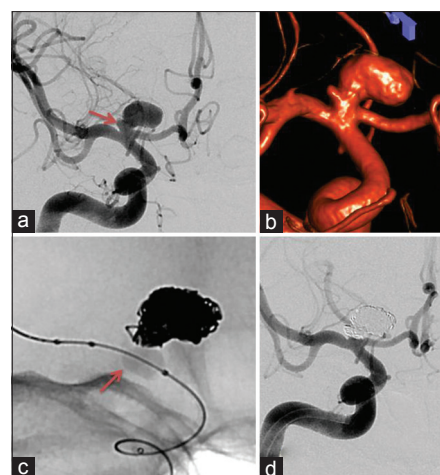


Figure 3: A 28-year-old man with subarachnoid hemorrhage. (a) Large broad neck right internal carotid artery terminus aneurysm with near the neck lobule (arrow). (b) Three-dimensional rotational angiography assessment. (c) Balloon (arrow) assisted coiling of the aneurysm. (d) Complete occlusion of the aneurysm achieved

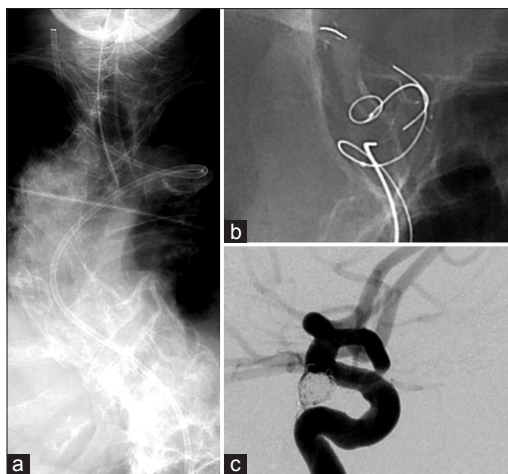


Figure 4: A 72-year-old lady with right third nerve palsy. (a) Extremely tortuous aortic arch. (b) Stent assisted coiling of the right posterior communicating artery aneurysm. (c) Complete occlusion of the aneurysm achieved with no complications

clinical deterioration and did not require surgery or external ventricular drain. Of the 20 patients who experienced intraoperative complications, postoperative modification of the clinical status was observed in 7 cases (2.5%). Two patients died (0.7%), 3 patients had a permanent deficit (1.0%), and 2 patients had a transient deficit (0.7%). There was groin hematoma in 3 cases with only 1 case requiring blood transfusion. One patient developed femoral arterio-venous fistula at the puncture site which resolved with ultrasound guided manual compression.

Management outcomes

In “good grade” patients, H and H grade 1-3, a good outcome (mRS 0-2) was in 87.6% patients while the bad outcome (mRS 3-5) was in 10.2% patients and mortality of 2.2%. In “bad grade” patients, H and H grade 3-5, a good outcome was in 29.2%, and bad outcome was in 41.7% patients with mortality was 29.1% [Table 8]. These are management outcomes including both treatment complications and clinical deterioration resulting from subarachnoid hemorrhage such as vasospasm, hydrocephalus and other clinical issues. There was clinical deterioration due to vasospasm in 68 (25.3%) patients which required one or more intra-arterial dilatation procedures with nimodipine.

In the unruptured aneurysm group, a good outcome was seen in 97.7% and bad outcome in 2.3% with no mortality.

In hospital rebleeding/retreatment

The early in hospital rebleeding was observed in only one patient of blister aneurysm of internal carotid artery which was treated by stent-assisted coiling. However, due to the friable nature of blister aneurysm, it was not possible to completely occlude the aneurysm, and there was a massive increase in the size of the aneurysm in a relatively short duration. Early retreatment was performed in 2 patients of dissecting

Table 5: Initial occlusion rate after the coiling treatment

Degree of occlusion (%)	Number of patients (%)
100	240 (77.9)
90-99	57 (18.5)
<90	9 (2.9)
<70	2 (0.7)

Table 6: Endovascular techniques used in aneurysm occlusion

Endovascular techniques	Number of patients (%)
Single catheter technique	232 (75.3)
Dual catheter technique	3 (0.9)
Balloon assistance	50 (16.2)
Stent assistance	12 (3.9)
Parent vessel occlusion	11 (3.5)

Table 7: Complications encountered during the endovascular treatment

Complications	Angiographic or technical (%)	Postoperative modification of clinical status (%)		
		Mortality	Permanent deficits	Transient deficits
Thrombo-embolism	18 (6.2)	1 (0.4)	3 (1.0)	2 (0.7)
Aneurysm rupture	2 (0.7)	1 (0.3)	0	0

Table 8: Management outcomes in 288 patients treated by endovascular coiling

Clinical grade at admission	Good outcome (%) (mRS 0-2)	Bad outcome (%) (mRS 3-5)	Mortality (%)
Hunt and Hess grade 1-3	87.6	10.2	2.2
Hunt and Hess grade 4-5	29.2	41.7	29.1
Unruptured aneurysm	97.7	2.3	0

aneurysms. In both patients of dissecting aneurysms, initial coiling was done to protect the dome of the aneurysm and retreatment was done with stent assistance when the initial period of hemorrhage was over. No complication was observed during retreatment.

Discussion

The aim of aneurysm treatment is mainly to prevent bleeding or rebleeding and thereby decrease the risk of death and dependency. Our study presents the technical feasibility and clinical outcomes of consecutive patients treated with the approach of endovascular management as preferred choice of treatment in patients with intracranial aneurysms.

Traditionally, surgical clipping was considered the treatment of choice in pre 1990 era. The initial indications for the endovascular coiling were mainly aneurysms in the posterior

circulation, patients in poor clinical grade or patients with multiple medical issues.^[18] The ISAT trial which showed an absolute risk reduction of 7.4% at the outset and a lower death rate at 1-year follow-up of endovascular coiling as compared to conventional surgical clipping changed the tide in favor of the coiling of the aneurysm in many countries.^[1,19-23] The long term follow-up of ISAT trial also showed that the early survival advantage was maintained up to 7 years and was significant.^[2]

However, the ISAT was criticized due to selection bias.^[24-29] Only aneurysms considered treatable by both techniques were randomized, resulting in only 22% of patients presenting with a ruptured aneurysm being included in the study. There were doubts raised about the experience of the neurosurgeons involved in the trial. In recent times published BRAT trial demonstrated that a policy of intent-to-treat by endovascular coil embolization results in fewer poor clinical outcomes after 1-year of follow-up.^[3] The proportion of patients with a poor outcome (defined by mRS score > 2) was 33.7% in the surgical group versus 23.2% ($P = 0.02$, intention-to-treat analysis) in the endovascular group. The expertise of the neurosurgeons involved and the fact that nearly 70% of eligible patients were enrolled in the BRAT trial has further dwarfed the arguments against ISAT results.^[30] The 3 year results of BRAT trial showed that the outcomes of all patients assigned to coil embolization showed a favorable 5.8% absolute difference compared with outcomes of those assigned to clip occlusion although this difference did not reach statistical significance ($P = 0.25$).^[31] A recent meta-analysis of three major randomized controlled trials comparing coiling and surgical clipping showed that the rate of poor outcome at 1-year was significantly lower in patients allocated to coil embolization (risk ratio, 0.75; 95% confidence interval [CI], 0.65-0.87). This relative effect is consistent with an absolute risk reduction of 7.8%.^[4]

Another large meta-analysis of 11568 patients including four randomized controlled trials and 23 observational studies also showed that coiling reduced the 1-year unfavorable outcome rate (odds ratio, 1.48; 95% CI, 1.24-1.76).^[5] Furthermore, subgroup analyses from these clinical trials have indicated that the risks of seizures, delayed cerebral ischemia, ischemic lesions on magnetic resonance imaging, and in-hospital complications are lower after coil embolization than after surgical clip ligation, but the risk of aneurysm recurrence, the need for retreatment, and the risk of rebleeding from the index aneurysm are higher after coil embolization. Though, despite the higher risk of rebleeding, the initial beneficial effect on functional outcome remained present up to 7 years after treatment.

However, the percentage of patients treated by coiling in ISAT and BRAT trials was 39.8% and 62.3% respectively.^[1,3] Last decade had seen major advances in the technical performance of coils and catheters including three-dimensional coils, guiding and distal access catheters, operator experience,

technical expertise, digital radiographic imaging systems, particularly three-dimensional angiography and use of balloon and stents for wide neck aneurysms, due to which more and more aneurysms can be tackled by endovascular approach.^[8-14] Therefore, our group has preferred the endovascular approach, if possible, and with this intent to coil approach the aneurysm treatment was feasible in 95% of cases. During this period, surgical clipping was done in 16 (5%) cases. The cases primarily referred to surgery were with a large hematoma, in which decompressive hemicraniectomy is required or large dysplastic complex aneurysms, which would have necessitated stent assistance in acute subarachnoid hemorrhage (SAH) stage, and were considered amenable to surgical reconstruction.

There are few studies in the literature with coiling as the first approach. In the series by Lubicz *et al.*^[6] of 167 patients treated by coiling as first intention, there were 87.3% patients treated by coiling as the first approach with surgery done in 12.7% cases. In another large series of CLARITY GDC study^[7] of 405 patients treated at 19 French centers, treating aneurysms preferentially by coiling, coils were introduced successfully into the aneurysms in 402 cases and coiling failed in 3 of 405 (0.7%), and all 3 patients were subsequently clipped. In another large multicenter series of 705 ruptured intracranial aneurysms, 96.9% feasibility of the endovascular technique was achieved.^[32] Henkes *et al.* on their review of 2150 intracranial aneurysms, showed 1811 aneurysms (84.2%) treated with endovascular coil occlusion, 187 (8.7%) remained untreated during their period of data collection, and 152 aneurysms (7.1%) were surgically treated.^[33]

Ours is the only large single center study with coiling as the first choice in consecutive patients, which describes both technical and final management outcomes in the patients treated by coiling as the first choice. The technical success thus achieved is comparable to the other studies published.

In all the treated aneurysms, there was complete occlusion achieved in 77.9% aneurysms and neck remnant in 18.5% aneurysms and aneurysm remnant in 3.6% aneurysms in our series. The ISAT revealed a complete occlusion rate of 66% (584 of 988) in the coiled patients, whereas other case series of ruptured coiled aneurysms revealed complete occlusion rates ranging from 33% to 81%^[10,32-38] [Table 9]. Therefore, our

Table 9: Initial occlusion rates of major endovascular studies

Studies	Total number of patients/aneurysms	Complete occlusion (n/%)	Neck remnant (n/%)	Incomplete (n/%)
Gallas <i>et al.</i> ^[32]	650/705	496 (72.6)	171 (25)	16 (2.4)
Henkes <i>et al.</i> ^[33]	1579/1811	1192 (65.8)	375 (20.7)	192 (10.7)
Willinsky <i>et al.</i> ^[34]	377/391	170 (43)	142 (36)	79 (20)
Cerecyte trial ^[30]	63/67	33 (49)	14 (21)	20 (30)

occlusion rates are comparable, if not better, than the previous results in spite of a large proportion of aneurysms treated preferentially by endovascular means in the ruptured state. This can be attributed to the vast technological advances as said before.

The majority of procedural complications during endovascular coil occlusion of intracranial aneurysms are either ischemic or hemorrhagic. In our series, we found technical issues in terms of ischemic complication in 6.2% of and 0.7% cases of aneurysmal rupture. The postoperative clinical deterioration was seen in total 2.5%. The reported frequency of ischemic complications ranges from 2.5% to 11.0%.^[33,39-43] In their literature meta-analysis, Brilstra *et al.*^[41] reported a 12% procedural complication rate in 1256 aneurysms, including ischemic events (8.5%) and aneurysm perforations (2.4%). In our series low ischemic complications can be attributed to the close monitoring of activated clotting time and if clot forms, early use of lytic agents like Abciximib (Reopro) to prevent clinical complication.

Procedural aneurysm perforations are less frequent than ischemic events.^[1,44] A frequently quoted rate is 2-3%, although in a recent series it is <1%.^[10] Use of three-dimensional rotational angiography, ultrasoft coils helps in preventing this dreaded complication. The authors have already published on the safety of coiling of very small <2 mm aneurysms, which are very high risk for rupture.^[45] In our 2 cases of rupture, the steps taken after the rupture was detected, includes medically induced hypotension, reversal of anticoagulation, coil occlusion of the perforation site, and the use of a balloon to temporarily occlude the artery.^[10,44,46] The external ventricular drainage, surgical evacuation of an intracerebral hematoma, or the emergency clipping of the perforated aneurysms were not required in our cases.^[47]

In “good grade” patients, H and H grade 1-3, a good outcome (mRS 0-2) was in 87.6% patients while the bad outcome (mRS 3-5) was in 10.2% patients and mortality of 2.2%. In “bad grade” patients, H and H grade 3-5, a good outcome was in 29.2%, and bad outcome was in 41.7% patients with mortality was 29.1%. The global mortality and morbidity, including both good and bad grade patients, in our experience, were 4.8% and 13.2% respectively, and the overall death or dependency was 18.0%. In comparison the total rate of death or dependency in ISAT trial^[1] was 23.7%, in BRAT^[3] trial 20.4% and in GDC CLARITY study 23.3%.^[7]

It is widely known that vasospasm is the cause of major mortality and morbidity in subarachnoid hemorrhage.^[48] There has been recent evidence that intra-arterial angioplasty either chemical or balloon improves the outcomes in patients of vasospasm.^[49] It is possible that aggressive management of vasospasm in our series using intra-arterial chemical angioplasty may have played a substantial role in improved outcomes.

Our study is unique that consecutive patients were treated by same protocol with endovascular unit being part of the neurosurgery team. This is the first of its kind study from the Asian continent. In our series of largely ruptured aneurysm, endovascular treatment was feasible in 95% of patients with reasonable technical and good clinical outcomes. In the previous randomized studies, ISAT and BRAT, proportionally less number of patients were treated by coiling. Although we treated larger number of patients by endovascular means, the technical and clinical outcomes were quite favorable. The good clinical outcomes, in terms of mRs scale, in H and H grade 1-3 were 87.6%. Therefore, in the current era, the favorable results of coiling demonstrated in previous studies may be applicable to the larger proportion of patients. It is our opinion that use of latest advances such as three-dimensional imaging and the interventional material along with the integrated team of neurosurgery and interventionist along with aggressive management of SAH related complication such as vasospasm helped in achieving good outcomes which can be compared favorably with previous studies.

Our study has few limitations. These are the initial management outcomes only. The long term follow-up of these patients will be required. Secondly, the angiographic follow-up and analysis is awaited to assess the issue of recanalization and retreatment rates.

References

1. Molyneux A, Kerr R, Stratton I, Sandercock P, Clarke M, Shrimpton J, *et al.* International Subarachnoid Aneurysm Trial (ISAT) of neurosurgical clipping versus endovascular coiling in 2143 patients with ruptured intracranial aneurysms: A randomised trial. *Lancet* 2002;360:1267-74.
2. Molyneux AJ, Kerr RS, Birks J, Ramzi N, Yarnold J, Sneade M, *et al.* Risk of recurrent subarachnoid haemorrhage, death, or dependence and standardised mortality ratios after clipping or coiling of an intracranial aneurysm in the International Subarachnoid Aneurysm Trial (ISAT): Long-term follow-up. *Lancet Neurol* 2009;8:427-33.
3. McDougall CG, Spetzler RF, Zabramski JM, Partovi S, Hills NK, Nakaji P, *et al.* The barrow ruptured aneurysm trial. *J Neurosurg* 2012;116:135-44.
4. Lanzino G, Murad MH, d’Urso PI, Rabinstein AA. Coil embolization versus clipping for ruptured intracranial aneurysms: A meta-analysis of prospective controlled published studies. *AJNR Am J Neuroradiol* 2013;34:1764-8.
5. Li H, Pan R, Wang H, Rong X, Yin Z, Milgrom DP, *et al.* Clipping versus coiling for ruptured intracranial aneurysms: A systematic review and meta-analysis. *Stroke* 2013;44:29-37.
6. Lubicz B, Balériaux D, Lefranc F, Brotchi J, Bruneau M, Levivier M. Endovascular treatment of intracranial aneurysms as the first therapeutic option. *J Neuroradiol* 2007;34:250-9.
7. Cognard C, Pierot L, Anxionnat R, Ricolfi F, Clarity Study Group. Results of embolization used as the first treatment choice in a consecutive nonselected population of ruptured aneurysms: Clinical results of the Clarity GDC study. *Neurosurgery* 2011;69:837-41.
8. McDougall CG, Johnston SC, Gholkar A, Barnwell SL, Vazquez Suarez JC, Massó Romero J, *et al.* Bioactive versus bare platinum coils in the treatment of intracranial aneurysms: The MAPS (Matrix and Platinum Science) trial. *AJNR Am J Neuroradiol* 2014;35:935-42.
9. White PM, Lewis SC, Gholkar A, Sellar RJ, Nahser H, Cognard C, *et al.* Hydrogel-coated coils versus bare platinum coils for the endovascular

- treatment of intracranial aneurysms (HELPS): A randomised controlled trial. *Lancet* 2011;377:1655-62.
10. Linfante I, DeLeo MJ 3rd, Gounis MJ, Brooks CS, Wakhloo AK. Cerecyte versus platinum coils in the treatment of intracranial aneurysms: Packing attenuation and clinical and angiographic midterm results. *AJNR Am J Neuroradiol* 2009;30:1496-501.
 11. Hui FK, Fiorella D, Masaryk TJ, Rasmussen PA, Dion JE. A history of detachable coils: 1987-2012. *J Neurointerv Surg* 2014;6:134-8.
 12. Gaba RC, Ansari SA, Roy SS, Marden FA, Viana MA, Malisch TW. Embolization of intracranial aneurysms with hydrogel-coated coils versus inert platinum coils: Effects on packing density, coil length and quantity, procedure performance, cost, length of hospital stay, and durability of therapy. *Stroke* 2006;37:1443-50.
 13. Biondi A, Janardhan V, Katz JM, Salvaggio K, Riina HA, Gobin YP. Neuroform stent-assisted coil embolization of wide-neck intracranial aneurysms: Strategies in stent deployment and midterm follow-up. *Neurosurgery* 2007;61:460-8.
 14. Weber W, Bendszus M, Kis B, Boulanger T, Solymosi L, Kühne D. A new self-expanding nitinol stent (Enterprise) for the treatment of wide-necked intracranial aneurysms: Initial clinical and angiographic results in 31 aneurysms. *Neuroradiology* 2007;49:555-61.
 15. Hunt WE, Hess RM. Surgical risk as related to time of intervention in the repair of intracranial aneurysms. *J Neurosurg* 1968;28:14-20.
 16. Fisher CM, Kistler JP, Davis JM. Relation of cerebral vasospasm to subarachnoid hemorrhage visualized by computerized tomographic scanning. *Neurosurgery* 1980;6:1-9.
 17. van Swieten JC, Koudstaal PJ, Visser MC, Schouten HJ, van Gijn J. Interobserver agreement for the assessment of handicap in stroke patients. *Stroke* 1988;19:604-7.
 18. Guglielmi G, Viñuela F, Dion J, Duckwiler G. Electrothrombosis of saccular aneurysms via endovascular approach. Part 2: Preliminary clinical experience. *J Neurosurg* 1991;75:8-14.
 19. Qureshi AI, Vazquez G, Tariq N, Suri MF, Lakshminarayan K, Lanzino G. Impact of International Subarachnoid Aneurysm Trial results on treatment of ruptured intracranial aneurysms in the United States. Clinical article. *J Neurosurg* 2011;114:834-41.
 20. Gnanalingham KK, Apostolopoulos V, Barazi S, O'Neill K. The impact of the international subarachnoid aneurysm trial (ISAT) on the management of aneurysmal subarachnoid haemorrhage in a neurosurgical unit in the UK. *Clin Neurol Neurosurg* 2006;108:117-23.
 21. Niemelä M, Koivisto T, Kivipelto L, Ishii K, Rinne J, Ronkainen A, *et al.* Microsurgical clipping of cerebral aneurysms after the ISAT Study. *Acta Neurochir Suppl* 2005;94:3-6.
 22. Barrow DL. Bad science ISAT: The impact on neurosurgical practice. *Clin Neurosurg* 2004;51:126-31.
 23. Maurice-Williams RS. Aneurysm surgery after the International Subarachnoid Aneurysm Trial (ISAT). *J Neurol Neurosurg Psychiatry* 2004;75:807-8.
 24. Carter BS. ISAT subgroups: Is aneurysm clipping better for some patients? *Neurosurgery* 2008;63:14.
 25. Harbaugh RE, Heros RC, Hadley MN. More on ISAT. *Lancet* 2003;361:783-4.
 26. Heros RC. International subarachnoid aneurysm trial analysis. *J Neurosurg* 2008;108:433-5.
 27. Javadpour M. ISAT: Will the results stand the test of time? *Br J Neurosurg* 2007;21:7-8.
 28. Mitha AP, Ogilvy CS. ISAT: Coiling or clipping for ruptured intracranial aneurysms? *Lancet Neurol* 2005;4:791-2.
 29. Kirkpatrick PJ, Kirillos RW, Higgins N, Matta B. Lessons to be learnt from the International Subarachnoid Haemorrhage Trial (ISAT). *Br J Neurosurg* 2003;17:5-7.
 30. Kerr R, Molyneux A. The barrow ruptured aneurysm trial and international subarachnoid aneurysm trial. *J Neurosurg* 2013;118:478-80.
 31. Spetzler RF, McDougall CG, Albuquerque FC, Zabramski JM, Hills NK, Partovi S, *et al.* The barrow ruptured aneurysm trial: 3-year results. *J Neurosurg* 2013;119:146-57.
 32. Gallas S, Pasco A, Cottier JP, Gabrillargues J, Drouineau J, Cognard C, *et al.* A multicenter study of 705 ruptured intracranial aneurysms treated with Guglielmi detachable coils. *AJNR Am J Neuroradiol* 2005;26:1723-31.
 33. Henkes H, Fischer S, Weber W, Miloslavski E, Felber S, Brew S, *et al.* Endovascular coil occlusion of 1811 intracranial aneurysms: Early angiographic and clinical results. *Neurosurgery* 2004;54:268-80.
 34. Willinsky RA, Peltz J, da Costa L, Agid R, Farb RI, terBrugge KG. Clinical and angiographic follow-up of ruptured intracranial aneurysms treated with endovascular embolization. *AJNR Am J Neuroradiol* 2009;30:1035-40.
 35. Friedman JA, Nichols DA, Meyer FB, Pichelmann MA, McIver JI, Toussaint LG 3rd, *et al.* Guglielmi detachable coil treatment of ruptured saccular cerebral aneurysms: Retrospective review of a 10-year single-center experience. *AJNR Am J Neuroradiol* 2003;24:526-33.
 36. Mejdoubi M, Gigaud M, Trémoulet M, Albuher JF, Cognard C. Initial primary endovascular treatment in the management of ruptured intracranial aneurysms: A prospective consecutive series. *Neuroradiology* 2006;48:899-905.
 37. Sluzewski M, van Rooij WJ, Rinkel GJ, Wijnalda D. Endovascular treatment of ruptured intracranial aneurysms with detachable coils: Long-term clinical and serial angiographic results. *Radiology* 2003;227:720-4.
 38. Viñuela F, Duckwiler G, Mawad M. Guglielmi detachable coil embolization of acute intracranial aneurysm: Perioperative anatomical and clinical outcome in 403 patients. *J Neurosurg* 1997;86:475-82.
 39. Alexander MJ, Duckwiler GR, Gobin YP, Viñuela F. Management of intraprocedural arterial thrombus in cerebral aneurysm embolization with abciximab: Technical case report. *Neurosurgery* 2002;50:899-901.
 40. Qureshi AI, Luft AR, Sharma M, Guterman LR, Hopkins LN. Prevention and treatment of thromboembolic and ischemic complications associated with endovascular procedures: Part II – Clinical aspects and recommendations. *Neurosurgery* 2000;46:1360-75.
 41. Brilstra EH, Rinkel GJ, van der Graaf Y, van Rooij WJ, Algra A. Treatment of intracranial aneurysms by embolization with coils: A systematic review. *Stroke* 1999;30:470-6.
 42. Koebe CJ, Horowitz MB, Levy EI, Dutton K, Jungreis CC, Purdy PD. Intraarterial thrombolysis for thromboemboli associated with endovascular aneurysm coiling. Report of five cases. *Interv Neuroradiol* 2002 30;8:151-8.
 43. Mounayer C, Piotin M, Baldi S, Spelle L, Moret J. Intraarterial administration of Abciximab for thromboembolic events occurring during aneurysm coil placement. *AJNR Am J Neuroradiol* 2003;24:2039-43.
 44. Levy E, Koebe CJ, Horowitz MB, Jungreis CA, Pride GL, Dutton K, *et al.* Rupture of intracranial aneurysms during endovascular coiling: Management and outcomes. *Neurosurgery* 2001;49:807-11.
 45. Jha AN, Gupta V. Blister aneurysms. *Neurol India* 2009;57:2-3.
 46. McDougall CG, Halbach VV, Dowd CF, Higashida RT, Larsen DW, Hieshima GB. Causes and management of aneurysmal hemorrhage occurring during embolization with Guglielmi detachable coils. *J Neurosurg* 1998;89:87-92.
 47. Short JG, Marx WF, Lanzino G, Ellegala DB, Kassell NF. Surgical salvage of microcatheter-induced aneurysm perforation during coil embolization. *AJNR Am J Neuroradiol* 2002;23:682-5.
 48. Macdonald LR, Weir B. Epidemiology. Cerebral vasospasm. San Diego (CA): Academic Press; 2001. p. 17-43.
 49. McGuinness B, Gandhi D. Endovascular management of cerebral vasospasm. *Neurosurg Clin N Am* 2010;21:281-90.

How to cite this article: Goel G, Gupta V, Chinchure S, Gupta A, Kaur G, Jha AN. A decade after International Subarachnoid Aneurysm Trial: Coiling as a first choice treatment in the management of intracranial aneurysms - Technical feasibility and early management outcomes. *Asian J Neurosurg* 2014;9:137-43.

Source of Support: Nil, **Conflict of Interest:** None declared.