

Neural oscillation, network, eloquent cortex and epileptogenic zone revealed by magnetoencephalography and awake craniotomy

Zamzuri Idris^{1,2}, Regunath Kandasamy², Faruque Reza², Jafri M. Abdullah^{1,2}

¹Center for Neuroscience Service and Research and ²Department of Neurosciences, School of Medical Sciences, Center for Neuroscience Service and Research, Universiti Sains Malaysia, Kubang Kerian, 16150 Kota Bharu, Kelantan, Malaysia

ABSTRACT

Background: Magnetoencephalography (MEG) is a method of functional neuroimaging. The concomitant use of MEG and electrocorticography has been found to be useful in elucidating neural oscillation and network, and to localize epileptogenic zone and functional cortex. We describe our early experience using MEG in neurosurgical patients, emphasizing on its impact on patient management as well as the enrichment of our knowledge in neurosciences.

Materials and Methods: A total of 10 subjects were included; five patients had intraaxial tumors, one with an extraaxial tumor and brain compression, two with arteriovenous malformations, one with cerebral peduncle hemorrhage and one with sensorimotor cortical dysplasia. All patients underwent evoked and spontaneous MEG recordings. MEG data was processed at band-pass filtering frequency of between 0.1 and 300 Hz with a sampling rate of 1 kHz. MEG source localization was performed using either overdetermined equivalent current dipoles or underdetermined inversed solution. Neuromag collection of events software was used to study brain network and epileptogenic zone. The studied data were analyzed for neural oscillation in three patients; brain network and clinical manifestation in five patients; and for the location of epileptogenic zone and eloquent cortex in two patients.

Results: We elucidated neural oscillation in three patients. One demonstrated oscillatory phenomenon on stimulation of the motor-cortex during awake surgery, and two had improvement in neural oscillatory parameters after surgery. Brain networks corresponding to clinico-anatomical relationships were depicted in five patients, and two networks were illustrated here. Finally, we demonstrated epilepsy cases in which MEG data was found to be useful in localizing the epileptogenic zones and functional cortices.

Conclusion: The application of MEG while enhancing our knowledge in neurosciences also has a useful role in epilepsy and awake surgery.

Key words: Awake craniotomy, brain network, epilepsy, magnetoencephalography, neural oscillation

Introduction

Neuronal oscillations in our brain are vital for normal brain function. These oscillations contribute to neural coding by

producing rhythms with differing frequencies. Rhythms may be defined as being either gamma, beta, alpha, theta or delta depending on their respective frequencies (above 30 Hz; 13-30 Hz; 8-13 Hz; 4-8 Hz; 0.5-4 Hz). Similar to genetic coding which give rise to heterogeneous and complex phenotypical manifestations, brain rhythms similarly also contribute to a myriad of diverging brain functions. Neural oscillations can be further stratified into microscale-oscillation (activity of a single neuron), mesoscale-oscillation (activity of the local group of neurons or vertices) and macroscale-oscillation (neural activity from different brain regions or networks).^[1] According to the graph theory, the macroscale-oscillation forms numerous network loops with edges and vertices inside our brain.^[2,3] This network loops play a crucial role in both; normal and abnormal (pathological) brain function. Abnormal or altered neural oscillations and networks may possibly contribute to various clinical and subclinical manifestations such as excessive synchronization during seizures

Access this article online	
Quick Response Code:	Website: www.asianjns.org
	DOI: 10.4103/1793-5482.142734

Address for correspondence:

AP Dr. Zamzuri Idris, Department of Neurosciences, School of Medical Sciences, Hospital Universiti Sains Malaysia, Kubang Kerian, 16150 Kota Bharu, Kelantan, Malaysia.
E-mail: zamzuri@kb.usm.my

and tremors as well as abnormal network formation in limbs weakness or cognitive impairment.^[4-8]

To study these fundamental aspects of brain function, one must be able to record brain oscillations or rhythms and map these brain networks. Magnetoencephalography (MEG) and electroencephalography (EEG) are viewed as being capable of fulfilling these tasks. MEG is capable of measuring magnetic fields and waves of brain activity, and it is increasingly recognized as a vital part of presurgical evaluation of patients with epilepsy and patients with brain lesions. MEG is also helpful for investigating patterns of brain waves in various physiological, medical and neurological conditions.^[9-11] We describe our early experience in mapping brain networks, studying neuroplasticity and localizing seizure focus by using the two modalities.

Materials and Methods

Patients

Data were collected from 10 patients with differing pathological conditions pertaining to neurosurgery: Anaplastic astrocytoma, meningioma, cerebral metastases, basal ganglia arteriovenous malformation (AVM), globus pallidus interna-internal capsule AVM, thalamic glioma, cerebral peduncle hemorrhage, insular high-grade glioma, intractable epilepsy secondary to low-grade glioma and cortical dysplasia. MEG recordings were performed before and after neurosurgical intervention in the majority of our cohort. MEG recordings were made for both: (a) Evoked somatosensory, motor, auditory and visual responses in a patient harboring a lesion at or near the eloquent cortex and (b) spontaneous eyes-open 30 min MEG recordings for all patients or 1 h recording for patients investigated specifically for epileptogenic zones. The data were registered, processed and fused with anatomical magnetic resonance images (MRI) [Figure 1a] and was designated as magnetic source imaging (MSI). MSI was subsequently transferred into the neuronavigational system (StealthStation® Medtronic-Sofamor Danek, Memphis, TN, USA) in the operating theatre for cases that required surgery. In general, MEG recordings were repeated 1-month after the surgery to analyze and compare the brainwaves before and after the surgery. For patients who did not undergo surgery, MEG analysis for brain networks was performed prior to any intended nonneurosurgical intervention.

Magnetoencephalography recording, postprocessing and data analysis

Magnetic evoked and spontaneous fields were recorded while patients were seated in a magnetically shielded room (MaxShield™, Elekta Oy, Helsinki, Finland) using a 306-channel (102 magnetometers and 204 gradiometers) whole-head MEG system (Elekta Neuromag®, Elekta Oy, Helsinki, Finland). A third-order software gradient was used after online band-pass filtering between 0.1 and 300 Hz

to discard noises. The sampling frequency was 1 kHz. The head-position relative to the MEG sensors of the helmet was localized using: (a) Three fiducial localization coils attached to right and left preauricular points, and the nasion of the patients; (b) 100-150 points digitized around the head using a three-dimensional positions monitoring systems (Pholemus, Colchester, VT, United States); (c) four electromagnetic head-positions indicator coils were used to assess the head-position at the beginning of the measurement process. During the recording, the head-position changes of up to 1.5 cm were accepted. MEG source localizations for somatosensory, motor, auditory and visual evoked magnetic fields were performed by using the technique of overdetermined equivalent current dipoles (ECDs), which was already installed inside the Neuromag computer working station [Figure 1b]. The somatosensory, motor, auditory and visual evoked magnetic fields (average) are normally expected at around 20ms–5ms (lefthand motor) and –50ms (righthand motor), 100 ms and 75-120 ms after the stimuli respectively. The anatomical brain images (T1-weighted/T2-weighted/fluid attenuated inversion recovery/three-dimensional) were obtained using Philips MRI (Philips Intera 3.0T MRI scanner Royal Philips, Breitner center, Amsterdam, Netherlands). Fusion between the anatomical MRI images and tomographic reconstruction of the head-model brainwave data was completed prior to source localization.

For brain network analysis and epileptic spike (or slow wave) localization, we used the Neuromag collection of events software to analyze the spontaneous brainwave data. Figure 2a-d illustrate our steps in automatic analysis of high amplitude spike-like hyperactive areas (this method can also localize the hypoactive or slow wave regions [theta/delta waves areas]). Normally, the brainwave threshold-amplitude was set at above 10% from normal brainwave activity for analysis of high amplitude spike-like hyperactive brain networks and commonly above 10-20% for automatic epileptic spike analysis. Two refractory epileptic patients were analyzed using MEG for interictal spikes (both patients had normal EEG recordings), and one of them had further reconfirmatory intraoperative electrocorticography (ECoG) recordings. For brain oscillation or frequency analysis, the fast Fourier transformation (FFT) was utilized (FFT-size-1024, FFT-step 512, hanning type window). Separate bands of brainwave frequencies (spectral analysis) were analyzed for a 20 s epoch, picked from each recording for each lobe of the brain (average brainwaves frequency band power from eight regions of the brain: Right and left frontal, parietal, temporal, and occipital). This was performed twice, before and after the surgery.

Awake surgery, electroencephalography and electrocorticography recording

Awake surgery was done without endotracheal intubation using scalp block of 25 ml mixture of 0.75% ropivacaine and

adrenaline of 5 µg/ml concentration and another 15 ml for skin infiltration at the head-pins and proposed incision site, and using dexmedetomidine and remifentanyl infusion as conscious sedation during the initial craniotomy. In the supine position, the head was fixed, the neck was supported and the trunk was elevated to 40° above the chest, craniotomy proceeded under

conscious sedation, and the MSI-based neuronavigational extraoperative images were used to “quickly” map the eloquent cortices and the lesion. Conscious sedative drug infusions were stopped at the beginning of dural opening. This step gives ample time for patients to regain consciousness allowing intraoperative mapping to be done immediately after

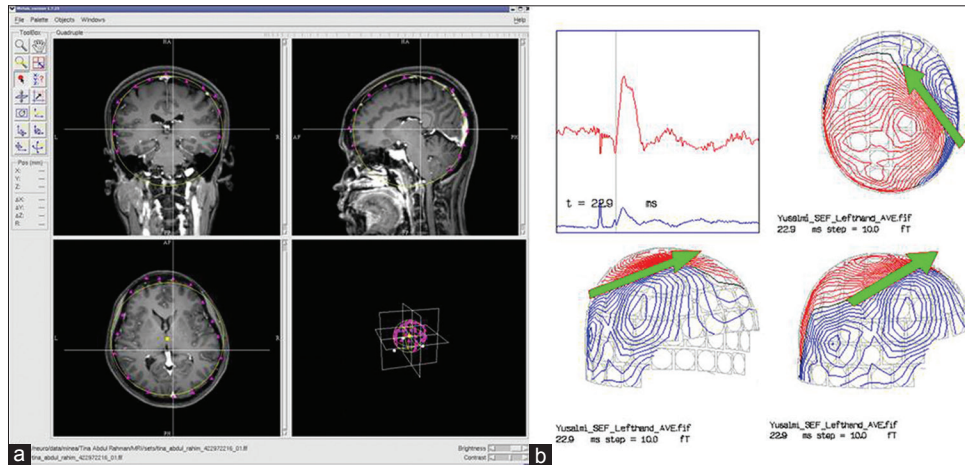


Figure 1: (a) Magnetoencephalography (MEG) registration and fusion: MEG data were processed and fused with anatomical magnetic resonance images. (b) Equivalent current dipole method for MEG source localization for magnetic evoked response to localize the eloquent cortex

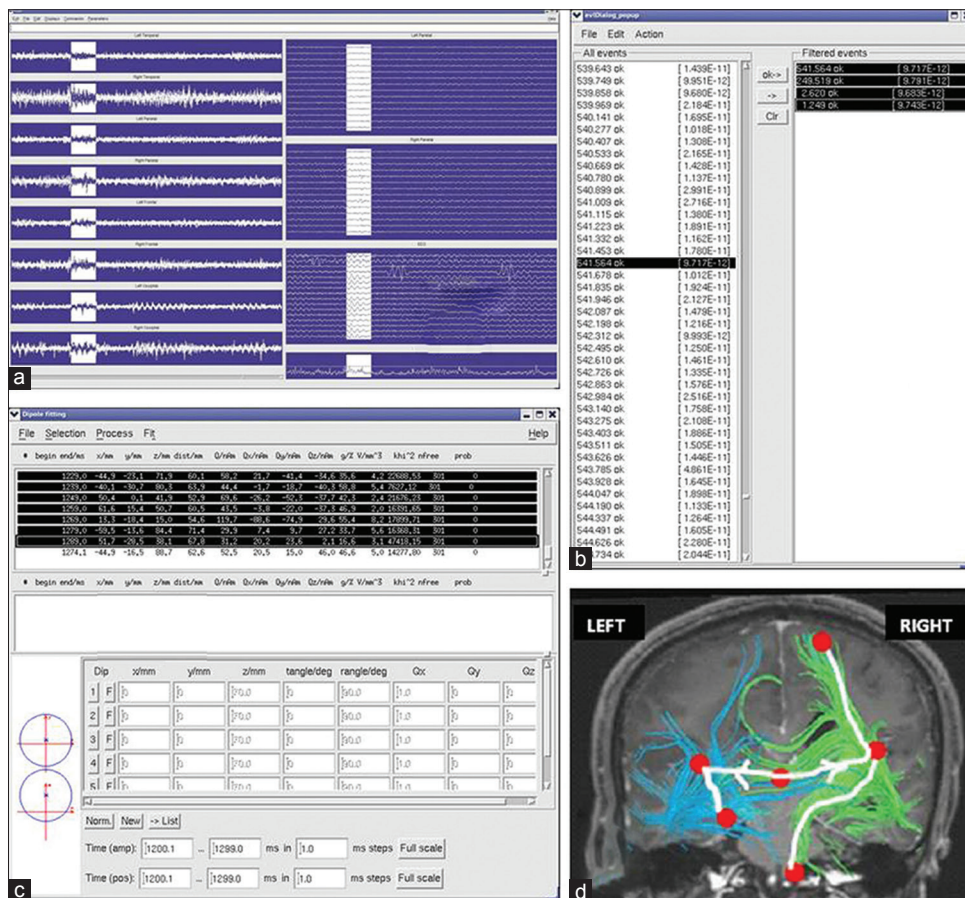

Figure 2: Collection of events Neuromag software analysis. (a) Brainwaves of above predetermined threshold (example: 10% increment) was selected. (b) Collection of events obtained, but only few selected events are randomly chosen and analyzed for their co-ordinates (x, y and z). (c) The co-ordinates were obtained, and only those with >50% fitness of good and those that correlate with anatomical images were selected. (d) The final activated (hyperactivated or hypoactivated) areas were mapped onto the anatomical images

opening the dura. Based on the navigated MSI images, the identified eloquent cortices were remapped and confirmed using an Ojemann bipolar cortical neurostimulator (Radionics, Inc., Burlington, MA). The motor response was normally obtained at amplitude of 5-6 mA (pulse frequency of 60 Hz, single pulse phase duration of 1 ms) and sensory response was normally obtained at amplitude of 4 mA (60 Hz, 1 ms/phase). Modification was made for epilepsy surgery which required implantation of subdural grid/strip electrodes. The craniotomy and implantation of subdural electrodes were performed under general anesthesia. The grid (or strip) electrodes were fixed, and several clear intraoperative photos were taken for future reference. Subsequently, the patient was transferred to the Intensive Care Unit for at least 48 h of brainwaves analysis. Resection of the epileptic lesion around the eloquent area was performed in an awake state only after concordant findings were confirmed in all modalities of investigation.

Matlab and statistical parametric mapping analysis

A home-made Matlab (matrix laboratory, MathWorks, Natick, MA) MEG-pipeline was used to further analyze the MEG data. This was done using Matlab statistical parametric mapping (SPM) to diffusely localize the eloquent area based on popular toolboxes.^[12] Standard neuroscience spectral data analysis such as analysis of the region of interest (ROI) with concomitant detection of significantly active regions that respond to external stimuli and inverse solutions for EEG/MEG data were commonly utilized.

Results

Subjects and analysis

All 10 patients had MEG recordings in seated position with eyes-open. MEG data was analyzed prior and after the surgery in two patients to disclose the properties of brain oscillation [Figures 3 and 4]. While in the third patient, the synchronized oscillation and networks was noted on scalp EEG during awake surgery [Figure 5]. Networks mapping and neuroplasticity evaluation were performed in five patients (two were depicted here): Patient with a thalamic lesion [Figure 6]; cerebral peduncle hemorrhage [Figure 7]; an insular glioma and a basal ganglia and internal capsule AVMs. Finally, two patients had MEG recordings to localize their epileptogenic zones, and one of the patients also had ECoG implantation to confirm the MEG findings [Figure 8].

Neural oscillation

A 56-year-old female was operated for a right frontal anaplastic astrocytoma. Prior to surgery, she had marked deficits in cognition. She had poor attention, was socially isolated and became inactive. In addition, she also had marked weakness of her left limbs. Her conditions improved after the surgery – she became more active, and the weakness markedly improved. The spontaneous resting eye-open presurgery MEG brainwaves

were compared with postsurgery brainwaves. The analysis revealed marked changes in brainwave patterns after tumor removal, not only in the brain hemisphere which harbored the tumor, but also in the opposite hemisphere [Figure 3a-c]. More activities or less slow wave patterns were recorded in both hemispheres after tumor resection. This corresponded to the marked improvement in patient's clinical conditions. Similar findings were recorded for another patient who had a large cribriform plate meningioma compressing the frontal lobes. The analysis again showed marked improvements in both; brainwaves frequency and clinical conditions after the surgery [Figure 4a-d]. Another patient that demonstrated oscillatory activity is the one who had awake surgery for a metastatic lesion at right sensorimotor gyrus. The cortical stimulation of the ipsilateral motor gyrus induced contralateral upper limb muscles contraction and EEG-evoked responses at the opposite hemisphere over the sensorimotor gyrus. This response was noted on each stimulation and shown in Figure 5a-d. Since the falx cerebri divides both brain hemispheres, the contralateral evoked responses noted on scalp EEGs during awake stimulation is believed to arise from the propagated waves that passed through the normal anatomical tract, either via the corpus callosum or other white matter fibers/tracts. This indirectly signifies there is either a closed networks between the two areas or simply means that, they are in a state of synchronized oscillations (either inhibitory or stimulatory).

Brain network and neuroplasticity

A 12-year-old boy with a right thalamic lesion [Figure 6a], presented with marked left sided dystonia that predominated in the upper limb and mild gait ataxia. There was no actual limb weakness. The high amplitude spike-like hyperactive brain network analysis revealed several regions of his brain were activated: The cortical sensorimotor areas, the midbrain diencephalon and the ipsilateral cerebellar cortex [Figure 6b and c]. The lesion was mapped using the Schaltenbrand-Wahren atlas and found mainly within ventral anterior (VA) and part of ventral lateral (VL) nucleus of the thalamus [Figure 6d]. The ventral group of thalamic nucleus is well known to participate in controlling the muscles tone and precision of limb movements. These areas are well described having connections with ipsilateral cerebellar cortex and to the sensorimotor areas. These features are well illustrated in this case. Another interesting network case is a 34-year-old man who suffered from a localized right cerebral peduncle hemorrhage [Figure 7a and b]. He currently suffers from resting and postural left hand tremors. The brain networks analysis for hyperactive brain regions disclosed the following brain areas were activated: Part of the thalamus and subthalamic nucleus, pons and ipsilateral cerebellar nuclei [Figure 7c and d]. These activated brain areas are thought to contribute to his persistent tremors. The two examples mentioned above highlight the importance of brain networks in causing various clinical

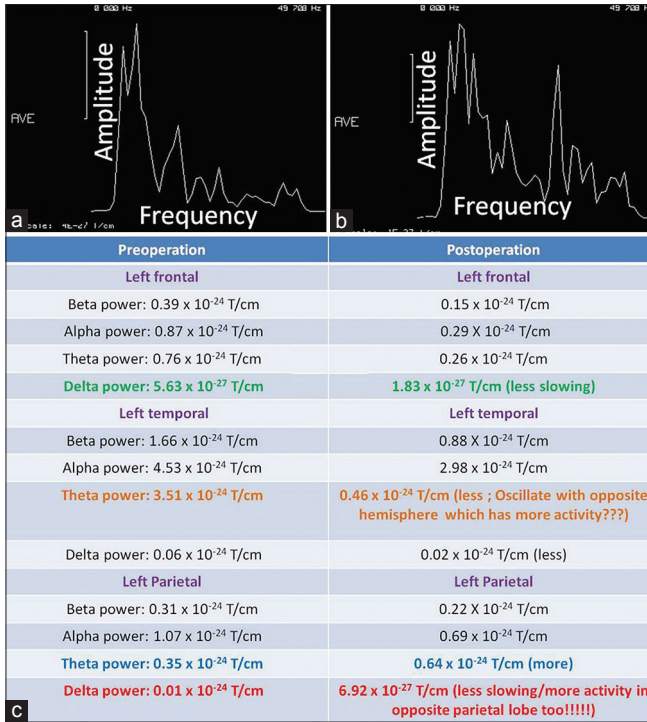


Figure 3: Fast Fourier transformation to analyze average brain rhythms amplitude and frequency spectrum for each lobe of the brain according to Neuromag magnetoencephalography-head channels. The patient had a tumor over the right frontal lobe. The brainwaves amplitude improved almost in all rhythms after the surgery even at opposite hemisphere (a) before; (b) after surgery. (c) Opposite hemisphere brainwaves analysis disclosed decreased amplitude in delta waves for frontal, temporal and parietal lobes suggesting more brain activity after the surgery

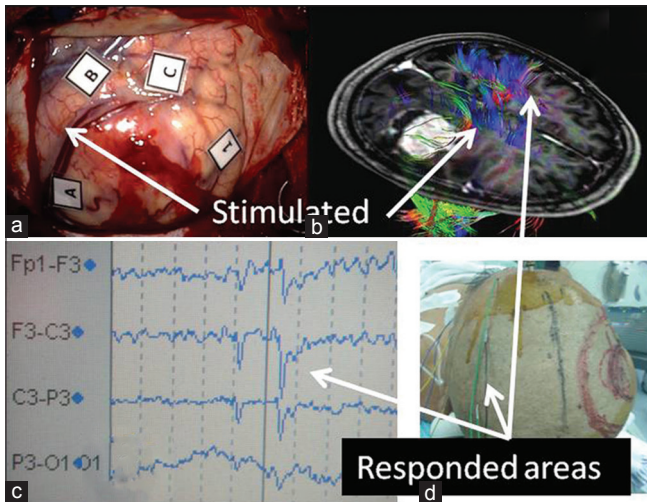


Figure 5: Neural in oscillation. Stimulation at right motor cortex (a and b) resulted in jerky movements of left upper limb and evoked responses on scalp electroencephalographs in the opposite hemisphere at region of hand motor cortex (b-d)

manifestations. Notion of a single area of the brain being responsible for single manifestation (one to one) seems unacceptable based on what we have currently learned. Similar analysis was performed for three other patients [Table 1]: Patient

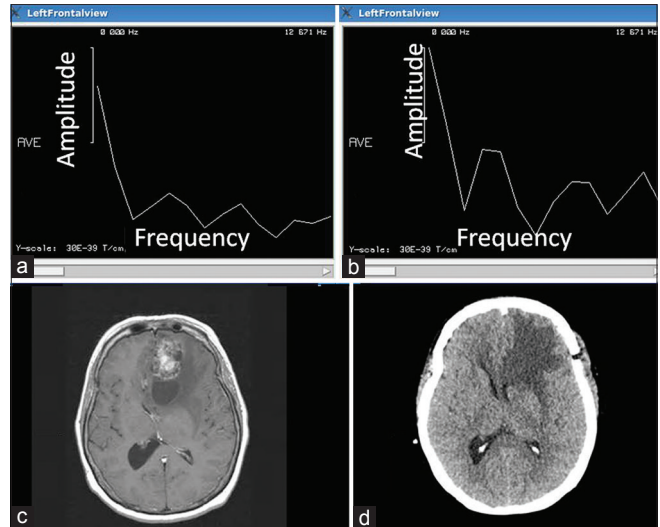


Figure 4: (a and c) Brainwaves frequency spectral analysis before and (b and d) after the surgery for large cribriform plate meningioma

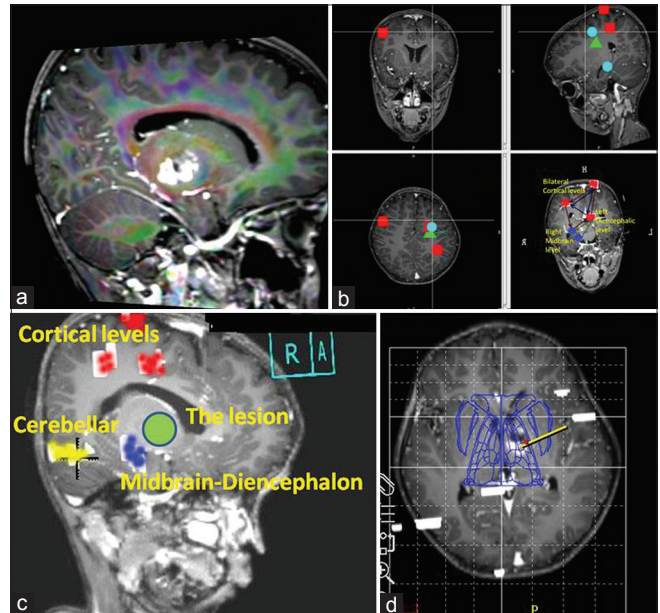


Figure 6: Brain networks analysis using collection of hyperactivated events. The right thalamic lesion (a) which causing left hand dystonia was mapped at ventral group of thalamic nucleus (d). The hyperactivated brain networks (b and c)

with an insular glioma (hyperactive brainwaves analysis) and patients with AVMs at the internal capsule and basal ganglia respectively (hypoactive or slow waves [delta waves] analysis). In general, the brain networks analysis disclosed far-distance brain regions, which could be labeled as either their network partners or newly recruited brain areas that became active to compensate for any deficit (neuroplasticity).

Epileptogenic zone and eloquent cortex

An 18-year-old man underwent preoperative evaluations for epilepsy surgery. His EEG was unremarkable, but his MEG disclosed significant spikes around the lesion [Figure 8a-c].

Table 1: The value of MEG in managing the patients

Patient	Diagnosis	MEG analysis	MEG/EEG/ECOG findings	Impact MEG on patient management or neuroscience
Case 1	Right frontal anaplastic astrocytoma	Neural oscillation	Comparing pre- and postsurgery brain oscillation: Improved	For future understanding in functional neurosurgery and clinical neuroscience; and as a method to evaluate patient outcome
Case 2	Cribriform plate meningioma	Neural oscillation	Comparing pre- and postsurgery brain oscillation: Improved	For future understanding in functional neurosurgery and clinical neuroscience; and as a method to evaluate patient outcome
Case 3	Right sensori-motor metastasis (awake surgery)	Neural oscillation/localize eloquent areas	Right and left sensorimotor cortices are interconnected and may play a role in neuroplasticity The MEG identified eloquent areas were tally with intraoperative findings	For future understanding in functional neurosurgery and clinical neuroscience. MEG helps the surgeon to localize “quickly” the eloquent areas
Case 4	Thalamic glioma	Brain networks/ neuroplasticity	Multiple brain areas were activated which corresponded to previous clinico-anatomical knowledge	For future understanding in functional neurosurgery and basic neuroscience
Case 5	Cerebral peduncle hemorrhage	Brain networks/ neuroplasticity	Multiple brain areas were activated which corresponded to previous clinico-anatomical knowledge	For future understanding in functional neurosurgery and basic neuroscience
Case 6	Insular gliomas	Brain networks/ neuroplasticity	Multiple brain areas were activated which corresponded to previous clinico-anatomical knowledge	For future understanding in functional neurosurgery and basic neuroscience
Case 7	Internal capsule AVM	Brain networks/ neuroplasticity	Connectivity to sensorimotor cortices bilaterally	For future understanding in functional neurosurgery and basic neuroscience
Case 8	Basal ganglia AVM	Brain networks/ neuroplasticity	Connectivity to sensorimotor cortices bilaterally	For future understanding in functional neurosurgery and basic neuroscience
Case 9	Left sensori-motor cortical dysplasia with epilepsy (awake surgery)	Localize the epileptogenic zone/localize the eloquent areas	MEG epileptogenic zone findings were in concordance with ECOG The MEG identified eloquent areas were tally with intraoperative findings	MEG provides information allowing “targeted invasive ECOG” and well localize the eloquent cortices
Case 10	Left angular gyrus low grade glioma with frequent speech arrest and seizures	Localize the epileptogenic zone/localize the eloquent areas	MEG localized the epileptogenic zone close to the lesion	MEG provides information on epileptogenic zone and localizes the eloquent cortices

MEG – Magnetoencephalography; EEG – Electroencephalography; ECOG – Electrocrusticography; AVM – Arteriovenous malformation

He underwent subdural grid electrodes implantation and was found to have significant epileptic spikes and spike-waves over the MEG-identified epileptogenic zones [Figure 8d and e]. Resection of the lesion as well as multiple subpial transection (MST) was performed. His ECOG and MEG after the surgery showed absence of abnormal spikes and spike-waves, and the patient has been seizure free since [Figure 8f and g]. During awake surgery for excision of a lesion in or around eloquent brain areas, the overdetermined ECD method was used to localize the eloquent cortices in all cases, as shown in Figure 9a: The blue dot represents the maximum magnetic vector for motor area, and the green dot localizes the sensory area. The red dot which lies close to low-grade tumor area is used here to illustrate the epileptogenic zone which was seen in another patient who was also suffering from refractory epilepsy [Figure 9b]. Besides simple ECD method, we also utilized home-made Matlab based underdetermined inverse solution (MEG-pipeline software) to localize the eloquent cortices [Figure 9c and d].

Summary of the results

The MEG-identified magnetic evoked fields for eloquent cortices were found to correspond to our findings based on intraoperative brain mapping using the Ojemann neurostimulator (Radionics, Inc., Burlington, MA). Similarly, the MEG-identified region for epileptic spikes tallied with our ECOG findings. In view of our encouraging results (good correlation between the MEG signal analysis and intraoperative findings), we proceeded with brain network analysis by using a selected epoch of hyperactive (spikes) or hypoactive (slow waves: Theta and/or delta waves) brainwaves. Since there is no established gold-standard in current literatures to analyze brain networks, our findings in brain networks analysis by using the collection of events method are open to criticism. Interestingly, our examples of networks analysis did show some degree of clinico-anatomical correlation among various activated brain regions. Finally, our home-made Matlab software with MEG-pipeline to analyze spontaneous and evoked MEG magnetic fields seems encouraging for our

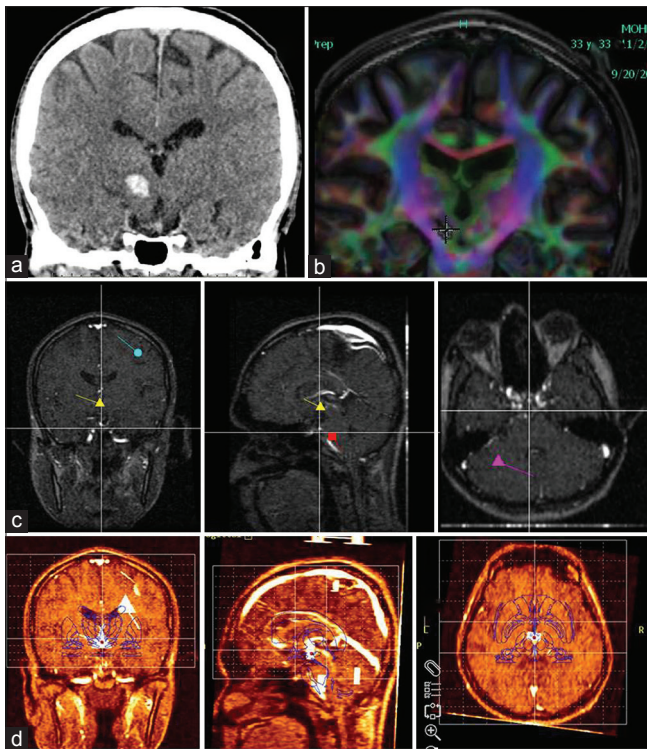


Figure 7: (a) The right cerebral peduncle hemorrhage (b) near the descending corticospinal tract (c) brain networks analysis (d) mapping of the hyperactivated regions

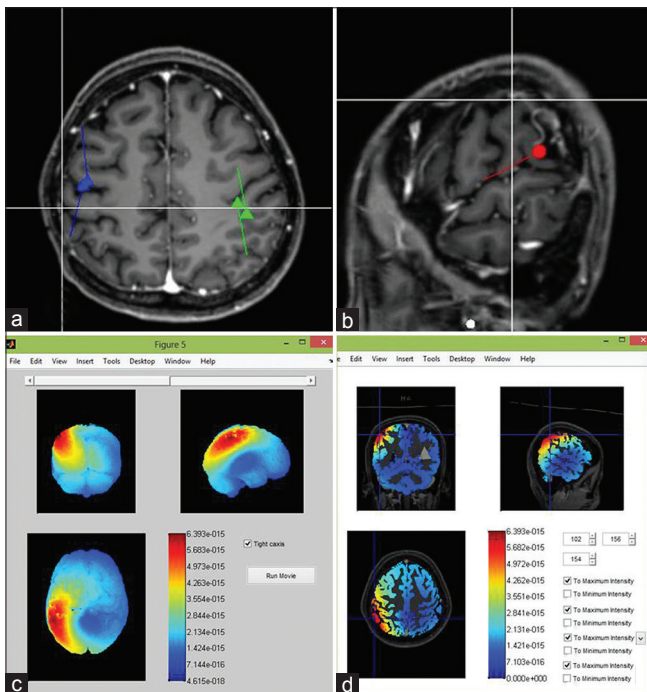


Figure 9: (a) The equivalent current dipole shows maximum magnetic vector for motor (blue) and sensory (green) areas. (b) The brainwaves spike analysis disclosed the red area representing the epileptogenic zone. (c and d) Matlab inverted problem analysis using magnetoencephalography-pipeline show activated motor area (diffused red color)

future work. Table 1 summarizes the value of MEG in all of our evaluated patients.

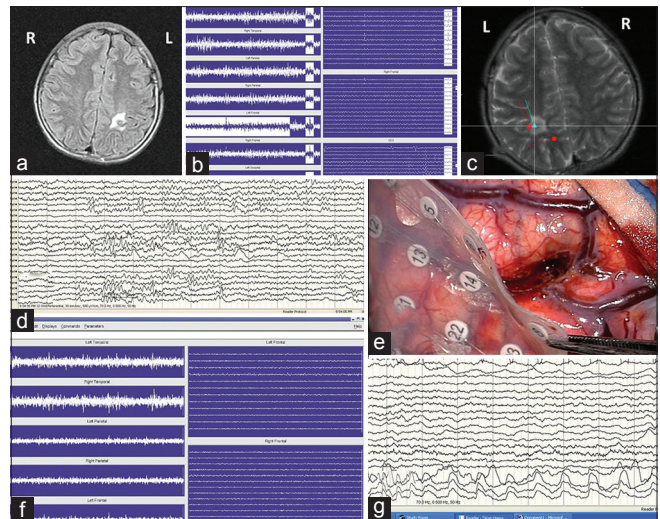


Figure 8: Epilepsy surgery. (a) A lesion at left sensorimotor cortex. (b and c) The magnetoencephalography (MEG) brainwaves analysis revealed spikes at and around the lesion. (d and e) The grid electrodes were implanted and showed areas of spikes which correspond to MEG findings. (f and g) The MEG and electrocorticography after the surgery showed absence spikes and spikewaves

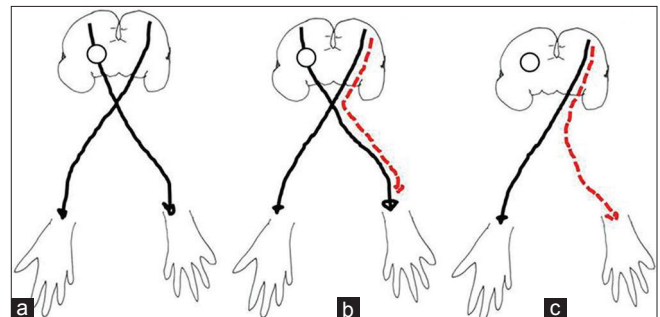


Figure 10: The affected hand due to a lesion (circle) can still receive contralateral projection (a) mixed projection from both affected and (b) unaffected hemisphere and (c) only ipsilateral projection

Discussion

Neural oscillation

Magnetoencephalography is one of the modalities of functional neuroimaging which may demonstrate specific functional and abnormal areas of the brain and may show a greater area of involvement than structural neuroimaging. Therefore, MEG can be used to map the eloquent cortex, hyperactivated or hypoactivated brainwaves areas, identify the epileptogenic zones and to study brain networks and neuronal plasticity.^[13-15] Since neural oscillations generate brainwaves, which are commonly classified according to their frequency (gamma/beta/alpha/theta/delta), their analysis can be used to study any correlation between patients improvement after brain surgery with patterns of brain rhythms. Cases 1 and 2 illustrate the possible use of MEG to analyze brain rhythms before and after the surgery. Improvement in both, brain rhythms magnetic amplitude (femtotesla) or spectral frequency (Hz), and patient condition after the surgery was noted. The analysis

revealed improvement not only in the ipsilateral hemisphere to the lesion but also at the contralateral side. This may indicate that synchronized neural oscillations among various regions of the brain do occur, and its betterment may correlate with clinical improvement. Existence of synchronized neural oscillation is further supported by our third patient (case 3). This patient underwent awake surgery for a single metastatic lesion close to the right sensorimotor gyrus. During the procedure, the area representing the upper limb segment of the motor-cortex (which was mapped extraoperatively by MEG) was stimulated, and interestingly enough, not only were their jerky movements in the contralateral upper limb, but also significant evoked responses in the motor area at the opposite hemisphere (EEG scalp electrodes were monitored in the opposite hemisphere). Since there is falx and other nonneural tissues intervening in the midline, the activation of the opposite hemisphere at middle-motor-cortex scalp EEG electrodes are thought to arise from brainwave propagation along the anatomical neural tracts or pathways. This could be via the corpus callosum or thalamocortical circuit.^[16,17] This dual activation or dual descending circuits is thought to become functional (recruitment) whenever there is injury to any one of them. Staudt *et al.* and Vandermeeren *et al.*, had shown one sided injury to the corticospinal tract may cause recruitment and activation in the contralateral tract (brain compensation and neuroplasticity).^[18,19] Their findings of different types of possible reinnervation or compensation for descending motor tract are summarized in Figure 10.

Brain networks and neuroplasticity

Magnetoencephalography is seen as a promising tool for investigating human brain activity particularly due to its good temporal and spatial resolution. When source localization was made from MEG data and fused with anatomical MRI images, the new images were labeled as MSI.^[14] Multiple localizations for hyperactivated or hypoactivated areas can be performed by using the collection of events method. By selecting certain brainwaves with a particular amplitude (example: Above 10% or more from normal), the ROI can be mapped. If there were more than one brainwave area with brainwave amplitude above the selected threshold, the ROI becomes multiple. Multiple ROIs create patterns of brain networks (which can be mapped). The created network is normally peculiar to that hyperactivated or hypoactivated brainwaves, and this abnormal brainwaves can be the source of abnormal clinical manifestations. Cases 4 and 5 illustrate brain networks which could be responsible for dystonia (case 4) and tremors (case 5). A lesion at ventral group of thalamic nucleus, especially the VA and VL are known to produce limb dystonia and ataxia. The connectivity of these nuclei with cerebellar nuclei, basal ganglia and sensorimotor cortex are well-depicted here and by others.^[20,21] Similarly in case 5 [Figure 7], a lesion at the cerebral peduncle may cause persistent tremors because of MEG-disclosed hyperactivated regions in the thalamus (coronal view), subthalamic

nucleus (axial), pontine and cerebellar nuclei (sagittal). We obtained MEG activated areas encompassing the whole brain including both, superficial and deep structures. Our findings are in agreement with other recent studies which found, that MEG can also detect activation areas deep inside the brain and noteworthy, our obtained brain network patterns for certain body functions are concordant with our current clinico-anatomical knowledge.^[22-24] Nonetheless, ones must remember that source localization in MEG is an ill-posed problem^[25] and therefore more studies are needed to validate our methods and to confirm the findings.

Epileptogenic zone and eloquent cortex

Lesion seen on anatomical MRI may not be responsible for abnormal brainwaves (spikes/spikewaves). The foci for epileptogenic zones may lie peripheral to the lesion or may even be distant. This structural versus functional mismatch revealed by MEG makes it pertinent in the presurgical evaluation of patients with refractory epilepsy. Studies have found that by adding MEG to the conventional presurgical evaluations, the number of patients who become eligible for epilepsy surgery may increase.^[26,27] Cases 9 and 10 highlight this point, the scalp and video EEG were unable to localize the seizure focus, but by adding MEG to the presurgical armamentarium, the foci became well localized and in one of these two patients (the second one is awaiting surgery), the ECoG findings are in good agreement (concordance) with the MEG spike areas. He became seizure free after having the lesion removed and MST onto the sensorimotor gyrus-epileptogenic zones identified by both; MEG and ECoG.

Besides overdetermined ECD method which is preinstalled inside the Neuromag computer software (commonly used for our awake surgery cases), other method to localize the eloquent cortices includes the use of underdetermined inversed solutions. The Matlab SPM is used to diffusely localize the eloquent cortex.^[12,28] This method is capable of mapping the brain, and its findings are commonly illustrated in spectral graphical forms with more diffused activated areas than the ECD method (this modality is widely used in analyzing massive data: In the fields of engineering, neuroscience and astronomy). Using our current MEG methods: ECD source localization or inversed solutions to map eloquent cortex and collection of events for epileptogenic zone, we found that MEG signals localization is in agreement with our intraoperative awake brain mapping findings. These findings further validate other studies, which found good correlation between MEG and intraoperative findings.^[29-31]

Conclusion

Magnetoencephalography is relatively new functional neuroimaging which lately has gained much popularity. This is mainly attributed to its capability to study brain activity and therefore open new windows for researchers to study

brain oscillation, neuroplasticity and networks. This modality also assists the neurosurgeon in mapping eloquent cortical areas and is useful for localizing epileptogenic zones. Our early experience with MEG supports its undoubted value in epilepsy surgery and for mapping functional brain areas, while simultaneously enriching our knowledge in functional neurosurgery and neuroscience.

References

1. Idris Z, Nazaruddin WH, Muzaimi M, Badriyah I, Rahman IG, Jafri MA. Functional MRI, diffusion tensor imaging, magnetic source imaging and intraoperative neuromonitoring guided brain tumor resection in awake and under general anaesthesia. In: Lichtor T, editor. *Clinical Management and Evolving Novel Therapeutic Strategies for Patients with Brain Tumors*. InTech; 2013. p. 17-54. Available from: <http://www.intechopen.com/books/clinical-management-and-evolving-novel-therapeutic-strategies-for-patients-with-brain-tumors/functional-mri-diffusion-tensor-imaging-magnetic-source-imaging-and-intraoperative-neuromonitoring-g> free accessed via google on 26.6.2013. Lo CY, He Y, Lin CP. Graph theoretical analysis of human brain structural networks. *Rev Neurosci* 2011;22:551-63.
2. Lo CY, He Y, Lin CP. Graph theoretical analysis of human brain structural networks. *Rev Neurosci* 2011;22:551-63.
3. van den Heuvel MP, Stam CJ, Boersma M, Hulshoff Pol HE. Small-world and scale-free organization of voxel-based resting-state functional connectivity in the human brain. *Neuroimage* 2008;43:528-39.
4. Bosboom JL, Stoffers D, Stam CJ, van Dijk BW, Verbunt J, Berendse HW, *et al.* Resting state oscillatory brain dynamics in Parkinson's disease: An MEG study. *Clin Neurophysiol* 2006;117:2521-31.
5. Fernández A, Hornero R, Gómez C, Turrero A, Gil-Gregorio P, Matías-Santos J, *et al.* Complexity analysis of spontaneous brain activity in Alzheimer disease and mild cognitive impairment: An MEG study. *Alzheimer Dis Assoc Disord* 2010;24:182-9.
6. Li Y, Tong S, Liu D, Gai Y, Wang X, Wang J, *et al.* Abnormal EEG complexity in patients with schizophrenia and depression. *Clin Neurophysiol* 2008;119:1232-41.
7. Bullmore E, Sporns O. The economy of brain network organization. *Nat Rev Neurosci* 2012;13:336-49.
8. McConnell GC, So RQ, Hilliard JD, Lopomo P, Grill WM. Effective deep brain stimulation suppresses low-frequency network oscillations in the basal ganglia by regularizing neural firing patterns. *J Neurosci* 2012;32:15657-68.
9. Funke M, Constantino T, Van Orman C, Rodin E. Magnetoencephalography and magnetic source imaging in epilepsy. *Clin EEG Neurosci* 2009;40:271-80.
10. Heers M, Rampp S, Stefan H, Urbach H, Elger CE, von Lehe M, *et al.* MEG-based identification of the epileptogenic zone in occult peri-insular epilepsy. *Seizure* 2012;21:128-33.
11. Bartolomei F, Bosma I, Klein M, Baayen JC, Reijneveld JC, Postma TJ, *et al.* Disturbed functional connectivity in brain tumour patients: Evaluation by graph analysis of synchronization matrices. *Clin Neurophysiol* 2006;117:2039-49.
12. Litvak V, Mattout J, Kiebel S, Phillips C, Henson R, Kilner J, *et al.* EEG and MEG data analysis in SPM8. *Comput Intell Neurosci* 2011;2011:852961.
13. Tarapore PE, Martino J, Guggisberg AG, Owen J, Honma SM, Findlay A, *et al.* Magnetoencephalographic imaging of resting-state functional connectivity predicts postsurgical neurological outcome in brain gliomas. *Neurosurgery* 2012;71:1012-22.
14. Alberstone CD, Skirboll SL, Benzel EC, Sanders JA, Hart BL, Baldwin NG, *et al.* Magnetic source imaging and brain surgery: Presurgical and intraoperative planning in 26 patients. *J Neurosurg* 2000;92:79-90.
15. Stefan H, Wu X, Buchfelder M, Rampp S, Kasper B, Hopfengärtner R, *et al.* MEG in frontal lobe epilepsies: Localization and postoperative outcome. *Epilepsia* 2011;52:2233-8.
16. O'Muirheartaigh J, Vollmar C, Barker GJ, Kumari V, Symms MR, Thompson P, *et al.* Abnormal thalamocortical structural and functional connectivity in juvenile myoclonic epilepsy. *Brain* 2012;135:3635-44.
17. Netz J, Ziemann U, Hömberg V. Hemispheric asymmetry of transcallosal inhibition in man. *Exp Brain Res* 1995;104:527-33.
18. Staudt M, Grodd W, Gerloff C, Erb M, Stitz J, Krägeloh-Mann I. Two types of ipsilateral reorganization in congenital hemiparesis: A TMS and fMRI study. *Brain* 2002;125:2222-37.
19. Vandermeeren Y, Davare M, Duque J, Olivier E. Reorganization of cortical hand representation in congenital hemiplegia. *Eur J Neurosci* 2009;29:845-54.
20. Tsang EW, Hamani C, Moro E, Mazzella F, Lozano AM, Yeh JJ, *et al.* Prominent 5-18 Hz oscillations in the pallidal-thalamic circuit in secondary dystonia. *Neurology* 2012;78:361-3.
21. Oropilla JQ, Diesta CC, Itthimathin P, Suchowersky O, Kiss ZH. Both thalamic and pallidal deep brain stimulation for myoclonic dystonia. *J Neurosurg* 2010;112:1267-70.
22. Ioannides AA, Fenwick PB. Imaging cerebellum activity in real time with magnetoencephalographic data. *Prog Brain Res* 2005;148:139-50.
23. Kanal EY, Sun M, Ozkurt TE, Jia W, Scwabassi R. Magnetoencephalographic imaging of deep corticostriatal network activity during a rewards paradigm. *Conf Proc IEEE Eng Med Biol Soc* 2009;2009:2915-8.
24. Ozkurt TE, Sun M, Scwabassi RJ. Decomposition of magnetoencephalographic data into components corresponding to deep and superficial sources. *IEEE Trans Biomed Eng* 2008;55:1716-27.
25. Darvas F, Pantazis D, Kucukaltun-Yildirim E, Leahy RM. Mapping human brain function with MEG and EEG: Methods and validation. *Neuroimage* 2004;23 Suppl 1:S289-99.
26. Knowlton RC. Can magnetoencephalography aid epilepsy surgery? *Epilepsy Curr* 2008;8:1-5.
27. Pataria E, Simos PG, Castillo EM, Billingsley RL, Sarkari S, Wheless JW, *et al.* Does magnetoencephalography add to scalp video-EEG as a diagnostic tool in epilepsy surgery? *Neurology* 2004;62:943-8.
28. Onozuka M, Yen CT, Ono Y, Ishiyama A. Magnetoencephalography: Basic theory and estimation techniques of working brain activity. In: Onozuka M, Yen CT, editors. *Novel Trends in Brain Science*. Japan: Springer; 2008. p. 77-93.
29. Schiffbauer H, Berger MS, Ferrari P, Freudenstein D, Rowley HA, Roberts TP. Preoperative magnetic source imaging for brain tumor surgery: A quantitative comparison with intraoperative sensory and motor mapping. *J Neurosurg* 2002;97:1333-42.
30. Roberts TP, Ferrari P, Perry D, Rowley HA, Berger MS. Presurgical mapping with magnetic source imaging: Comparisons with intraoperative findings. *Brain Tumor Pathol* 2000;17:57-64.
31. Korvenoja A, Kirveskari E, Aronen HJ, Avikainen S, Brander A, Huttunen J, *et al.* Sensorimotor cortex localization: Comparison of magnetoencephalography, functional MR imaging, and intraoperative cortical mapping. *Radiology* 2006;241:213-22.

How to cite this article: Idris Z, Kandasamy R, Reza F, Abdullah JM. Neural oscillation, network, eloquent cortex and epileptogenic zone revealed by magnetoencephalography and awake craniotomy. *Asian J Neurosurg* 2014;9:144-52.

Source of Support: Nil, **Conflict of Interest:** None declared.