

# Sellar repair with autologous muscle and composite septal cartilage grafts for treatment of cerebrospinal fluid leakage following trans-sphenoidal pituitary surgery

Ayman A. El Shazly, Mohammed A. El Wardany, Tamer A. Abo El Ezz<sup>1</sup>

Departments of Neurosurgery and <sup>1</sup>Otorhinolaryngology, Ain Shams University, Ramses Extension Road, Abbasia Square, Cairo, Egypt

## ABSTRACT

**Context:** Many reconstructive techniques have been proposed to prevent postoperative cerebrospinal fluid (CSF) leakage after trans-sphenoidal pituitary surgery. However, no total agreement has been reached to the best technique.

**Aim:** Assessment of the efficacy of sellar repair with autologous muscle and composite septal cartilage grafts for treatment of intraoperative and delayed postoperative CSF leakage following trans-sphenoidal pituitary surgery without the use of postoperative external lumbar CSF drain.

**Study Design:** This is a retrospective case series study, level IV evidence.

**Materials and Methods:** Twenty three patients were involved in this study. Seventeen patients had intraoperative CSF leakage and were treated immediately by our technique. Six patients had postoperative CSF rhinorrhea and had delayed treatment with our technique after failure of conservative measures and external lumbar CSF drainage for more than three days. The technique involved intradural placement of autologous muscle graft supplemented with extradural composite septal cartilage graft, composed of a piece of the posterior cartilaginous septum with its covering mucoperichondrium on one side only to fit into the sellar defect as a double layer button.

**Results:** CSF leak was of grade 1 in 6 patients (26.1%), grade 2 in 10 patients (43.5%) and grade 3 in 7 patients (30.4%). None of the patients in our study had postoperative CSF leak after the use of our technique during the follow up period (mean  $24 \pm 10.47$  standard deviation months). None of the patients developed treatment-related complications. All the patients had well developed mucosal covering of the sellar defect after two months.

**Conclusion:** Our technique of sellar repair by using autologous muscle and composite septal cartilage grafts is effective in treatment of intraoperative and delayed postoperative CSF leakage following trans-sphenoidal pituitary surgery without the use of postoperative external lumbar CSF drain even in the high-output CSF leaks.

**Key words:** Cerebrospinal fluid rhinorrhea, composite septal cartilage, pituitary adenoma, sella, trans-sphenoidal

Access this article online	
Quick Response Code:	Website: www.asianjns.org
	DOI: 10.4103/1793-5482.144157

### Address for correspondence:

Dr. Ayman A. El Shazly, Department of Neurosurgery, Ain Shams University, Ramses Extension Road, Abbasia Square, Cairo, Egypt. E-mail: shazlyneuro@yahoo.com

## Introduction

The trans-sphenoidal surgical approach is the preferred method for pituitary tumor resection. In experienced hands, this procedure is considered safe with low morbidity and mortality rates.<sup>[1,2]</sup> One of the most serious non-endocrine post trans-sphenoidal potential complication is cerebrospinal fluid (CSF) leakage.<sup>[3-5]</sup> Serious complications may occur as sequelae of CSF leakage such as meningitis and tension pneumocephalus.<sup>[4]</sup> The incidence of postoperative CSF leakage after trans-sphenoidal surgery has been reported to range from 0.5-15%, with the majority of authors reporting incidences between 0.5% and 6.0%.<sup>[3-5]</sup>

Postoperative CSF leakage typically results from the inadequate repair of a CSF fistula created at the time of the initial operation.<sup>[6]</sup> A variety of methods for reconstruction of the sellar floor have been recommended to avoid postoperative CSF leakage. Autologous materials for example fat, fascia, muscle, cartilage, bone and mucoperiosteal grafts have been used.<sup>[3,4,7-13]</sup> Although autologous tissue grafts are indisputably biocompatible, in many cases they need postoperative external lumbar drain to decrease CSF pressure on the graft and keep the graft in place until healing of the arachnoid is achieved.<sup>[6,14]</sup>

Heterologous and synthetic materials, for example ceramic,<sup>[15]</sup> titanium,<sup>[16]</sup> stainless steel,<sup>[17]</sup> silicone,<sup>[18,19]</sup> bone cement,<sup>[20]</sup> and resorbable materials,<sup>[6,14,16,21-25]</sup> have also been used to repair the sellar floor. These materials can prevent postoperative CSF leakage. However their slow adhesion to surrounding tissues leads many surgeons to use postoperative external lumbar CSF drain to confirm sealing of the sellar floor, especially in patients with large CSF leakage. Using postoperative external lumbar CSF drain would result in prolonged hospital stay and increased risk of meningitis.<sup>[2,19]</sup> Other disadvantages of these heterologous and synthetic materials include tissue reaction, increase total cost of the procedure and possibility of transmission of viral diseases if biological components are used.<sup>[24,25]</sup>

In this study we describe a modified technique which utilizes multi-layered autologous grafts for sellar repair and treatment of CSF leakage following trans-sphenoidal pituitary surgery. The technique involves intradural placement of autologous muscle graft supplemented with extradural composite septal cartilage graft, composed of a piece of the posterior cartilaginous septum with its covering mucoperichondrium on one side only to fit into the sellar defect as double layer button. The purpose of this study is to assess the efficacy of this technique for treatment of intraoperative and delayed postoperative CSF leakage following trans-sphenoidal pituitary surgery without the use of postoperative external lumbar CSF drain.

## Materials and Methods

This retrospective case series study was conducted on 23 patients with CSF leakage following trans-sphenoidal excision of pituitary adenoma and were treated with autologous muscle graft and composite septal cartilage graft during the period between January 2005 and October 2011. The patients were classified into two groups according to the time of repair. Group A; composed of 17 patients out of 203 cases of trans-sphenoidal excision of pituitary adenoma done by the authors during this period. The patients in this group had intraoperative CSF leakage and they were treated immediately by our technique. Group B; composed of 6 patients who were referred to the authors complaining of persistent postoperative CSF rhinorrhea following trans-sphenoidal excision of

pituitary adenoma and failed to respond to conservative measures (included antibiotics, cautioning patients not to blow their nose and to avoid sneezing, coughing, or any activities that stimulate straining, bed rest with elevation of head of bed at 30°) and external lumbar CSF drainage for more than three days. The patients in this group had a second operation and delayed treatment of their CSF leakage with our technique.

All the patients had preoperative full clinical, neuro-ophthalmological and endocrinological evaluation. Radiological investigations included both a pre-operative contrasted computed tomography (CT) and magnetic resonance imaging (MRI) of the brain.

Intraoperative CSF leaks were classified as Grade 1, small leak confirmed by a Valsalva maneuver without obvious diaphragmatic defect; Grade 2, moderate leak; or Grade 3, large diaphragmatic defect with associated leak.<sup>[26]</sup>

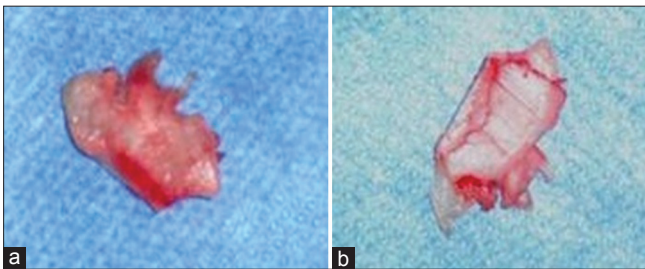
## Surgical technique

After induction of general anesthesia the endotracheal tube was placed in the left angle of the mouth and pharyngeal pack of wet gauze was introduced. The patient was placed in supine position with the patient's head slightly extending by lowering the head rest of the operating table about 10°. The mucosa of the nasal septum on the right side was infiltrated with 0.5% procaine containing epinephrine (1:200,000) to facilitate dissection and decrease bleeding by spreading the perichondrium from the underlying cartilage on the right side and preserving it attached to the cartilage on the left side. Incision was made in the perichondrium on the right side one inch posterior to the columella. By dissection in the cleavage plane between the cartilage and mucosa/perichondrium with a dissector, a mucosal tunnel was created. The mucosal tunnel was extended basally to the maxillary crest and advanced posteriorly as far as the sphenoid rostrum. A small conical speculum was inserted to displace the cartilage to the opposite side and the microscope was introduced at this stage. In group A and group B when a bony septum was preserved, the border between the bony septum and the cartilage was separated with a dissector and the bony septum was exposed in the midline between the blades of the speculum. The bony septum was removed with rongeurs, and the mucosal tunnel was extended down to the floor of the sphenoid sinus, followed by insertion of a large speculum. The sphenoid sinus was opened with a diamond drill and with a punch (group A). The sphenoid mucosa was stripped off with forceps, and the sphenoid septum was removed with a rongeur and a diamond drill. The sellar floor is opened with a diamond drill and a punch (group A). After dural incision and excision of the adenoma in group A or removal of the packing and reconstructing materials in group B a Valsalva maneuver was performed to identify the site of CSF leakage and to determine its grade. Then the speculum

was removed. A piece of the posterior cartilaginous septum with its covering perichondrium and nasal mucosa on the left side was harvested according to the size of the defect. This piece was usually  $1.5 \times 1.5$  cm (about 20% larger than the sellar defect). The cartilage was fissured into 3 or 4 parts leaving its covering mucoperichondrium intact to make this graft pliable to fit into the sellar defect [Figure 1]. A small skin incision (about 2 cm) was done in the upper lateral part of the thigh and small muscle graft was harvested from the vastus lateralis muscle. The speculum was introduced again. Care was taken to keep the blades just outside the sphenoid sinus to prevent fractures of the lateral walls of the sphenoid when opening the speculum. The muscle graft was introduced into the intradural space over the arachnoid defect. The composite septal cartilage graft was placed to fit into the sellar defect as a double layer button. The bare cartilage was placed intrasellar facing the dura. The mucoperichondrium was placed extrasellar facing the sphenoid sinus [Figure 2]. Then the speculum was removed and the septal mucosa was re-approximated and maintained with endonasal merocel tampons. The small incision in the thigh was closed cosmetically by using continuous subcuticular absorbable sutures.

All the patients were transferred to the ward after surgery without external CSF lumbar drain. The patients received postoperative antibiotics for at least 48 hours. The nasal packs were removed after 48 hours and CSF rhinorrhea was examined with the patient in the sitting position.

The patients were discharged to home after removal of nasal packs if no complications were identified. All patients had routine follow-up reviews at 2 weeks, 1 months, 2 months, 6 months, and 12 months postoperatively. All the patients underwent clinico-endoscopic assessment 2 weeks, 1 month, and 2 months after the operation at the minor surgery outpatient clinic to observe the conditions of sellar floor and to remove the crustations over the septum until complete healing. Examination of the patient's field of vision, along with an ophthalmology assessment was done at 1 and 6 months postoperatively. All patients had endocrinological evaluation at 1 and 6 months, and MR studies with and without gadolinium at 2 and 12 months postoperatively.



**Figure 1:** Our composite septal cartilage graft with its, (a) Mucoperichondrial surface and, (b) Cartilaginous surface fissured into 4 parts

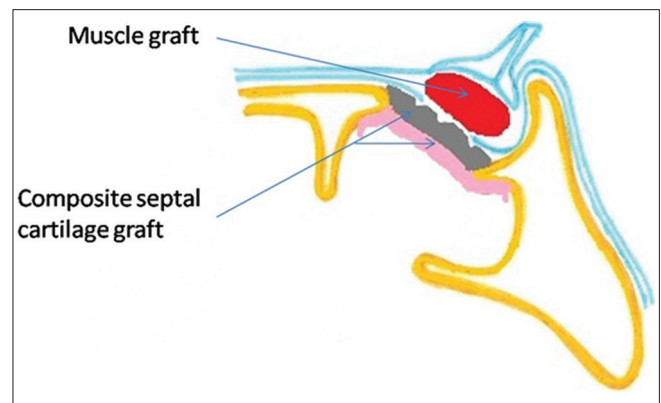
## Results

The study was conducted on 23 patients, twelve females (52.2%) and eleven males (47.8%) ranging in age from 19-65 years with a mean age of  $38 (\pm 13.67 \text{ STD})$  years.

With regard to the preoperative diagnosis, seven patients (30.4%) had non-functioning adenoma, 6 patients (26.1%) had growth hormone (GH) secreting adenoma, 5 patients (21.7%) had prolactin hormone secreting adenoma, 2 patients (8.7%) had adrenocorticotropic hormone (ACTH) secreting adenoma and 3 patients (13%) had non-functioning adenoma with apoplexy. The tumors were macroadenoma ( $\geq 1$  cm in diameter) in 21 patients (91.3%) and microadenoma ( $< 1$  cm in diameter) in 2 patients (8.7%). Seventeen patients (73.9%) were involved in group A, where the intraoperative CSF leakage was treated immediately by our technique (primary repair). While 6 patients (26.1%) were involved in group B, who had delayed treatment of their CSF leakage by our technique after failure of conservative treatment and external lumbar drain for more than three days (delayed repair). Four patients in group B had repair of the sellar floor with other techniques at the time of initial operation, that failed to prevent postoperative CSF rhinorrhea, two of them had repair with fat graft and gelfoam<sup>®</sup>, one of them had repair with fat graft and piece of nasal bone and one of them had repair with muscle graft, facia lata and surgiglu<sup>®</sup>. The other 2 patients in group B did not have any sellar repair at the time of initial operation.

CSF leak was of grade 1 in 6 patients (26.1%), grade 2 in ten patients (43.5%) and grade 3 in 7 patients (30.4%).

The patients were followed up for a period ranged from 12-48 months (mean  $24 \pm 10.47 \text{ STD}$  months). None of the patients in our study had postoperative CSF leak after the use of our technique for sellar repair during the follow up period. None of the patients developed treatment-related



**Figure 2:** Schematic description of our technique for sellar repair. The muscle graft is plugged into the intradural space. The composite septal cartilage graft acts as a double layer button to fit into the sellar defect. The bare cartilage is placed intrasellar facing the dura while the mucoperichondrium is placed extrasellar facing the sphenoid sinus.

complications after the operation either in the nasal site or the muscle donor site. During the first post-operative endoscopic follow-up, all patients demonstrated the presence of bloody crustations. The crusts were removed regularly and they disappeared gradually in the subsequent follow-up visits. Complete healing of the septum had occurred in all the patients without the formation of synechias or septal perforations. All the patients had well-developed mucosal covering of the sellar defect at the 2 month endoscopic follow-up visit. The patient population and case distribution are reported in Table 1.

## Discussion

Trans-sphenoidal surgery is the main operative approach for pituitary adenoma and postoperative CSF rhinorrhea is one of the most common and early surgical complication of this procedure.<sup>[1-5]</sup> If CSF leakage is found during trans-sphenoidal surgery, the best solution to prevent CSF rhinorrhea is complete sealing of the CSF leak during the initial surgery.<sup>[6]</sup>

No total agreement has been reached to the best technique for closing the CSF fistula and performing sellar floor reconstruction. Many reconstructive techniques have been proposed to prevent postoperative CSF leaks after traditional trans-sphenoidal surgery.

The aims and principles of repair remain the same to form a watertight dural seal and establish a barrier between the

sterile cranial cavity and the contaminated sino-nasal tract, thus decreasing the risk of ascending bacterial meningitis.<sup>[27]</sup>

Although a watertight dural suturing technique is optimal following trans-sphenoidal surgery, it is not always feasible. It seems even impossible to achieve a watertight repair of the defect because of limited space in the exposed sphenoid sinus, inability to define a specific site of leakage and even unavailability of identifiable dural borders.<sup>[28]</sup>

Classically, surgeons have used autologous materials such as abdominal fat, muscle, or fascia lata with or without support for the graft from nasal bone/nasal cartilage to prevent postoperative CSF rhinorrhea.<sup>[3,4,10,12,13]</sup>

Packing of the sella with an abdominal fat graft has been a relatively standard treatment for the management of intraoperative CSF leak during trans-sphenoidal surgery. Obliteration of the dead space in the sella and sphenoid sinus helps to prevent postoperative CSF fistula. However, the use of fat may introduce problems and complications.<sup>[22]</sup> Fat may interfere with the interpretation of the sellar content on postoperative MRI.<sup>[29]</sup> At 1 year postoperative, a considerable amount of non-resorbed fat may remain within the sella mixed with isointense non-enhancing tissue.<sup>[29]</sup> In addition, compression of the optic chiasm is a possibility and may require reoperation.<sup>[30]</sup> Another technical problem of autologous fat grafts is that inadequate packing, especially of large tissue

**Table 1: Patient population and case distribution**

Age (years)	Sex	Type of adenoma	Tumor size	Time of repair	Previous materials used	Grade of leak	Follow up (months)
59	Male	Non functioning	Macro	Delayed	Fat+gelfoam®	3	24
33	Female	GH secreting	Macro	Delayed	No	1	40
26	Female	GH secreting	Macro	Primary	No	2	37
35	Female	Apoplexy	Macro	Primary	No	1	15
24	Female	Prolactin secreting	Macro	Primary	No	2	18
42	Male	Non functioning	Macro	Delayed	Muscle+facia+surgiglu®	3	27
30	Female	Prolactin secreting	Macro	Primary	No	2	24
54	Male	Non functioning	Macro	Primary	No	2	20
29	Male	GH secreting	Macro	Delayed	Fat+bone	3	32
24	Female	GH secreting	Macro	Primary	No	2	35
37	Male	ACTH secreting	Micro	Primary	No	1	48
61	Female	Non functioning	Macro	Delayed	Fat+gelfoam®	3	18
26	Female	Prolactin secreting	Macro	Primary	No	2	24
19	Female	ACTH secreting	Micro	Primary	No	1	36
37	Male	Prolactin secreting	Macro	Primary	No	2	30
31	Male	GH secreting	Macro	Primary	No	2	30
34	Female	Non functioning	Macro	Primary	No	3	18
64	Male	Apoplexy	Macro	Delayed	No	1	12
35	Female	Apoplexy	Macro	Primary	No	3	14
65	Male	Non functioning	Macro	Primary	No	1	13
27	Female	Prolactin secreting	Macro	Primary	No	2	12
37	Male	GH secreting	Macro	Primary	No	3	12
45	Male	Non functioning	Macro	Primary	No	2	12

GH – Growth hormone, ACTH – Adrenocorticotropic hormone

graft, may aggravate the arachnoid tearing. When fat graft is inserted into the intrasellar space, the normal gland is pushed more posteriorly. Thus, the arachnoid tear and the gap between the normal gland and dura margin could be enlarged and postoperative CSF rhinorrhea might occur.<sup>[6]</sup>

Also in the single layer reconstructions using autologous tissue grafts, it was considered in many cases to insert postoperative external lumbar drain to decrease CSF pressure on the graft and keep the graft in place until healing of the arachnoid is achieved.<sup>[6,14]</sup>

Possible complications of external lumbar drain include meningitis, CSF overdrainage, or pneumocephalus. Complications secondary to mechanical failure of the catheter and insertion site infection are also possible. Risk of nerve root irritation has been documented to be as high as 5%. In addition, to prevent management complications, a very high level of familiarity by the nursing staff is required for the care of patients with postoperative external lumbar drain. As a result, patients may require ICU admission while an external lumbar drain is in place, thereby placing additional strain on resources and increasing the cost and overall length of stay for a patient compared to a patient who is cared for in a regular ward bed.<sup>[29,31]</sup>

Some authors advocated reconstruction of skull base defect after trans-sphenoidal surgery based on vascularized pedicle flaps.<sup>[7,11]</sup> They proposed that, the vascularity provided by the preserved pedicle allows rapid and effective integration with the surrounding tissues. The prolonged time required for tissue integration and risks of tissue resorption when using non-vascularised flaps can lead to a delayed postoperative CSF leak. However the disadvantages of the pedicled flaps are the limitation of covered areas due to the pedicles and the uncertainty of the size of the dural defect when they harvest the vascularized flap.<sup>[32]</sup>

Because of these problems, many authors have tried to obviate autologous tissue grafts. Various heterologous and synthetic materials have been proposed to repair CSF leaks, each one with some advantages and disadvantages.<sup>[6,14-25,33]</sup>

The use of hard materials for example ceramic plates,<sup>[15]</sup> pure titanium,<sup>[16]</sup> stainless steel plates,<sup>[17]</sup> silicone blocks,<sup>[18,19]</sup> and bone cement,<sup>[20]</sup> have been used for sellar reconstruction. Although these can be effective in preventing CSF leakage and form a strong sellar floor, they may not only be difficult to shape, but also may interfere with radiological studies, and these foreign bodies may cause a host-tissue reaction, serve as a nidus for infection, or be troublesome when repeated trans-sphenoidal surgery is necessary. Also their slow adhesion to surrounding tissue leads many surgeons to use postoperative external lumbar CSF drain to confirm sealing of the sellar floor, especially in patients with large CSF leakage.<sup>[17,25,34]</sup>

The newer resorbable materials, for example vicryl patches, gelatin foam, collagen sponges, oxidative cellulose, and fibrin glue, have yielded better results with less complications.<sup>[6,14,21-25,33]</sup> However, spinal drainage was required to prevent CSF leakage especially in cases with large tears. Also some authors reported danger of transmitting viral diseases or bovine spongiform encephalitis when human plasma or bovine collagen is used with these materials.<sup>[24,25]</sup> In addition, these heterologous and synthetic materials increase the total cost of the procedure and may not be available when arachnoid tear and CSF leak are encountered during the initial procedure.

Our technique of sellar repair for treatment of CSF leak after trans-sphenoidal excision of pituitary adenoma in this study was based on multi-layered autologous grafts consisting of intradural placement of muscle graft supplemented with extradural composite septal cartilage graft, composed of a piece of the posterior cartilaginous septum with its covering mucoperichondrium on one side only.

The intradural placement of the muscle graft was used to compress the arachnoid tear and allow sealing of the sub-arachnoidal space which represents the source from which the CSF comes out. In this way a first, valid, watertight barrier against CSF was realized. Muscle graft has advantage over fat graft in that, it is easy to manipulate and plug it into the intradural space thus decreasing the risk of optic chiasm compression or aggravating the dural tear.

The composite septal cartilage graft acted as a double layer button to fit into the sellar defect. The bare cartilage was placed intrasellar facing the dura to support the muscle graft and compress it against the arachnoid defect to promote its healing and to prevent downward displacement of the graft with the CSF pulsations. The mucoperichondrium was placed extrasellar facing the sphenoid sinus mucosa to adhere with it and with the roof of sphenoid sinus and allow physiological healing at the roof of sphenoid sinus to achieve complete sealing of the sellar defect. Also its attachment with the cartilage at the edge of sellar defect prevents upward and lateral displacement of the graft during cough or sneezing thus preventing failure of the graft or air to enter the cranium and cause tension pneumocephalus. Thus, the double layer button action of the composite septal cartilage graft resist pressure on both direction, from above by the high pulsatile force of CSF and from below by the positive pressure in the nasopharynx and the sphenoid sinus during cough or sneezing.

In comparison with the single-layer free autologous grafts our technique makes skull base reconstruction firmer even in high-output CSF leaks, thus maintains sealing of CSF fistula until healing of the arachnoid tear.

In comparison with the vascularized pedicle flaps our grafts are easy to harvest. Owing to the small size of the sellar defect it was not difficult at all to find a suitable composite septal cartilage in all cases even in revision cases. Also our graft is easy to manipulate and fit it into the sellar defect.

In comparison with the heterologous and synthetic materials, the autologous grafts that were used in our technique are always available, safe, and totally compatible, can resist infection and free of charge. The direct contact of the muscle graft with the arachnoid tear promotes its rapid healing. Also the direct contact of mucoperichondrium with the sphenoid mucosa and bone promotes physiological healing and complete selling at the sellar defect.

Most of the reports in literature especially that who used heterologous and synthetic materials for sellar reconstruction after trans-sphenoidal excision of pituitary adenoma described their results on prevention of postoperative CSF leakage when there was no leak during the initial surgery or when there was leak that treated immediately during the initial operation. However few reports described their results on management of delayed postoperative CSF rhinorrhea after trans-sphenoidal excision of pituitary adenoma.

Our study included twenty three patients and all of them had CSF leakage following trans-sphenoidal excision of pituitary adenoma. Seventeen patients had intraoperative CSF leakage after excision of the adenoma and were treated immediately by our technique at the time of initial operation (group A). While the other six patients had postoperative CSF rhinorrhea and had delayed treatment by our technique after failure of conservative measures and external lumbar CSF drainage for more than three days (group B). Four patients in group B had repair of the sellar floor with other techniques at the time of initial operation that failed to prevent postoperative CSF rhinorrhea, while the other two patients did not have any sellar repair at the time of initial operation. None of the patients in our study had postoperative CSF leak after the use of our technique for sellar repair during the follow up period (mean  $24 \pm 10.47$  STD months) either in group A or group B.

Many authors did not use external lumbar CSF drain with autologous grafts or other commercially available products for sellar reconstruction after trans-sphenoidal excision of pituitary adenoma if intraoperative CSF can no longer be detected despite an intraoperative Valsalva maneuver or jugular compression (grade 0) and if there is low-output CSF leak (grade 1 and 2). However they advocated the use of postoperative external CSF lumbar drain in the high output CSF leaks (grade 3).

In our study CSF leak was of grade 1 in 6 patients (26.1%), grade 2 in 10 patients (43.5%) and grade 3 in 7 patients (30.4%)

and all the patients were transferred to the ward after surgery without external CSF lumbar drain.

## Conclusion

Our technique of sellar repair by using autologous muscle and composite septal cartilage grafts is effective in treatment of intraoperative and delayed postoperative CSF leakage following trans-sphenoidal pituitary surgery without the use of postoperative external lumbar CSF drain even in the high output CSF leaks. These grafts have the advantages of being always available, easy to harvest and manipulate, safe, totally compatible, can resist infection, have rapid integration with the surrounding tissues and free of charge.

## References

1. Jane JA Jr, Laws ER Jr. The surgical management of pituitary adenomas in a series of 3,093 patients. *J Am Coll Surg* 2001;193:651-9.
2. Laws ER Jr, Thapar K. Surgical management of pituitary adenomas. *Baillieres Clin Endocrinol Metab* 1995;9:391-405.
3. Black PM, Zervas NT, Candia GL. Incidence and management of complications of transsphenoidal operation for pituitary adenomas. *Neurosurgery* 1987;20:920-4.
4. Ciric I, Ragin A, Baumgartner C, Pierce D. Complications of transsphenoidal surgery: Results of a national survey, review of the literature, and personal experience. *Neurosurgery* 1997;40:225-37.
5. Shiley SG, Limonadi F, Delashaw JB, Barnwell SL, Andersen PE, Hwang PH, *et al.* Incidence, etiology, and management of cerebrospinal fluid leaks following trans-sphenoidal surgery. *Laryngoscope* 2003;113:1283-8.
6. Cho JM, Ahn JY, Chang JH, Kim SH. Prevention of cerebrospinal fluid rhinorrhea after trans-sphenoidal surgery by collagen fleece coated with fibrin sealant without autologous tissue graft or postoperative lumbar drainage. *Neurosurgery* 2011;68 Suppl 1:130-7.
7. El-Sayed IH, Roediger FC, Goldberg AN, Parsa AT, McDermott MW. Endoscopic reconstruction of skull base defects with the nasal septal flap. *Skull Base* 2008;18:385-94.
8. Fortes FS, Carrau RL, Snyderman CH, Prevedello D, Vescan A, Mintz A, *et al.* The posterior pedicle inferior turbinate flap: A new vascularized flap for skull base reconstruction. *Laryngoscope* 2007;117:1329-32.
9. Hadad G, Bassagasteguy L, Carrau RL, Mataza JC, Kassam A, Snyderman CH, *et al.* A novel reconstructive technique after endoscopic expanded endonasal approaches: Vascular pedicle nasoseptal flap. *Laryngoscope* 2006;116:1882-6.
10. Hardy J. Transsphenoidal hypophysectomy. *J Neurosurg* 1971;34:582-94.
11. Kassam AB, Thomas A, Carrau RL, Snyderman CH, Vescan A, Prevedello D, *et al.* Endoscopic reconstruction of the cranial base using a pedicled nasoseptal flap. *Neurosurgery* 2008;63 (1 Suppl 1):44-52.
12. Spaziante R, de Divitiis E, Cappabianca P. Reconstruction of the pituitary fossa in transsphenoidal surgery: An experience of 140 cases. *Neurosurgery* 1985;17:453-8.
13. Wilson CB, Dempsey LC. Transsphenoidal microsurgical removal of 250 pituitary adenomas. *J Neurosurg* 1978;48:13-22.
14. Seiler RW, Mariani L. Sellar reconstruction with resorbable vicryl patches, gelatin foam, and fibrin glue in transsphenoidal surgery: A 10-year experience with 376 patients. *J Neurosurg* 2000;93:762-5.
15. Kobayashi S, Hara H, Okudera H, Takemae T, Sugita K. Usefulness of ceramic implants in neurosurgery. *Neurosurgery* 1987;21:751-5.
16. Arita K, Kurisu K, Tominaga A, Ikawa F, Iida K, Hama S, *et al.* Size-adjustable titanium plate for reconstruction of the sella turcica: Technical note. *J Neurosurg* 1999;91:1055-7.
17. Freidberg SR, Hybels RL, Bohigian RK. Closure of cerebrospinal fluid leakage after transsphenoidal surgery: Technical note. *Neurosurgery* 1994;35:159-60.

18. Kabuto M, Kubota T, Kobayashi H, Takeuchi H, Nakagawa T, Kitai R, *et al.* Long-term evaluation of reconstruction of the sellar floor with a silicone plate in transsphenoidal surgery. *J Neurosurg* 1998;88:949-53.
19. Kubota T, Hayashi M, Kabuto M, Takeuchi H, Fuji T, Ohhashi M, *et al.* Reconstruction of the skull base using a silicone plate during transsphenoidal surgery. *Surg Neurol* 1991;36:360-4.
20. Moliterno JA, Mubita LL, Huang C, Boockvar JA. High-viscosity polymethylmethacrylate cement for endoscopic anterior cranial base reconstruction. *J Neurosurg* 2010;113:1100-5.
21. Cappabianca P, Cavallo LM, de Divitiis E. Collagen sponge repair of small cerebrospinal fluid leaks obviates tissue grafts and cerebrospinal fluid diversion after pituitary surgery. *Neurosurgery* 2002;50:1173-4.
22. Cappabianca P, Cavallo LM, Valente V, Romano I, D'Enza AI, Esposito F, *et al.* Sellar repair with fibrin sealant and collagen fleece after endoscopic endonasal transsphenoidal surgery. *Surg Neurol* 2004;62:227-33.
23. Kaptain GJ, Vincent DA, Laws ER Jr. Cranial base reconstruction after transsphenoidal surgery with bioabsorbable implants. *Neurosurgery* 2001;48:232-4.
24. Kelly DF, Oskouian RJ, Fineman I. Collagen sponge repair of small cerebrospinal fluid leaks obviates tissue grafts and cerebrospinal fluid diversion after pituitary surgery. *Neurosurgery* 2001;49:885-90.
25. Yano S, Tsuiki H, Kudo M, Kai Y, Morioka M, Takeshima H, *et al.* Sellar repair with resorbable polyglactin acid sheet and fibrin glue in endoscopic endonasal transsphenoidal surgery. *Surg Neurol* 2007;67:59-64.
26. Esposito F, Dusick JR, Fatemi N, Kelly DF. Graded repair of cranial base defects and cerebrospinal fluid leaks in transsphenoidal surgery. *Neurosurgery* 2007;60 (4 Suppl 2):295-304.
27. Cavallo LM, Messina A, Esposito F, de Divitiis O, Dal Fabbro M, de Divitiis E, *et al.* Skull base reconstruction in the extended endoscopic transsphenoidal approach for suprasellar lesions. *J Neurosurg* 2007;107:713-20.
28. Chung SB, Nam DH, Park K, Kim JH, Kong DS. Injectable hydroxyapatite cement patch as an on-lay graft for the sellar reconstructions following endoscopic endonasal approach. *Acta Neurochir (Wien)* 2012;154:659-64.
29. Sade B, Mohr G, Frenkiel S. Management of intra-operative cerebrospinal fluid leak in transnasal transsphenoidal pituitary microsurgery: Use of post-operative lumbar drain and sellar reconstruction without fat packing. *Acta Neurochir (Wien)* 2006;148:13-19.
30. Slavin ML, Lam BL, Decker RE, Schatz NJ, Glaser JS, Reynolds MG. Chiasmal compression from fat packing after transsphenoidal resection of intrasellar tumor in two patients. *Am J Ophthalmol* 1993;115:368-71.
31. Açıkbaş SC, Akyüz M, Kazan S, Tuncer R. Complications of closed continuous lumbar drainage of cerebrospinal fluid. *Acta Neurochir (Wien)* 2002;144:475-80.
32. Pinheiro-Neto CD, Prevedello DM, Carrau RL, Snyderman CH, Mintz A, Gardner P, *et al.* Improving the design of the pedicled nasoseptal flap for skull base reconstruction: A radioanatomic study. *Laryngoscope* 2007;117:1560-9.
33. Burkett CJ, Patel S, Tabor MH, Padhya T, Vale FL. Polyethylene glycol (PEG) hydrogel dural sealant and collagen dural graft matrix in transsphenoidal pituitary surgery for prevention of postoperative cerebrospinal fluid leaks. *J Clin Neurosci* 2011;18:1513-7.
34. Couldwell WT, Kan P, Weiss MH. Simple Closure Following Transsphenoidal Surgery: Technical Note. *Neurosurg Focus* 2006;20:E11.

**How to cite this article:** El Shazly AA, El Wardany MA, Abo El Ezz TA. Sellar repair with autologous muscle and composite septal cartilage grafts for treatment of cerebrospinal fluid leakage following trans-sphenoidal pituitary surgery. *Asian J Neurosurg* 2016;11:433-9.

**Source of Support:** Nil, **Conflict of Interest:** None declared.