

## CASE REPORT

# Association of brain abscess with a mycotic aneurysm of the contralateral internal carotid artery in a patient of cyanotic heart disease

Sumit Bansal, Sachin A. Borkar, Ashok K. Mahapatra

Department of Neurosurgery, All India Institute of Medical Sciences, New Delhi, India

## ABSTRACT

Congenital cyanotic heart disease can lead to intra-cranial involvement. Authors report a very rare case of right intra-cerebral abscess diagnosed on computerized tomography (CT) scan and simultaneous presence of an aneurysm of the left internal carotid artery diagnosed on CT angiogram in a 15-year-old child with congenital cyanotic heart disease with recent onset left hemiparesis. Right cerebral abscess was tapped and left internal carotid aneurysm was planned to be followed up by giving antibiotics and serial angiograms, but he could not survive and died due to non-cranial cause. We conclude that cerebral angiography is necessary to diagnose cerebro-vascular complications, including infectious aneurysms, in cases presenting with unusual findings on neuroimaging study. Patient must undergo serial angiography while being on intravenous antibiotics. Intervention (either surgical or endovascular) should be considered if there are no signs of regression of size of aneurysm or in the presence of aneurysm rupture. We have not been able to find a similar case in the English literature.

**Key words:** Brain abscess, cyanotic heart disease, internal carotid aneurysm, mycotic aneurysm

## Introduction

Although septic emboli are thought to be a cause of metastatic brain abscess in patients of cyanotic heart disease, this has not been clearly proven by clinical studies. Molinari *et al.*<sup>[1]</sup> experimentally produced brain abscesses with infected emboli via a carotid cannula in dogs. It is very rare to encounter such a situation in the clinical setting.

To the best of the authors' knowledge, this is the first case report of simultaneous presence of brain abscess in a cerebral hemisphere with a mycotic aneurysm of the contralateral proximal internal carotid artery.

## Case Report

A 15-year-old boy with a known case of congenital cyanotic heart disease (Tetralogy of Fallot) was referred by a local

physician for evaluation of progressive lethargy, fever, aphasia, and left hemiparesis for a duration of one and a half months.

## Examination

Neurologically, the patient was febrile, lethargic, and aphasic, with a left hemiparesis (2/5, Medical Research Council grading). Contrast-enhanced computerized tomography (CECT) scan revealed a single lesion in the right cerebral hemisphere with midline shift along with a small hyper-dense lesion in the left internal carotid artery (ICA) region. The lesion was located in the right cerebral hemisphere predominantly in the centrum semiovale, internal capsule, and the watershed cortical areas. The radiological features were suggestive of brain abscess [Figure 1]. CT angiography was performed, which revealed an aneurysm of the left ICA [Figure 2]. On blood examination, his haemoglobin was found to be 21 g/dl and total leukocyte count was 14,700/mm<sup>3</sup>. Coagulation

### Access this article online

#### Quick Response Code:



#### Website:

www.asianjns.org

#### DOI:

10.4103/1793-5482.144171

This is an open access article distributed under the terms of the Creative Commons Attribution-NonCommercial-ShareAlike 3.0 License, which allows others to remix, tweak, and build upon the work non-commercially, as long as the author is credited and the new creations are licensed under the identical terms.

**For reprints contact:** reprints@medknow.com

### Address for correspondence:

Dr. Sachin A. Borkar, Department of Neurosurgery, Neurosciences Center, All India Institute of Medical Sciences, New Delhi - 110 029, India.  
E-mail: sachin.aiims@gmail.com

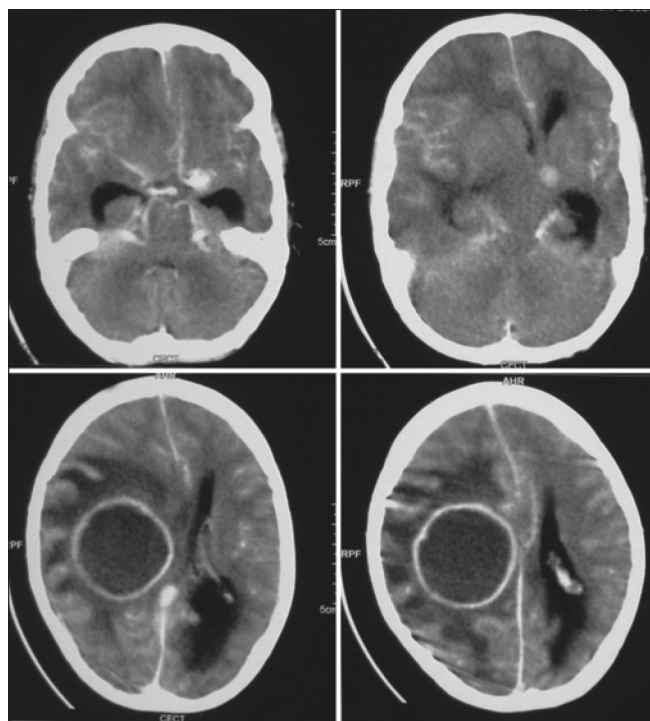
**How to cite this article:** Bansal S, Borkar SA, Mahapatra AK. Association of brain abscess with a mycotic aneurysm of the contralateral internal carotid artery in a patient of cyanotic heart disease. Asian J Neurosurg 2017;12:220-3.

parameters were within normal limits. Blood culture was sterile at the time of admission and echocardiography showed no evidence of endocarditis. The aneurysm was presumed to be mycotic on clinical and neuroimaging features.<sup>[2]</sup>

### Course

After admission, burr hole and tapping of right parietal abscess were performed. About 100 ml of thick pus was aspirated. Pus culture was positive for methicillin-sensitive *Staphylococcus aureus*. The patient received appropriate antibiotics. Follow-up CT scan performed during stay in hospital revealed a small residual abscess, which was tapped after 1 week, through the same burr hole and around 40 ml of thick pus was aspirated. Patient's power improved to 4/5 (Medical Research Council grading), with antibiotics to be continued for a minimum of 6 weeks. CECT of head performed just before discharge revealed a resolution of abscess [Figure 3]. The patient was advised to take antibiotics for 6 weeks and was discharged on post-operative day 10 with a plan for angiogram check after 6 weeks.

The patient was well for 1 month after discharge from hospital when he suddenly deteriorated and expired in a local hospital. CT of head performed at that time in a peripheral hospital did not reveal any evidence of sub-arachnoid haemorrhage, any other kind of intra-cranial mass lesion or infarct. Due to simultaneous presence of cyanotic congenital heart disease, the cause of death was presumed to be cardiac in origin in the absence of intra-cranial cause of sudden death.



**Figure 1:** CECT scans obtained on admission showing a large abscess in the right cerebral hemisphere with peri-lesional oedema and midline shift. A hyper-dense lesion in left ICA region can also be seen

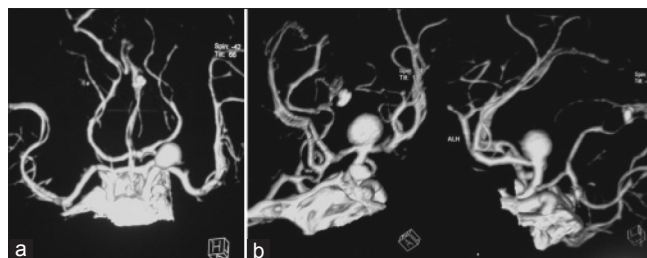
### Discussion

Mycotic aneurysms are a rare cause of intra-cranial aneurysms that develop in the presence of infections such as infective endocarditis.<sup>[3]</sup> They account for 0.7%-6.5% of all intra-cranial aneurysms<sup>[2]</sup> and are associated with significant morbidity and mortality, as high as 60%-90% in earlier case studies, and 12%-32% in more recent literature reviews.<sup>[3,4]</sup> Most often they are located on the distal branches of the middle cerebral artery, and are multiple and bilateral.<sup>[5-8]</sup> Metastatic abscesses in the brain account for about 30% of all brain abscesses.<sup>[9]</sup> A survey of previously reported cases of metastatic brain abscesses has disclosed no cases of brain abscess associated with mycotic aneurysm of the internal carotid artery except occasional reported cases of multiple brain abscesses with a mycotic aneurysm of the left common carotid artery,<sup>[10]</sup> ascending aorta,<sup>[11]</sup> and middle and anterior cerebral arteries.<sup>[12]</sup>

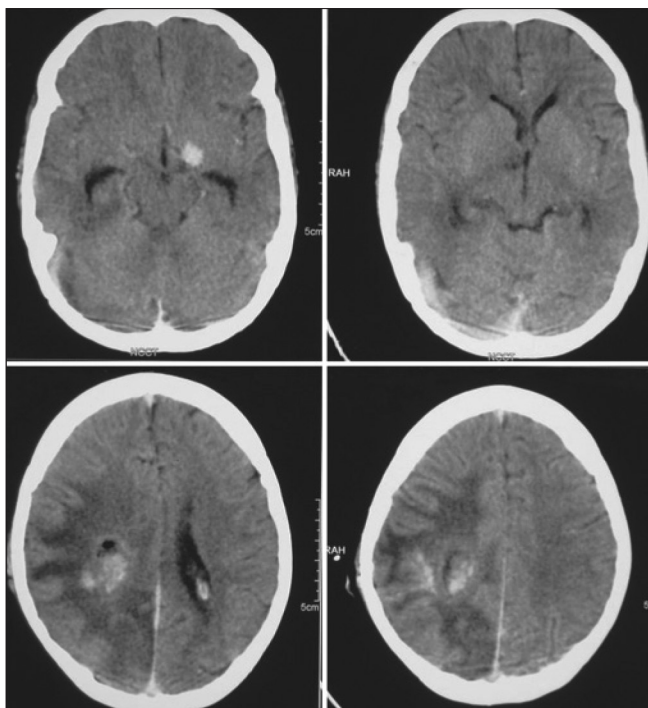
The mechanism of metastasis, by and large, is presumed to be by septic emboli,<sup>[1,13-15]</sup> but this can rarely be proven from clinical studies.<sup>[1,14]</sup> From experimental studies, the evolution of brain abscess is said to require at least the co-existence of a bacterial infection and a focus of ischemic or necrotic tissue.<sup>[1,15]</sup>

In our case, specifically, the abscess was situated in the following areas: The centrum semiovale, the internal capsule, and the anterior and posterior watershed cortical areas. These areas are less well vascularised, with relatively little collateral circulation. The infected emboli could have been delivered to other areas, but the brain abscesses developed only in these poorly vascularised areas.<sup>[10]</sup> This case, therefore, may support the above experimental hypothesis concerning the pathogenesis of metastatic brain abscesses.

The proposed diagnostic criteria for infectious aneurysm by Kanno *et al.*<sup>[2]</sup> contain a mandatory criterion (demonstration of intra-cranial aneurysm by neuroimaging) and 12 supportive criteria drawn from three domains. Domain A encompasses infection such as infective endocarditis, meningitis, cavernous sinus thrombophlebitis, or orbital cellulitis. Domain B encompasses angiographic features of the aneurysm, such as multiplicity, distal location, fusiform shape, and change in size or appearance of new aneurysm at follow-up angiogram. Domain C encompasses other features, such as



**Figure 2:** (a and b) A CT angiogram demonstrating a saccular aneurysm of the left proximal internal carotid artery with no evidence of aneurysm on the right side



**Figure 3:** CECT scans obtained just before discharge showing resolution of abscess with no shift of midline structures. A hyper-dense lesion is still persisting in the left ICA region in this scan

age <45 years, recent history of fever, lumbar puncture, or cerebral haemorrhage. Diagnosis would be clinically compelling if three or more of the proposed supportive criteria are satisfied, or clinically probable if two proposed supportive criteria are satisfied apart from the mandatory criteria. In our case, the criteria fulfilled were demonstration of aneurysm on neuroimaging, source of infection in the form of cyanotic congenital heart disease with fever, and brain abscess in a young patient (15 years of age).

Given the relative rarity of this disease, current recommendations regarding management of infective intra-cranial aneurysms have been divided into medical, endovascular, and surgical treatment. The medical intervention that is uniformly recommended is long-term intravenous antibiotic therapy for at least 6 weeks.<sup>[16]</sup>

Morawetz and Karp<sup>[16]</sup> observed that unruptured mycotic aneurysms could undergo spontaneous thrombosis, suggesting that mycotic aneurysms could resolve completely with antibiotic therapy alone. In a review of 20 cases of mycotic aneurysms over a 10-year period by Chun *et al.*,<sup>[17]</sup> seven patients were initially treated conservatively with intravenous antibiotics alone and followed by serial angiography. In this series, the aneurysms in two patients decreased in size, one did not change, two achieved successful thrombosis, and the remaining two enlarged. Based on this review, the conclusion regarding unruptured mycotic aneurysms is that medical management with 6 weeks of intravenous antibiotic therapy is reasonable if closely followed by serial angiography. The goal

of serial angiography would be to demonstrate improvement in aneurysm size and resolution. Zhao *et al.*<sup>[18]</sup> reported a case in which a mycotic aneurysm failed to show radiographic decrease in size after 2 weeks of medical therapy, and was successfully treated with endovascular therapy.

Recently, a comprehensive review by Ducruet *et al.*,<sup>[19]</sup> of 27 clinical series and 287 patients with intra-cranial mycotic aneurysms diagnosed between 1950 and 2009, concluded that in all treatment modalities combined, 62% of patients had a positive outcome, 20% faced further neurological decline, 5% died before an invasive intervention could be performed, and 12% died immediately after an intervention was performed whether surgical or endovascular.

From the above observations, we conclude that cerebral angiography is necessary to diagnose cerebro-vascular complications, including infectious aneurysms, in cases presenting with unusual findings on neuroimaging study. Patient must undergo serial angiography while being on intravenous antibiotics. Intervention (either surgical or endovascular) should be considered if there are no signs of regression of size of aneurysm or in the presence of aneurysm rupture. Co-existing congenital cyanotic heart disease should be managed in consultation with a cardiology team.

### Financial support and sponsorship

Nil.

### Conflicts of interest

There are no conflicts of interest.

### References

1. Molinari GF, Smith L, Goldstein MN, Satran R. Brain abscess from septic cerebral embolism: An experimental model. *Neurology* 1973;23:1205-10.
2. Kanno S, Thomas SV, Nair S, Sarma PS. Proposed diagnostic criteria for intracranial infectious aneurysms. *J Neurol Neurosurg Psychiatry* 2008;79:943-6.
3. Kanno S, Thomas SV. Intracranial microbial aneurysm (infectious aneurysm): Current options for diagnosis and management. *Neurocrit Care* 2009;11:120-9.
4. Watanabe A, Hirano K, Ishii R. Cerebral mycotic aneurysm treated with endovascular occlusion: Case report. *Neurol Med Chir* 1998;38:657-60.
5. Hart RG, Kagan-Hallet K, Joerns SE. Mechanisms of intracranial haemorrhage in infective endocarditis. *Stroke* 1987;18:1048-56.
6. Roach MR, Drake CG. Ruptured cerebral aneurysms caused by microorganisms. *N Engl J Med* 1965;273:240-4.
7. Pruitt AA, Rubin RH, Karchmeier AW, Duncan GW. Neurologic complications of bacterial endocarditis. *Medicine* 1978;57:329-43.
8. Salgado AV, Furlan AJ, Keys TF. Mycotic aneurysms, subarachnoid haemorrhage and indications for cerebral angiography in infective endocarditis. *Stroke* 1987;18:1057-60.
9. Ettinger MG. Brain abscess. In: Baker AB, Baker LH, editors. *Clinical Neurology*. Vol. 2. Philadelphia: Harper and Row; 1982. p. 1-35.
10. Imamura J, Watanabe Y. Multiple brain abscesses associated with a mycotic aneurysm of the left common carotid artery. *J Neurosurg* 1986;64:325-7.
11. Pocar M, Moneta A, Pelenghi S, Donatelli F, Tresoldi F, Scomazzoni F, *et al.* Mycotic aortic aneurysm presenting as multiple cerebral abscesses. *Acta Neurochir (Wien)* 1998;140:289-90.

12. Murakami K, Takahashi N, Matumura N, Umezawa K, Midorikawa H, Kaimori M, *et al.* A case presenting brain abscess with multiple infectious aneurysms. *No Shinkei Geka* 2002;30:1089-94.
13. Berg B, Franklin G, Cuneo R, Boldrey E, Strimling B. Nonsurgical cure of brain abscess: Early diagnosis and follow-up with computerized tomography. *Ann Neurol* 1978;3:474-8.
14. Kitamura K, Kagawa M. Abscess of the brain. *No Shinkei Geka* 1974;2:355-64.
15. Wood JH, Lightfoote II, WE, Ommaya AK. Cerebral abscesses produced by bacterial implantation and septic embolisation in primates. *J Neurol Neurosurg Psychiatry* 1979;42:63-9.
16. Morawetz RB, Karp RB. Evolution and resolution of intracranial bacterial (mycotic) aneurysms. *Neurosurgery* 1984;15:43-9.
17. Chun JY, Smith W, Halbach VV, Higashida RT, Wilson CB, Lawton MT. Current multimodality management of infectious intracranial aneurysms. *Neurosurgery* 2001;48:1203-13; discussion 1213-4
18. Zhao PC, Li J, He M, You C. Infectious intracranial aneurysm: Endovascular treatment with onyx case report and review of the literature. *Neurol India* 2010;58:131-4.
19. Ducruet AF, Hickman ZL, Zacharia BE, Narula R, Grobelny BT, Gorski J, *et al.* Intracranial infectious aneurysms: A comprehensive review. *Neurosurg Rev* 2010;33:37-46.