

CASE REPORT

Distal posterior cerebral artery revascularization for a fusiform PCA aneurysm: A lesson learned

Gavin W. Britz, Ali Zomorodi¹, Ciaran J. Powers²

Department of Neurosurgery, Houston Methodist Hospital, Houston, TX, ²Wexner Medical Center, The Ohio State University, Columbus, OH, ¹Department of Surgery, Division of Neurosurgery, Duke University Medical Center, Durham, NC, USA

ABSTRACT

The need for revascularization with proximal posterior cerebral artery occlusion in the treatment of giant and fusiform aneurysms is unclear. While early series demonstrated only about a 10% chance of infarction following posterior cerebral artery occlusion, recently several authors have advocated a bypass prior to parent vessel sacrifice in all cases. We present the case of an adult man with a fusiform aneurysm of the right posterior cerebral artery at the P2-P3 junction. He clinically failed a balloon test occlusion preoperatively and therefore underwent an occipital artery to distal posterior cerebral artery bypass with subsequent endovascular occlusion of the parent vessel and aneurysm. Despite the fact that the immediate and 6 month follow up cerebral angiography confirmed a patent bypass, the patient still developed a posterior cerebral artery territory stroke. We believe this case demonstrates that successful distal revascularization in the setting of proximal posterior cerebral artery occlusion does not guarantee against cerebral ischemia and infarction even in those patients that fail a test occlusion.

Key words: Cerebral aneurysms, revascularization, stroke

Introduction

Aneurysms of distal posterior cerebral artery (PCA) can be treated by proximal PCA occlusion with a low risk of neurologic deficit.^[1] However, sometimes revascularization is necessary in attempts to prevent stroke.^[2-4] We report the case of a patient with a distal fusiform right PCA aneurysm who presented with an ischemic stroke. After failing balloon test occlusion, he underwent successful occipital artery to distal PCA bypass followed by endovascular P2 occlusion. Although the bypass remained patent on immediate and delayed angiography, the patient nevertheless suffered a right PCA territory stroke and developed a left visual field deficit. We believe this case demonstrates that distal revascularization in the setting of proximal posterior cerebral artery occlusion does not guarantee against cerebral

ischemia and infarction. Patients and surgeons should be aware of this possibility.

Case Report

The patient is an adult man who presented to our institution after developing the acute onset of transient left-sided body numbness while lifting weights. His past medical history was remarkable only for a closed head injury with facial and skull fractures following a bull-riding accident ten years before. Computed tomography (CT) of the head revealed a hyperdensity in the right ambient cistern [Figure 1a] and CT angiography revealed a 12 mm fusiform right PCA aneurysm [Figure 1b]. Lumbar puncture revealed no evidence of subarachnoid hemorrhage. Cerebral catheter angiography demonstrated a partially thrombosed 12 mm by 9 mm right P2-P3 junction aneurysm as well as a suitable right occipital artery. [Figure 2a and b] Balloon test occlusion of the right PCA just proximal to the aneurysm resulted in an immediate field cut as well as nausea.

This is an open access article distributed under the terms of the Creative Commons Attribution-NonCommercial-ShareAlike 3.0 License, which allows others to remix, tweak, and build upon the work non-commercially, as long as the author is credited and the new creations are licensed under the identical terms.

For reprints contact: reprints@medknow.com

How to cite this article: Britz GW, Zomorodi A, Powers CJ. Distal posterior cerebral artery revascularization for a fusiform PCA aneurysm: A lesson learned. Asian J Neurosurg 2017;12:273-5.

Access this article online	
Quick Response Code:	Website: www.asianjns.org
	DOI: 10.4103/1793-5482.144186

Address for correspondence:

Dr. Gavin W. Britz, Department of Neurosurgery, Houston Methodist Hospital, 6560 Fannin St. Suite 944, Houston, TX, 77030. USA.
E-mail: gbritz@houstonmethodist.org

Given the result of the balloon test occlusion, the patient was started on oral aspirin and then taken to the operating room for right occipital artery to right parieto-occipital artery bypass. The recipient vessel was noted to be very small (approximately 0.8 mm in size), but Doppler ultrasonography confirmed patent flow following the anastomosis. After careful attention to hemostasis during closure, the patient was taken to the endovascular suite. The patient was fully heparinized after cerebral catheter angiography confirmed a patent bypass and consequently the fusiform aneurysm and parent vessel were occluded with detachable coils [Figure 3a and b]. He remained on therapeutic heparin for 24 hours after the occlusion.

Immediately postoperatively the patient was doing well, but on the second postoperative day he developed a left drift and progressive somnolence. A CT of the head revealed a delayed right PCA distribution infarct [Figure 4]. After recovering with the assistance of physical and occupational therapies, the patient was discharged to an acute rehabilitation facility.

He was seen in clinic at 2 weeks and 6 months. He had a left visual field deficit, but was otherwise neurologically normal and was fully independent with activities of daily living. A repeat cerebral catheter angiogram was performed at 6 months that showed the occipital artery to distal PCA bypass was still patent [Figure 5].

Discussion

There is controversy regarding the need for revascularization following proximal PCA occlusion in the treatment of giant

or fusiform aneurysms.^[5] In his treatment of 47 patients with giant or fusiform distal PCA aneurysms treated with proximal occlusion, Drake had only five who developed postoperative visual field defects.^[6,7] Drake ascribed this low rate of infarct following PCA occlusion (10.6%) due to the robust collaterals from the anterior and middle cerebral arteries.

However, several groups have advocated revascularization prior to PCA occlusion for the treatment of giant or fusiform distal PCA aneurysms with the goal being to minimize the risk of PCA stroke.^[2,4,6] Chang *et al.* described four patients with PCA aneurysms who were treated with proximal occlusion.^[2] Two were also treated with revascularization to minimize the risk of stroke. One of the two who were not revascularized suffered a severely disabling stroke, while the other three patients had excellent outcomes. Chang *et al.* concluded that PCA revascularization should be attempted when the proximal PCA is occluded.^[2]

Lawton *et al.* have argued in favor of revascularization in all patients with aneurysms treated by parent artery occlusion.^[3] In their review of 61 patients with 63 aneurysms, 93% had good outcomes and there was only one mortality. Since the risk of stroke after carotid artery occlusion may be as high as 22%, even in patients that pass balloon test occlusion, the authors argued that the risk of neurologic complications

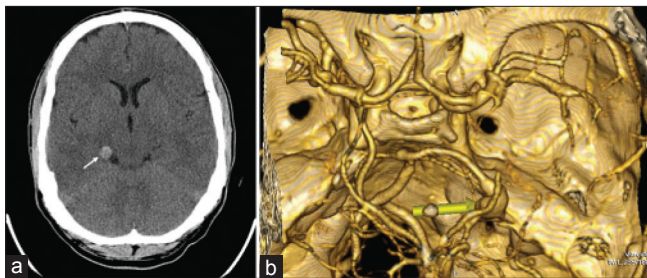


Figure 1: (a) Non-contrast head CT showing hyperdensity in right ambient cistern (arrow); (b) CT angiogram reconstruction showing fusiform right PCA aneurysm (arrow)

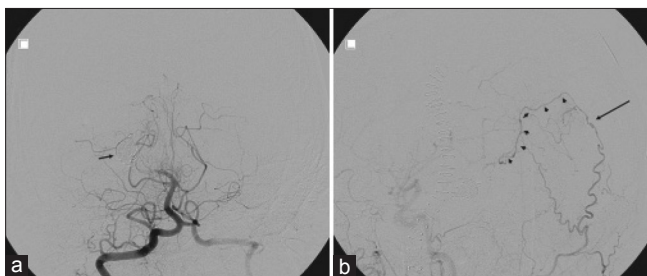


Figure 3: (a) Postoperative Towne's view right VA angiogram showing obliteration of right PCA aneurysm (arrow); (b) Postoperative lateral view right external carotid artery angiogram showing patent bypass (arrow) with filling of distal PCA (arrowheads)

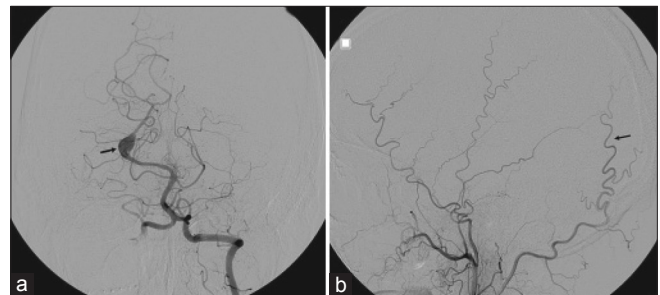


Figure 2: (a) Towne's view left VA angiogram showing right PCA aneurysm (arrow); (b) Lateral view right ECA angiogram showing suitable occipital artery for planned bypass (arrow)

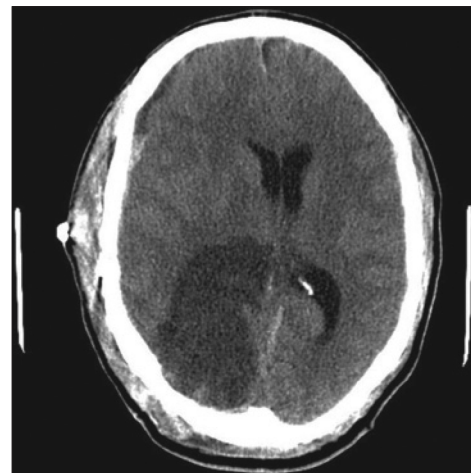


Figure 4: Non-contrast head CT showing large right occipital hypodensity consistent with PCA territory stroke

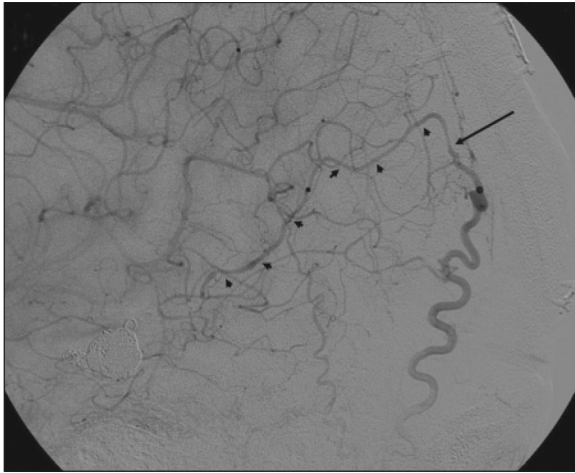


Figure 5: Six month postoperative lateral view right external carotid angiogram showing matured patent bypass (arrow) with filling of distal PCA (arrowheads)

following revascularization is lower than the risk of parent artery occlusion alone.^[3] Of note, there were no patients with PCA aneurysms in this study.

More recently, Vishteh *et al.* have also advocated PCA revascularization prior to PCA occlusion for the treatment of giant or fusiform PCA aneurysms.^[4] They described two patients with distal PCA aneurysms who were treated with distal bypass prior to proximal occlusion. These bypasses were to distal PCA branches, avoiding the complications associated with more proximal PCA bypasses, particularly the complications related to temporal lobe retraction and need to do the distal anastomosis in a deep field. Both of these patients had full visual fields when examined in follow up. Vishteh *et al.* concluded that distal revascularization with proximal occlusion carries less risk than proximal occlusion alone.^[4]

We agree that peripheral revascularization should be attempted if there is evidence that proximal PCA occlusion will be symptomatic. This was evident in the case presented here, insofar as the patient became acutely symptomatic with balloon test occlusion. Although we were confident with the patency of our bypass intraoperatively (and immediate postoperative angiography confirmed this), nevertheless we were thwarted in our goal of preventing a stroke. Although it is possible that the patient's stroke was the result of a thromboembolic event, we do not think this is likely given that, in addition to maintaining therapeutic heparinization during the procedure and postoperatively, he was also maintained on antiplatelet therapy with aspirin. We believe his stroke was the result of inadequate blood flow due to the small donor and recipient

vessel which is often the case in distal revascularization.

The "lesson learned" in this case is that even with an angiographically patent bypass, adequate revascularization may not be achieved. Each patient has their own amount of collateral circulation that is unknown and in selected cases, the distal PCA branches such as the parieto-occipital artery may simply not be an adequate recipient vessels for an extracranial-intracranial bypass to prevent a stroke.

Conclusion

We have presented the case of a PCA stroke resulting from proximal PCA occlusion in spite of a patent occipital artery to distal PCA bypass. While as many as 90% of patients may tolerate proximal PCA occlusion, those that fail balloon test occlusion are very likely to fall into the other 10%. We agree that attempted revascularization is appropriate for these patients. However, in distal PCA revascularization both the donor and recipient vessel may be of too small a caliber to be a sufficient conduit to supply adequate blood supply back to the larger and more proximal PCA segments in patients with very poor collateral circulation.

Financial support and sponsorship

Nil.

Conflicts of interest

There are no conflicts of interest.

References

1. Drake CG. Giant posterior cerebral aneurysms: 66 patients. In: Drake CG, Peerless SJ, Hernesniemi JA, editors. *Surgery of Vertebrobasilar Aneurysms*: London, Ontario, Experience on 1,767 Patients. New York: Springer-Verlag; 1996. p. 230-48.
2. Chang HS, Fukushima T, Takakura K, Shimizu T. Aneurysms of the posterior cerebral artery: Report on ten cases. *Neurosurgery* 1986;19:1006-11.
3. Lawton MT, Hamilton MG, Morcos JJ, Spetzler RF. Revascularization and aneurysm surgery: Current techniques, indications, and outcome. *Neurosurgery* 1996;38:83-94.
4. Vishteh AG, Smith KA, McDougall CG, Spetzler RF. Distal posterior cerebral artery revascularization in multimodality management of complex peripheral posterior cerebral artery aneurysms: Technical case report. *Neurosurgery* 1998;43:166-70.
5. Bendok BR, Ali MJ, Getch CC, Gottardi-Littell NR, Mindea S, Batjer HH. Basilar apex and posterior cerebral artery aneurysms. In: Winn RH, editor. *Youman's Neurological Surgery*. Vol 2. Philadelphia: Saunders; 2004. p. 2041-55.
6. Korinth MC, Thron A, Bertalanffy H, Gilsbach JM. Coil embolization of an incidental posterior cerebral artery aneurysm after initial OA-PCA bypass surgery. *Zentralbl Neurochir* 2000;61:158-61.
7. Peerless SJ, Hernesniemi JA, Drake CG. Posterior circulation aneurysms. In: Wilkins RH, Rengachary SS, editors. *Neurosurgery*. Vol 2. New York: McGraw-Hill; 1996. p. 2341-56.