

Localized reversible high signal intensities on diffusion-weighted MRI in hypoglycemia: A study of 70 cases

Masahito Katoh, Masami Yoshino, Takeshi Aoki, Takeo Abumiya, Hiroyuki Imamura, Toshimitsu Aida
 Department of Neurosurgery, Hokkaido Neurosurgical Memorial Hospital, Sapporo, Japan

ABSTRACT

Introduction: It is well-known that localized reversible high signal intensities in the splenium of the corpus callosum or the basal ganglia appear on diffusion-weighted MRI in the presence of hypoglycemia. The aim of this study was to clarify the incidence and significance of such high signal intensity lesions.

Results: We analyzed 70 cases of hypoglycemia with consciousness disturbance referred to our outpatient office. Localized reversible high signal intensities on diffusion-weighted MRI were noted in 6 cases (8.6%). They were at the splenium of the corpus callosum in four cases (5.7%), and right frontal cortex and bilateral frontal white matter in one each. Convulsions were noted in five cases, and right hemiparesis was noted in three. None of the three cases of hemiparesis showed localized reversible high signal intensities on diffusion-weighted MRI. These lesions are reversible if the patients undergo treatment without delay.

Conclusion: The significance of these lesions is still unclear. However, when a high signal intensity lesion that is not reasonable for the symptom is detected on diffusion-weighted MRI, an immediate check of the blood sugar level is mandatory.

Key words: Hypoglycemia, localized reversible high signal intensity, splenium of the corpus callosum

Introduction

It is well-known that localized reversible high signal intensities in the splenium of the corpus callosum^[1] or the basal ganglia^[2-4] appear on diffusion-weighted magnetic resonance imaging (MRI) in the presence of hypoglycemia.

The aim of this study was to clarify the incidence and significance of such high signal intensity lesions. We analyzed 70 cases of hypoglycemia with consciousness disturbance referred to our outpatient office.

Patients and Methods

The present series consisted of 70 cases (65 patients) with the hypoglycemia with consciousness disturbance referred

to the Hokkaido Neurosurgical Memorial Hospital from June 4, 2005 to September 17, 2011. All patients underwent MRI on arrival. Other studies included the blood sugar level, hemoglobin A1c, medical history of diabetes mellitus, and hemiparesis. A dextrostix method (CareFast[®]; NIPRO) was used to check the blood sugar level in the emergency room for initial treatment consideration. The blood sugar levels were examined on arrival and after recovery from consciousness disturbance. Some patients refused to undergo other examinations after consciousness disturbance recovery.

Results

Of the 70 cases, the mean age was 72.54 years, and 36 cases were females. The mean age of male patients was 67.50 years, and that of female patients was 77.31 years. The blood sugar levels were measured on arrival in 65 cases; dextrostix showed “low” in five cases. The mean blood sugar level on arrival was 33.23 mg/dl (range, 0-68). As soon as hypoglycemia was noted, glucose was administered. After recovery from consciousness disturbance, the blood sugar levels were examined in 58 cases, and the mean level was 137.00 mg/dl (range, 46-376).

Sixty-two patients were under treatment for diabetes mellitus; 36 received oral hypoglycemic agents, 23 received insulin, and the treatments of three were unknown. One case whose blood sugar level on arrival was 0 mg/dl took a large amount of oral

Access this article online	
Quick Response Code:	Website: www.asianjns.org
	DOI: 10.4103/1793-5482.144196

Address for correspondence:

Dr. Masahito Katoh, Hokkaido Neurosurgical Memorial Hospital,
 Hachiken 9 Higashi 5, Nishi-Ku, Sapporo, Japan.
 E-mail: masasama@ceres.ocn.ne.jp

hypoglycemic agents to commit suicide. One case was under dialysis. Hemoglobin A1c was examined in 46 cases; the mean was 5.6% (range, 4.3-7.5).

Convulsions were noted in five cases, and right hemiparesis was noted in three.

Localized reversible high signal intensities on diffusion-weighted MRI were noted in six cases (8.6%) [Table 1, Figures 1-6]. They were at the splenium of the corpus callosum in four cases (5.7%), and right frontal cortex and bilateral frontal white matter in one each. None of the three cases of

hemiparesis showed localized reversible high signal intensities on diffusion-weighted MRI.

Discussions

Patients who present with consciousness disturbance and are brought to the emergency department by ambulance include those with hypoglycemia. Some hypoglycemic patients with consciousness disturbance present with hemiparesis or convulsion; therefore, it is not always easy to differentiate

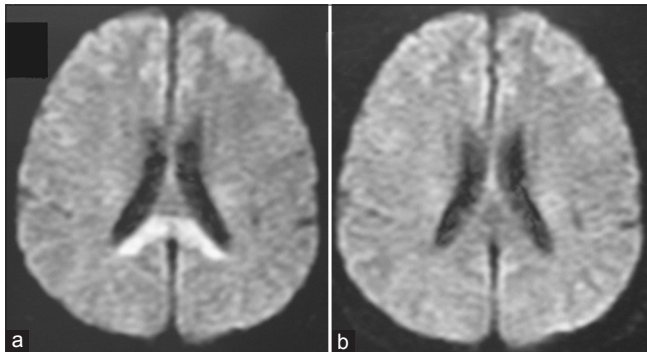


Figure 1: (a) Boomerang-shaped high signal intensity was detected in the splenium of the corpus callosum on diffusion-weighted MRI (b) The lesion had disappeared on MRI on the next day with the recovery from hypoglycemia

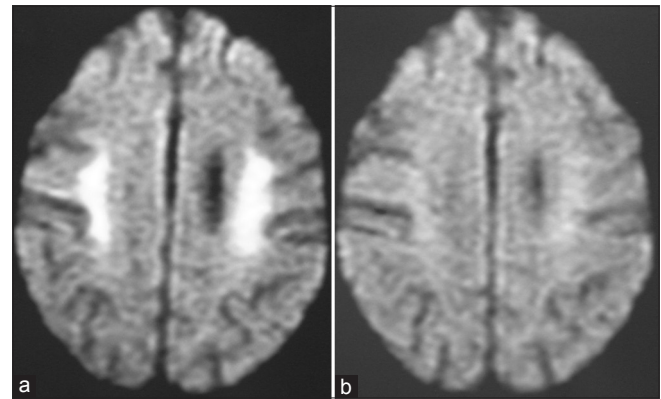


Figure 2: (a) High signal intensity was detected in bilateral frontal white matter on diffusion-weighted MRI (b) The lesion had disappeared on MRI on the next day with the recovery from hypoglycemia

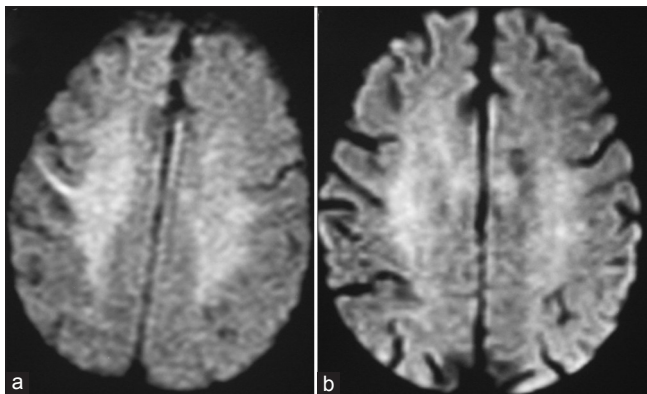


Figure 3: (a) High signal intensity was detected in right frontal cortex on diffusion-weighted MRI (b) The lesion had disappeared on MRI on the next day with the recovery from hypoglycemia

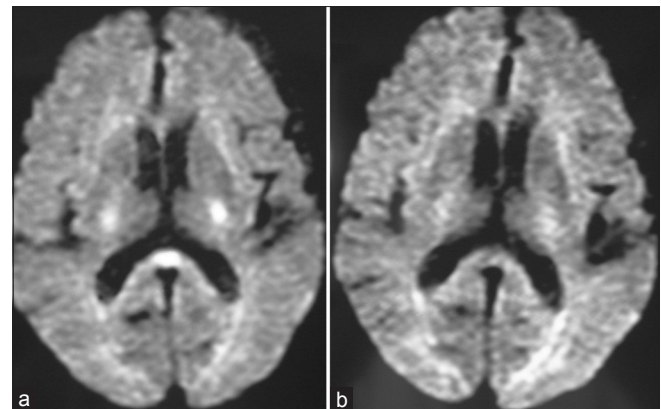


Figure 4: (a) Oval-shaped high signal intensity was detected in the splenium of the corpus callosum on diffusion-weighted MRI (b) The lesion had disappeared on MRI on the next day with the recovery from hypoglycemia

Table 1: Summary of patient characteristics that showed localized reversible high signal intensities on diffusion-weighted MRI

Case	Age	Sex	BS1	BS2	Consciousness	Location	DM	Treatment	Hb-A1c %
2	45	M	35	130	E4V3M5=12	Splenium	(+)	Insulin	6.7
11	81	F	30	144	E1V1M4=6	White matter	(+)	Oral	5.9
14	86	M	45	164	E4V4M6=14	Cortex	(+)	Oral	5.4
23	86	F	43	89	E4V1M5=10	Splenium	(+)	Oral	6.3
27	82	M	68		E4V4M6=14	Splenium	(+)	Oral	6.5
28	79	F	26	91	E1V1M1=3	Splenium	(-)		4.6

BS1 - The blood sugar levels on arrival, BS2 - The blood sugar levels after treatment; MRI - Magnetic resonance imaging

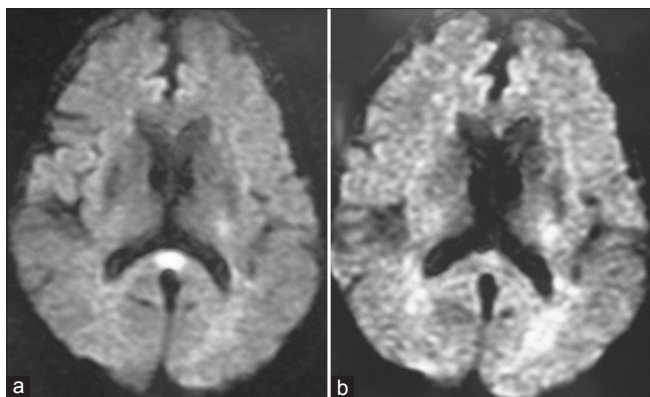


Figure 5: (a) Oval-shaped high signal intensity was detected in the splenium of the corpus callosum on diffusion-weighted MRI (b) The lesion had disappeared on MRI on the next day with the recovery from hypoglycemia

them from stroke or brain tumor patients in the emergency room. Malouf and Brust reported^[5] that 2.4% of hypoglycemic patients presented with hemiparesis.

Normalization of the blood sugar level should be realized as soon as possible in the presence of hypoglycemia. A delay in treatment may lead to irreversible brain injury and prolonged consciousness disturbance.^[6,7] The lesions on MRI and consciousness disturbance of all cases in the present study were reversible. All patients recovered from hypoglycemia.

There have been many reports of a localized reversible high signal intensity at the splenium of the corpus callosum on diffusion-weighted MRI in hypoglycemia since the report of Böttcher *et al.*^[8] in 2005. Hypoglycemia is not the only condition that presents such reversible high signal intensity, as it has been described in patients with encephalitis, epileptic seizure, and metabolic disturbance.^[9-11] However, when such a high signal intensity lesion is detected on MRI, it is important to check the blood sugar level promptly. If hypoglycemia is revealed, immediate recovery is crucial.

It is widely assumed that severe hypoglycemia causes cerebral energy failure and leads to a reduction of cell membrane ionic pump activity and a consecutive shift of cerebral water from extra- to intracellular spaces;^[8] therefore, the apparent diffusion coefficient (ADC) reduces and a high signal intensity change will be detected on diffusion-weighted images. The reason why a lack of energy for the whole brain leads to localized ADC reduction is still unclear. Hasegawa *et al.*^[12] speculated that the localized ADC changes might be caused by regional imbalances between energy supply and demand, spreading depression, or an excitotoxic mechanism. However, there are no data on the splenium of the corpus callosum in this study.

The localized reversible high signal intensities on diffusion-weighted MRI in hypoglycemia are not detected only at the splenium of the corpus callosum, but also at the internal

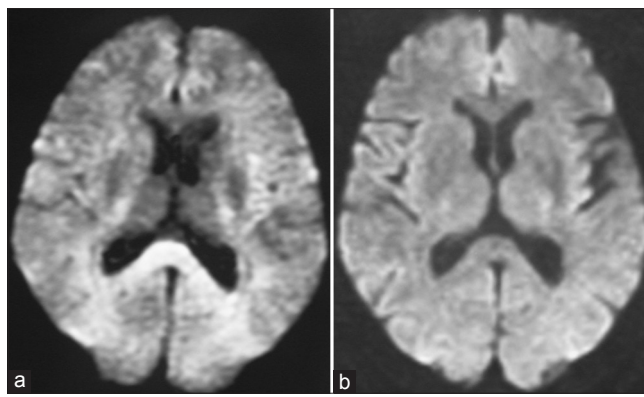


Figure 6: (a) Boomerang-shaped high signal intensity was detected in the splenium of the corpus callosum on diffusion-weighted MRI (b) The lesion had disappeared on MRI on the next day with the recovery from hypoglycemia

capsule or basal ganglia,^[3,13] deep white matter,^[8] or cerebral cortex.^[14] In the present study, localized reversible high signal intensities on diffusion-weighted MRI were found in six of the 70 cases (8.6%). They were at the splenium of the corpus callosum in four cases (5.7%), and right frontal cortex and bilateral frontal white matter in one each. The lesions of all six cases had disappeared on MRI on the next day with the recovery from hypoglycemia. Although Doherty *et al.*^[9] mentioned that the splenium of the corpus callosum may be easily perturbed by a cellular fluid mechanism when compared with surrounding tissues, the reason why the reversible high signal intensity lesion is apt to present in the splenium of the corpus callosum is still unclear. There are two types of lesion in the splenium: Boomerang^[8,13] and oval shaped.^[10,15] There were two cases each in the present study. The significance of the shape of lesions remains unclear. We require the further accumulation of cases.

There are some reports^[3,13] concerning the relationship between the localized reversible high signal intensity lesion at the internal capsule and hemiparesis. However, no cases that presented with hemiparesis showed a lesion on MRI in the present study. And, no cases that presented with convulsions showed a lesion on MRI in the present study, either.

Of the six cases which showed the localized reversible high signal intensities on diffusion-weighted MRI, the mean age was 76.5 years, and the mean blood sugar level on arrival was 41.17 mg/dl (range, 26-68). Both were slightly higher than the means of the 70 cases. There was no association between the lesion and level of hypoglycemia. As in cases 14 and 27, the lesion can be seen in cases which showed mild consciousness disturbance. Therefore, the degree of consciousness disturbance does not relate to the appearance of the lesion. In this study, the consciousness disturbance disappeared with recovery from hypoglycemia and, fortunately, no neurological sequelae were observed in any cases. We could not investigate the relation between the lesion and prognosis. In case 2, the patient

received insulin, and in case 11, 14, 23, and 27, the patients received oral hypoglycemic agents. These agents were variable. There was no specific agent. In case 28, the patient was not diabetic, with HbA1c in the normal range (4.6%). Therefore, the lesion can be seen regardless of the presence or absence of diabetes mellitus.

Conclusion

The present study showed that 8.6% (5.7% at the splenium) of hypoglycemic patients with consciousness disturbance who were referred to the neurosurgical department presented with localized reversible high signal intensities on diffusion-weighted MRI. These lesions are reversible if the patients undergo treatment without delay. The significance of these lesions is still unclear. However, when a high signal intensity lesion that is not reasonable for the symptom is detected on diffusion-weighted MRI, an immediate check of the blood sugar level is mandatory.

References

1. Kagawa K, Okada H. Reversible splenial lesion of the corpus callosum on diffusion-weighted magnetic resonance imaging in hypoglycemic hemiparesis: Report of two cases. *No Shinkei Geka* 2009;37:473-8.
2. Endo H, Shimizu H, Tominaga T, Yoshimoto T. Transient hyperintensity lesions on diffusion-weighted MRI in the bilateral internal capsules due to hypoglycemic coma. *No To Shinkei* 2003;55:174-5.
3. Cordonnier C, Oppenheim C, Lamy C, Meder JF, Mas JL. Serial diffusion and perfusion-weighted MR in transient hypoglycemia. *Neurology* 2005;65:175.
4. Albayram S, Ozer H, Gokdemir S, Gulsen F, Kiziltan G, Kocer N, *et al.* Reversible reduction of apparent diffusion coefficient values in bilateral internal capsules in transient hypoglycemia-induced hemiparesis. *Am J Neuroradiol* 2006;27:1760-2.
5. Malouf R, Brust JC. Hypoglycemia: Causes, neurological manifestations, and outcome. *Ann Neurol* 1985;17:421-30.
6. Mori F, Nishie M, Houzen H, Yamaguchi J, Wakabayashi K. Hypoglycemic encephalopathy with extensive lesions in the cerebral white matter. *Neuropathology* 2006;26:147-52.
7. Fujioka M, Okuchi K, Hiramatsu KI, Sakaki T, Sakaguchi S, Ishii Y. Specific changes in human brain after hypoglycemic injury. *Stroke* 1997;28:584-7.
8. Böttcher J, Kunze A, Kurrat C, Schmidt P, Hagemann G, Witte OW, *et al.* Localized reversible reduction of apparent diffusion coefficient in transient hypoglycemia-induced hemiparesis. *Stroke* 2005;36:20-2.
9. Doherty MJ, Jayadev S, Watson NF, Konchada RS, Hallam DK. Clinical implications of splenium magnetic resonance imaging signal changes. *Arch Neurol* 2005;62:433-7.
10. Garcia-Monco JC, Martínez A, Brochado AP, Saralegui I, Cabrera A, Beldarrain MG. Isolated and reversible lesions of the corpus callosum: A distinct entity. *J Neuroimaging* 2010;20:1-2.
11. Garcia-Monco JC, Cortina IE, Ferreira E, Martínez A, Ruiz L, Cabrera A, *et al.* Reversible splenial lesion syndrome (RESLES): What's in a name? *J Neuroimaging* 2011;21:e1-14.
12. Hasegawa Y, Formato JE, Latour LL, Gutierrez JA, Liu KF, Garcia JH, *et al.* Severe transient hypoglycemia causes reversible change in the apparent diffusion coefficient of water. *Stroke* 1996;27:1648-55.
13. Terakawa Y, Tsuyuguchi N, Nunomura K, Murayama N, Fujishige M, Yamamura A, *et al.* Reversible diffusion-weighted imaging changes in the splenium of the corpus callosum and internal capsule associated with hypoglycemia: Case report. *Neurol Med Chir (Tokyo)* 2007;47:486-8.
14. Jung SL, Kim BS, Lee KS, Yoon KH, Byun JY. Magnetic resonance imaging and diffusion-weighted imaging changes after hypoglycemic coma. *J Neuroimaging* 2005;15:193-6.
15. Hegde A, Kei PL, Ahuja MS. Case of the month. The case of the vanishing splenial lesion. *Br J Radiol* 2009;82:262-3.

How to cite this article: Katoh M, Yoshino M, Aoki T, Abumiya T, Imamura H, Aida T. Localized reversible high signal intensities on diffusion-weighted MRI in hypoglycemia: A study of 70 cases. *Asian J Neurosurg* 2016;11:412-5.

Source of Support: Nil, **Conflict of Interest:** None declared.