

## CASE REPORT

# Recurrence of spinal schwannoma: Is it preventable?

Satya B. Senapati, Sudhansu S. Mishra, Manmath K. Dhir, Ashis Patnaik, Souvagya Panigrahi

Department of Neurosurgery, SCB Medical College and Hospital, Cuttack, Odisha, India

## ABSTRACT

Spinal schwannomas account for about 25% of primary intradural spinal cord tumors in adult. The prognosis for spinal schwannomas is excellent in most cases. Complete resection is curative. However following subtotal removal, recurrence develops after several years. We describe a case of recurrent spinal schwannoma who had been operated twice before for same disease. The possible cause of recurrence and difficulties in reoperation are discussed.

**Key words:** Recurrent, spinal, schwannoma

## Introduction

Schwannoma (Neurilemmoma) and neurofibroma are benign peripheral nerve sheath tumors.<sup>[1]</sup> These tumors are associated with a genetic condition called neurofibromatosis (NF). NF1 affects approximately 1 in 2,000 to 1 in 5,000 births and NF2 affects 1 in 35,000 to 1 in 40,000 births worldwide. NF1 is associated with neurofibromas and NF2 is associated with schwannomas. Bilateral vestibular schwannomas are pathognomonic of NF2. Spinal schwannomas arises from spinal nerve root sheaths. Multiple schwannomas at different spinal level is a common finding in NF2. Schwannoma is generally separable from the underlying nerve, so marginal excision spares the parent nerve. For neurofibromas, a resection of the nerve with the tumor is necessary because it can't be separated from the nerve fibers.<sup>[2]</sup>

## Case Report

A 45 years old female presented to us with complains of lower back pain for last 6 months. Pain was insidious in onset, later on it radiated to right lower limb followed by left limb. Two months later she noticed spasticity in right lower limb followed by left limb. Weakness increased to such an extent that she becomes total bed ridden for last 2 month. She had to strain

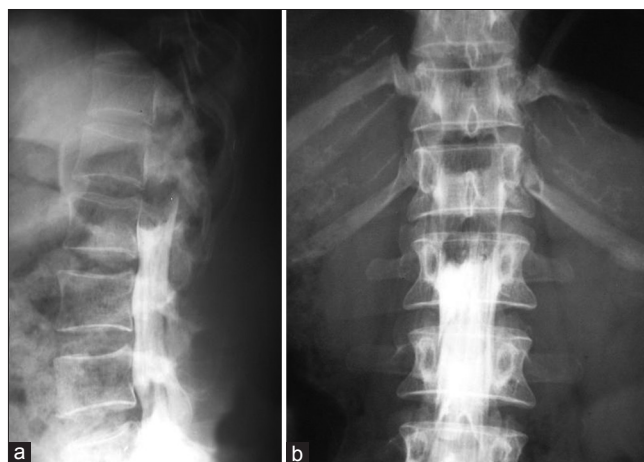to evacuate her bowl and bladder for last 15 days. Her past history was suggestive, she had already been operated two times for similar complain. Last operation was done 8 years back. During first operation (9 year back) D-11 to L-2 right hemi-laminectomy with removal of intradural extramedullary schwannoma extending from D-10 to L-1 level was done. This surgery was done based on myelogram finding. In which there was complete block of contrast flow at L-1 level with convex lower outline. Filum terminale was found deviated towards left and posteriorly [Figure 1]. After first surgery when she does not show expected recovery and symptoms relapsed, MRI was done. MRI revealed another right sided intradural extramedullary lesion extending from D-8 to D-10 level and compressing cord [Figure 2]. For which she was reoperated. During 2<sup>nd</sup> surgery D-7 to D-10 right hemi laminectomy with removal of intradural extramedullary neurilemoma, extending from D-8 to D-10 level done.

There was no family history of neurofibromatosis. On examination we found, no neurocutaneous marker over her

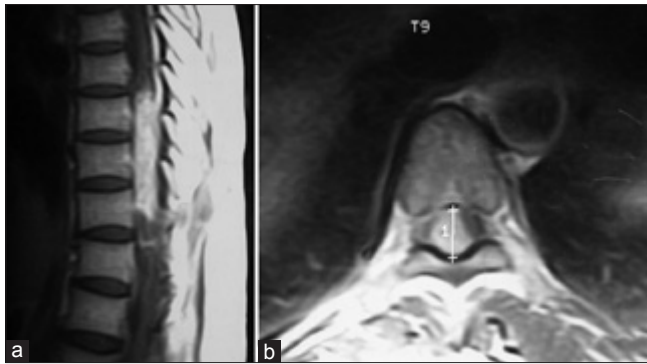
Access this article online	
Quick Response Code:	Website: www.asianjns.org
	DOI: 10.4103/1793-5482.145060

### Address for correspondence:

Dr. Satya Bhusan Senapati, Department of Neurosurgery, SCB Medical College and Hospital, Cuttack - 753 007, Odisha, India. E-mail: satya.bhusan.senapati@gmail.com



**Figure 1:** (a and b) Myelogram showing complete block of contrast flow at L-1 level with convex lower outline. Filum terminale was found deviated towards left and posteriorly

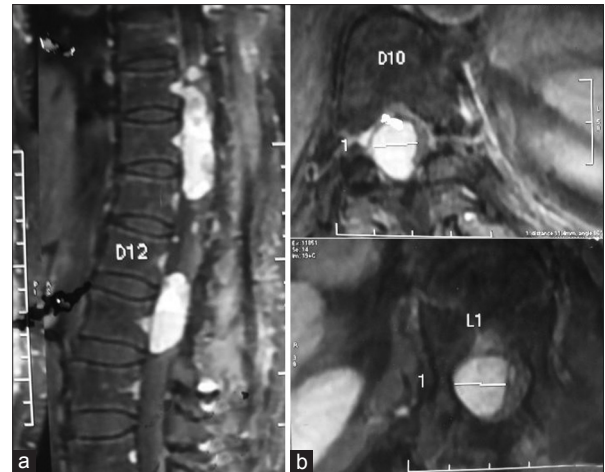


**Figure 2:** (a and b) MRI revealed another right sided intradural extramedullary lesion extending from D-8 to D-10 level and compressing cord, after 1 year of first surgery

body. Her higher mental function was normal, cranial nerves were intact. No motor or sensory deficit was found over both upper limbs. Right lower limb was spastic and contracted at knee and ankle joint, left was hypertonic. Power of right and left lower limb were 3/5 and 4+/5 respectively. Jerks exaggerated in both the side and plantar was bilaterally up going. There was sensory impairment of all modalities below L-1 level on both the side (Right > Left). Her recent MRI revealed two separately located right sided intradural extramedullary, homogenously enhancing, well marginated mass exactly at the previous operated sites [Figure 3]. She was again operated. Out of previous surgery normal anatomy was lost. There was lot of adhesion both extra and intra durally. There was no clear cleavage between tumor and cord structure. Using microsurgical techniques, tumor was removed in piecemeal. Tumor was histologically conformed as schwannoma. Immediate Post operatively her power dropped to 2/5. Gradually she regained her power in next 1 month to 4+ /5.

## Discussion

As schwannoma is a benign well encapsulated tumor, complete removal is expected from surgery. Recurrence is expected in cases of NF, but usually at a site different from previous site. In case of large dumbbell tumors if residual tumor is left recurrence can occur.<sup>[3]</sup> Analyzing our case we found that myelogram had failed to detect second lesion that was lying above first one, which is an inherent problem with this diagnostic modality. This lead to early recurrence of symptoms within 1 year of first surgery. During second surgery Surgeon must have felt difficulty in re-operating at same sight that we faced during third surgery leading to a vicious cycle. Second recurrence of lesions exactly at previous operating sights after 8 years of second surgery might be due to incomplete removal during previous two surgeries, where microscope was



**Figure 3:** (a and b) Recent MRI revealed two separately located right sided intradural extramedullary, homogenously enhancing, well marginated mass exactly at the previous operated sites

not used. Instead of long segment laminectomy, laminoplasty would have been a better option. Laminoplasty not only gives stability but also prevents epidural scar formation.<sup>[4]</sup>

## Conclusion

The outcome of surgical treatment for benign spinal neoplasm is considered to be excellent. Risk of recurrence is estimated to be very low, except with subtotal resections. When recurrence occurs it behaves like malignant tumor, because of distorted anatomy and lot of adhesion out of previous surgery leading to difficulty for 2<sup>nd</sup> approach. Complete removal of tumor with capsule becomes difficult. With use of MRI as diagnostic modality and microsurgical techniques recurrence can be avoided. Therefore every attempt should be made to remove tumor completely during 1<sup>st</sup> surgery.

## References

1. Dorsi MJ, Belzberg AJ. Paraspinal nerve sheath tumors. *Neurosurg Clin N Am* 2004;15:217-22.
2. Jinnai T, Koyama T. Clinical characteristics of spinal nerve sheath tumors: Analysis of 149 cases. *Neurosurgery* 2005;56:510-5.
3. Seppala MT, Haltia MJ, Sankila RJ, Jaaskelainen JE, Heiskanen O. Long-term outcome after removal of spinal schwannoma: A clinicopathological study of 187 cases. *J Neurosurg* 1995;83:621-6.
4. Shinichi Hida, Masatoshi Naito, Jun Arimizu, Yuichiro Morishita, and Atsuhiko Nakamura. The transverse placement laminoplasty using titanium miniplates for the reconstruction of the laminae in thoracic and lumbar lesion. *Eur Spine J* 2006;15:1292-7.

**How to cite this article:** Senapati SB, Mishra SS, Dhir MK, Patnaik A, Panigrahi S. Recurrence of spinal schwannoma: Is it preventable?. *Asian J Neurosurg* 2016;11:451-2.

**Source of Support:** Nil, **Conflict of Interest:** None declared.