

Role of endoscopic third ventriculostomy in tuberculous meningitis with hydrocephalus

Yad R. Yadav, Vijay S. Parihar, Mina Todorov¹, Yatin Kher, Ishwar D. Chaurasia², Sonjjay Pande³, Hemant Namdev

Departments of Neurosurgery, ¹Surgery, St. Joseph Mercy Oakland Hospital, Pontiac, Michigan, USA, ²Neurosurgery, Gandhi Medical College, Bhopal, ³Radio Diagnosis, NSCB Medical College, Jabalpur, Madhya Pradesh, India

ABSTRACT

Hydrocephalus is one of the commonest complications of tuberculous meningitis (TBM). It can be purely obstructive, purely communicating, or due to combinations of obstruction in addition to defective absorption of cerebrospinal fluid (CSF). Endoscopic third ventriculostomy (ETV) as an alternative to shunt procedures is an established treatment for obstructive hydrocephalus in TBM. ETV in TBM hydrocephalus can be technically very difficult, especially in acute stage of disease due to inflamed, thick, and opaque third ventricle floor. Water jet dissection can be helpful in thick and opaque ventricular floor patients, while simple blunt perforation is possible in thin and transparent floor. Lumbar peritoneal shunt is a better option for communicating hydrocephalus as compared to VP shunt or ETV. Intraoperative Doppler or neuronavigation can help in proper planning of the perforation to prevent neurovascular complications. Choroid plexus coagulation with ETV can improve success rate in infants. Results of ETV are better in good grade patients. Poor results are observed in cisternal exudates, thick and opaque third ventricle floor, acute phase, malnourished patients as compared to patients without cisternal exudates, thin and transparent third ventricle floor, chronic phase, well-nourished patients. Some of the patients, especially in poor grade, can show delayed recovery. Failure to improve after ETV can be due to blocked stoma, complex hydrocephalus, or vascular compromise. Repeated lumbar puncture can help faster normalization of the raised intracranial pressure after ETV in patients with temporary defect in CSF absorption, whereas lumbar peritoneal shunt is required in permanent defect. Repeat ETV is recommended if the stoma is blocked. ETV should be considered as treatment of choice in chronic phase of the disease in obstructive hydrocephalus.

Key words: Cerebrospinal fluid shunt, endoscopic third ventriculostomy, hydrocephalus, neuroendoscopy, tuberculous meningitis

Introduction

Endoscopic techniques are being increasingly used in the management of various intracranial pathologies in recent times.^[1-5] Hydrocephalus is one of the commonest complications of tuberculous meningitis (TBM).^[6] It can be classified as purely obstructive, purely communicating, or due to combinations of obstruction in addition to defective absorption.^[7,8] Endoscopic third ventriculostomy (ETV) as an

alternative to shunt procedures is an established treatment for obstructive hydrocephalus in TBM.^[7,9-20] Role of ETV is controversial in communicating hydrocephalus and in acute phase of disease. The present article is aimed to review the role of ETV in TBM hydrocephalus.

Indications of ETV in TBM hydrocephalus

ETV is indicated in obstructive hydrocephalus in TBM. Most of the researchers prefer lumbar peritoneal shunt in communicating hydrocephalus,^[21,22] although there are reports of ETV being performed in communicating hydrocephalus.^[13,15]

Endoscopic third ventriculostomy procedure

ETV is technically difficult in post-infective hydrocephalus, especially in acute phase of disease due to presence of inflammation, thick and opaque floor of third ventricle.^[7,10,17] It is comparatively simple in chronic phase of disease. There is an increased risk of hemorrhage and neurovascular injury, especially in acute phase.^[10] Difficult cases in acute stage can be managed by water jet dissection.^[10] Simple cases, in chronic phase, can be dealt by blunt perforation of the floor of third ventricle. Although ETV is technically possible in almost all cases of TBM hydrocephalus, proper case selection

Access this article online

Quick Response Code:



Website:

www.asianjns.org

DOI:

10.4103/1793-5482.145100

Address for correspondence:

Dr. Y. R. Yadav, 105 Nehru Nagar, Opposite Medical College, Jabalpur, Madhya Pradesh - 482 003, India.
E-mail: yadavyr@yahoo.co.in

and the adequate experience of the surgeon is important for optimal results.^[9] Surgeon should have sufficient experience in neuroendoscopic procedures before starting ETV in TBM hydrocephalus. Initial experience should be gained in congenital hydrocephalus and other simpler endoscopic techniques.

Burr hole site should be carefully selected and should be in line with Foramen of Monro and the interpeduncular cistern. Fenestration in the third ventricle floor should be in between the mammillary bodies and the infundibular recess. It should be anterior to the basilar artery and at the thinnest point on the floor of the third ventricle. Minimal or no heat in the form of cautery or any other source should be used. Stoma can be enlarged by the Fogarty catheter or by the ventriculostomy forceps. The Lilliequist membrane, if present, should be perforated. Choroid plexus coagulation can be performed to increase success rate of ETV in infants.^[23] Tubercles on the choroid plexus and the ventricular margin can be seen in some cases [Figures 1 and 2].

There can be fatal complication of massive hemorrhage due to non-visualization of the basilar artery or its branch during ETV when the floor is thick or opaque. Intraoperative Doppler or neuronavigation can help to overcome this problem.^[24,25] Virtual neuroendoscopy based on 3-D ultrasonography can reveal detailed anatomical information of the ventricular system including the foramen of Monro and the floor of the third ventricle. This can be helpful in proper planning of the fenestration.^[26]

Diagnosis of patent stoma

Conventional MR imaging criteria such as resolution of periventricular edema, widening of subarachnoid space, and diminution of ventricular size are helpful in deciding about stoma patency. These criteria are indirect judgment of stoma patency and have low sensitivity. Ventriculography, though invasive, is useful in diagnosis of stoma patency.^[27]

Follow up of patients with ETV mainly relies on demonstration of flow or flow void areas across the ventriculostomy defect. Cine phase contrast MRI technique has a high sensitivity to detect flow void and has been extensively used to document the patency of ETV stoma.^[28,29] Three dimensional constructive interference in steady state (CISS) MR technique has also gained importance in pre and post procedural planning. It has been found to be sensitive to flow.^[30,31]

Success rate of ETV

Clinical improvement in TBM hydrocephalus depends on many factors such as management of hydrocephalus, presence of infarct, and clinical status of the patient. Failure to improve after ETV does not always mean that the ETV is malfunctioning. It can be due to an infarct or poor preoperative status. Patent stoma does not necessarily mean that the procedure is effective in reducing intracranial pressure (ICP). Complex hydrocephalus is the most important cause of failure to improve after ETV. Other causes of failure to improve after ETV are blocked stoma and infarct. Overall, clinical improvement after ETV alone range from 58 to 77% in various series.^[12,14,17] Yadav *et al.* reported 58% improvement after ETV alone which rose to 80% when lumbar peritoneal shunt was added.^[17]

The comparatively poor results of ETV in TBM are due to high incidence of complex hydrocephalus.^[17] This incidence is higher in acute phase of disease as compared to chronic phase.^[17] It is therefore better to do shunt surgery and avoid ETV in acute phase of the disease.^[9] The obliteration of cerebrospinal fluid (CSF) pathways and defective absorption of CSF from arachnoid villi can result in persistently raised intracranial pressure in TBM after ETV. Defective absorption and/or obliteration of CSF pathways in complex hydrocephalus can be temporary or permanent.^[7] Most of the patients have temporary defect of absorption and these patients should be managed by repeated lumbar punctures after ETV before labeling them as failed ETV patients.^[17,32]

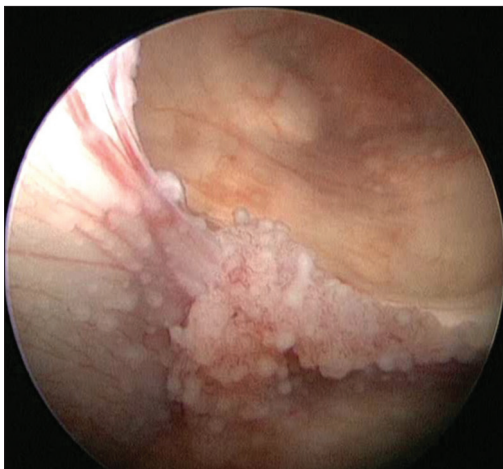


Figure 1: Multiple tubercles on choroid plexuses and ventricle wall

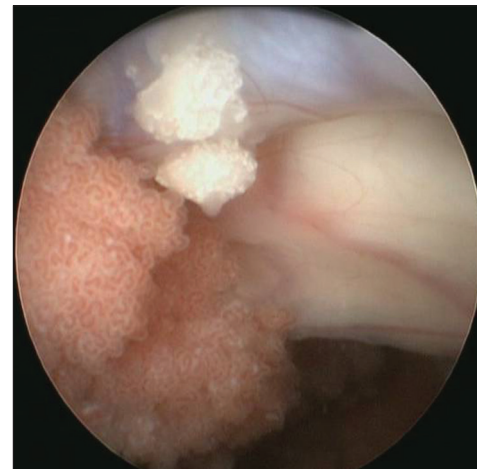

Figure 2: Two tubercles on the ventricle wall

Majority of patients in TBM recover early,^[14,17] about 17 to 20% may show delayed recovery, especially in poor grade. Radiological recovery can also be very slow.^[14,17] Decrease in the size of the ventricle occurs very slowly after ETV. The presence of basal exudates, type of the third ventricle floor, age, clinical grade, and the phase of disease can influence recovery in TBM after ETV. Presence of basal exudates^[12,17] is associated with poor prognosis as compared to their absence. Clinical outcome is better in thin and transparent third ventricle floor as compared to thick and opaque floor.^[17,33] The success rate of ETV in poor clinical grade,^[12,17] and acute phase of the disease^[9,17] is lower as compared to good clinical grade and chronic phase of the disease. Adult patients may fair slightly better as compared to children.^[17]

Complications

ETV in TBM can be associated with intraoperative and the postoperative complications. One may fail to perform ETV in some patients. It may be dangerous to perform ETV when structures underneath the perforations are not clearly seen. This can result in neurovascular injuries including fatal bleeding. The vascular injury can be partly avoided by making perforation in the midline, between the infundibular recess and the mammillary bodies, just behind the dorsum sellae. Other complications can be seizures, oculomotor nerve palsy, forniceal injury, bradycardia, basilar artery traumatic aneurysm, and subdural hematoma. Postoperative complications can be infection, CSF leak, blocked stoma, thermoregulation disturbance, diabetes insipidus, and syndrome of inappropriate antidiuretic hormone secretion (SIADH). Patient may not improve in spite of patent stoma due to complex hydrocephalus or ischemia.

Blocked stoma can also be seen in ETV. Generally, the relative risk of ETV failure is initially higher than that for shunt, but after about 3 months, the relative risk becomes progressively lower for ETV.^[34] After the early high-risk period of ETV failure, a patient can experience a long-term treatment survival advantage compared with shunt. It might take several years to realize this benefit of long-term success.

Complication avoidance

Forniceal injury and other neural injuries can be avoided by proper planning of burr hole, avoiding side movements, and selecting proper patients with significantly enlarged foramen of Monro and third ventricle. ETV in patients with comparatively small foramen of Monro can be done with the help of smaller size of the telescope or by flexible scope. Intraoperative bleeding should be avoided by using water jet dissection, and by avoiding the stretching of the tough third ventricle floor. Excessive side movement should be avoided to prevent bleeding from injuries to the fornix and veins at foramen of Monro. Rarely, blood might trickle from burr hole site into the ventricle, proper hemostasis must be achieved before entering the ventricle. Thorough

inspection is essential before making perforation in the third ventricle floor. Fenestration on the vessel should be avoided. Bradycardia due to the raised ICP should be prevented by keeping the outflow channel patent. Bradycardia due to the stretch on the brain stem should be avoided, especially during perforation of tough third ventricle floor.

Postoperative fever can be due to use of electrocautery which should be avoided. Postoperative CSF leak can be decreased by plugging cortical and dural opening by Gel foam, direct dural closure, especially in large ventriculomegaly in infants,^[11] or by using artificial dural substitute and tissue sealant in patients with high risk of CSF leak. Postoperative CSF leak can also be reduced by galeal pericranial flap. Acute subdural hematoma can be prevented by making burr hole at highest point by flexing the neck, proper hemostasis at burr hole site, and by preventing brain collapse using constant fluid irrigation.

Postoperative care

Failure to improve after ETV can be due to the blocked stoma, complex hydrocephalus, or vascular compromise. Postoperative raised ICP has been observed following ETV. The raised ICP observed in a group of patients in the early postoperative days is probably related to complex hydrocephalus. Temporary defect of CSF absorption can be overcome by repeated lumbar punctures. A cycle of one to three lumbar punctures should always be performed in patients who remain symptomatic and who show increasing ventricular dilatation after the ETV, before it is assumed to have failed.^[17] Some form of shunt is required in permanent defect. Lumbar peritoneal shunt is very effective in management of communicating hydrocephalus in patients who do not improve after ETV due to complex hydrocephalus. Lumbar puncture helps by increasing the compliance and the buffering capacities of the spinal subarachnoid spaces. It probably decreases the CSF outflow resistance from the ventricular system, facilitating the decrease of the ventricular volume and allowing faster permeation of the intracranial subarachnoid spaces.

Although external ventricular drainage has not been used after ETV in TBM, it has been tried in other pathologies.^[35] Elgama^[35] studied EVD insertion and measured postoperative continuous ICP monitoring after ETV. The EVD is helpful in providing accurate assessment of the success of the ETV and the patency of the stoma in the early postoperative days by CT ventriculography. It can also be used to install intraventricular antibiotics when there is any infection. It also allows intermittent CSF drainage to relieve raised ICP in blocked stoma.

Treatment Recommendations in TBM Hydrocephalus

ETV is recommended in chronic phase in TBM hydrocephalus. The ventriculoperitoneal shunt should be performed in the acute

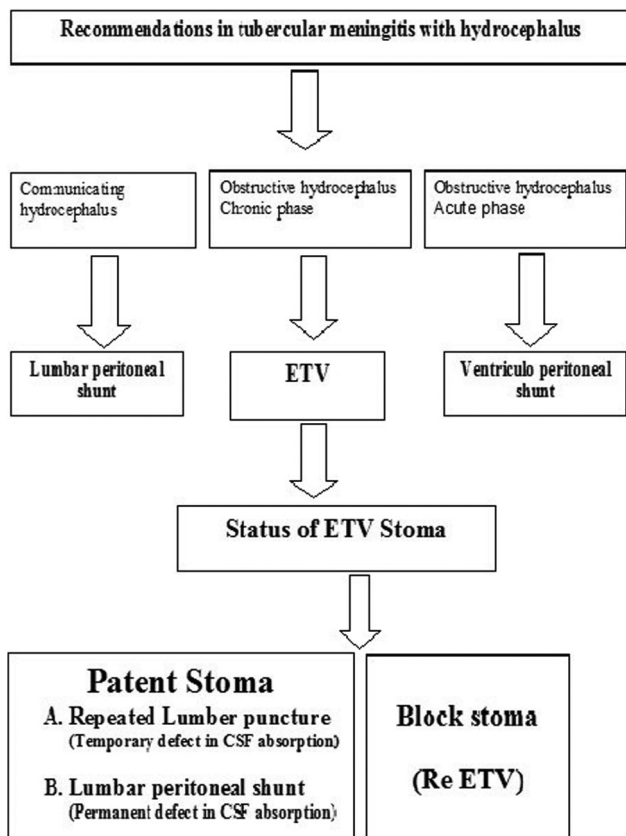


Figure 3: Flow diagram of treatment plan in tuberculous meningitis with hydrocephalus.

phase of the disease, especially if surgeon does not have sufficient experience in neuroendoscopy. Lumbar peritoneal shunt seems to be better option in communicating hydrocephalus.^[21,22] Stoma patency should be determined if there is no clinical recovery and there is an evidence of raised ICP after ETV. If the stoma is patent and patient continues to have raised ICP, it can be due to complex hydrocephalus. This complex hydrocephalus due to temporary defect in CSF absorption or circulation can be overcome by repeated lumbar punctures. Lumbar peritoneal shunt should be performed in cases with the permanent defect in CSF dynamics. Repeat ETV is recommended if the stoma is blocked [Figure 3].

References

1. Yadav YR, Yadav S, Sherekar S, Parihar V. A new minimally invasive tubular brain retractor system for surgery of deep intracerebral hematoma. *Neurol India* 2011;59:74-7.
2. Yadav YR, Parihar V, Sinha M, Jain N. Endoscopic treatment of the suprasellar arachnoid cyst. *Neurol India* 2010;58:280-3.
3. Yadav YR, Sinha M, Neha, Parihar V. Endoscopic management of brain abscesses. *Neurol India* 2008;56:13-6.
4. Yadav YR, Mukerji G, Shenoy R, Basoor A, Jain G, Nelson A. Endoscopic management of hypertensive intraventricular haemorrhage with obstructive hydrocephalus. *BMC Neurol* 2007;7:1.
5. Yadav YR, Parihar V, Agarwal M, Sherekar S, Bhatele PR. Endoscopic vascular decompression of the trigeminal nerve. *Minim Invasive Neurosurg* 2011;54:110-4.
6. Rajshekhar V. Management of hydrocephalus in patients with tuberculous meningitis. *Neurol India* 2009;57:368-74.

7. Yadav YR, Mukerji G, Parihar V, Sinha M, Pandey S. Complex hydrocephalus (combination of communicating and obstructive type): An important cause of failed endoscopic third ventriculostomy. *BMC Res Notes* 2009;16:137.
8. Yadav YR, Parihar V. Management of hydrocephalus in patients with tuberculous meningitis. *Neurol India* 2009;57:691.
9. Bhagwati S, Mehta N, Shah S. Use of endoscopic third ventriculostomy in hydrocephalus of tubercular origin. *Childs Nerv Syst* 2010;26:1675-82.
10. Yadav YR, Shenoy R, Mukerji G, Parihar V. Water jet dissection technique for endoscopic third ventriculostomy minimizes the risk of bleeding and neurological complications in obstructive hydrocephalus with a thick and opaque third ventricle floor. *Minim Invasive Neurosurg* 2010;53:155-8.
11. Yadav YR, Jaiswal S, Adam N, Basoor A, Jain G. Endoscopic third ventriculostomy in infants. *Neurol India* 2006;54:161-3.
12. Chugh A, Husain M, Gupta RK, Ojha BK, Chandra A, Rastogi M. Surgical outcome of tuberculous meningitis hydrocephalus treated by endoscopic third ventriculostomy: Prognostic factors and postoperative neuroimaging for functional assessment of ventriculostomy. *J Neurosurg Pediatr* 2009;3:371-7.
13. Singh I, Haris M, Husain M, Husain N, Rastogi M, Gupta RK. Role of endoscopic third ventriculostomy in patients with communicating hydrocephalus: An evaluation by MR ventriculography. *Neurosurg Rev* 2008;31:319-25.
14. Singh D, Sachdev V, Singh AK, Sinha S. Endoscopic third ventriculostomy in post-tubercular meningitis hydrocephalus: A preliminary report. *Minim Invasive Neurosurg* 2005;48:47-52.
15. Jonathan A, Rajshekhar V. Endoscopic third ventriculostomy for chronic hydrocephalus after tuberculous meningitis. *Surg Neurol* 2005;63:32-4.
16. Figaji AA, Fieggen AG, Peter JC. Endoscopic third ventriculostomy in tuberculous meningitis. *Childs Nerv Syst* 2003;19:217-25.
17. Yadav YR, Parihar V, Agrawal M, Bhatele PR. Endoscopic third ventriculostomy in tubercular meningitis with hydrocephalus. *Neurol India* 2011;59:855-60.
18. Husain M, Jha DK, Rastogi M, Husain N, Gupta RK. Role of neuroendoscopy in the management of patients with tuberculous meningitis hydrocephalus. *Neurosurg Rev* 2005;28:278-83.
19. Tandon V, Mahapatra AK. Management of post-tubercular hydrocephalus. *Childs Nerv Syst* 2011;27:1699-707.
20. Figaji AA, Fieggen AG. Endoscopic challenges and applications in tuberculous meningitis. *World Neurosurg* 2013;79 (2 Suppl):S24. e9-14.
21. Yadav YR, Parihar V, Sinha M. Lumbar peritoneal shunt. *Neurol India* 2010;58:179-84.
22. Yadav YR, Pande S, Raina VK, Singh M. Lumboperitoneal shunts: Review of 409 cases. *Neurol India* 2004;52:188-90.
23. Warf BC. Comparison of endoscopic third ventriculostomy alone and combined with choroid plexus cauterization in infants younger than 1 year of age: A prospective study in 550 African children. *J Neurosurg* 2005;103 (6 Suppl):475-81.
24. Schmidt RH. Use of a microvascular Doppler probe to avoid basilar artery injury during endoscopic third ventriculostomy. Technical note. *J Neurosurg* 1999;90:156-9.
25. Hopf NJ, Grunert P, Darabi K, Busert C, Bettag M. Frameless neuronavigation applied to endoscopic neurosurgery. *Minim Invasive Neurosurg* 1999;42:187-93.
26. Jödicke A, Berthold LD, Scharbrodt W, Schroth I, Reiss I, Neubauer BA, et al. Endoscopic surgical anatomy of the paediatric third ventricle studied using virtual neuroendoscopy based on 3-D ultrasonography. *Childs Nerv Syst* 2003;19:325-31.
27. Joseph VB, Raghuram L, Korah IP, Chacko AG. MR ventriculography for the study of CSF flow. *AJNR Am J Neuroradiol* 2003;24:373-81.
28. Bargallo N, Olondo L, Garcia AI, Capurro S, Caral L, Rumia J. Functional analysis of third ventriculostomy patency by quantification of CSF stroke volume by using cine phase-contrast MR imaging. *AJNR Am J Neuroradiol* 2005;26:2514-21.
29. Feng H, Huang G, Liao X, Fu K, Tan H, Pu H, et al. Endoscopic third ventriculostomy in the management of obstructive hydrocephalus: An outcome analysis. *J Neurosurg* 2004;100:626-33.

30. Doll A, Christmann D, Kehrl P, Abu Eid M, Gillis C, Bogorin A, *et al.* Contribution of 3D CISS MRI for pre- and post-therapeutic monitoring of obstructive hydrocephalus. *J Neuroradiol* 2000;27:218-25.
31. Kurihara N, Takahashi S, Tamura H, Higano S, Furuta S, Jokura H, *et al.* Investigation of hydrocephalus with three dimensional constructive interference in steady state MRI. *Neuroradiology* 2000;42:634-8.
32. Cinalli G, Spennato P, Ruggiero C, Aliberti F, Zerah M, Trischitta V, *et al.* Intracranial pressure monitoring and lumbar puncture after endoscopic third ventriculostomy in children. *Neurosurgery* 2006;58:126-36.
33. Jha DK, Mishra V, Choudhary A, Khatri P, Tiwari R, Sural A, *et al.* Factors affecting the outcome of neuroendoscopy in patients with tuberculous meningitis hydrocephalus: A preliminary study. *Surg Neurol* 2007;68:35-41.
34. Kulkarni AV, Drake JM, Kestle JR, Mallucci CL, Sgouros S, Constantini S. Canadian pediatric neurosurgery study group. Endoscopic third ventriculostomy vs cerebrospinal fluid shunt in the treatment of hydrocephalus in children: A propensity score-adjusted analysis. *Neurosurgery* 2010;67:588-93.
35. Elgamal EA. Continuous monitoring of intracranial pressure after endoscopic third ventriculostomy in the management of CSF shunt failure. *Minim Invasive Neurosurg* 2010;53:49-54.

How to cite this article: Yadav YR, Parihar VS, Todorov M, Kher Y, Chaurasia ID, Pande S, *et al.* Role of endoscopic third ventriculostomy in tuberculous meningitis with hydrocephalus. *Asian J Neurosurg* 2016;11:325-9.

Source of Support: Nil, **Conflict of Interest:** None declared.