

CASE REPORT

Late onset of subdural hematoma after bifrontal contusion

Bora Gürer, Hayri Kertmen, Habibullah Dolgun, Zeki Sekerci

Neurosurgery Clinic, Ministry of Health Diskapi Yildirim Beyazit Education and Research Hospital, Ankara, Turkey

ABSTRACT

Cerebral cortical contusions are one of the most common computed tomography findings in head-injured patients and common sequel of traumatic brain injury. These contusions tend to show a progressive increase in mass effect on repeated imaging, most small contusions do not require surgical evacuation. However, progression to subdural hematoma (SDH) in a late aspect is unique. Here we present a 71-year-old man with bifrontal contusion, who deteriorated 43 days after initial trauma with sudden onset of acute SDH. This unusual case suggests that neurosurgeons should be alert for the possibility of very late onset of acute SDH after bifrontal contusions.

Key words: Contusion, head trauma, subdural hematoma

Introduction

Cerebral cortical contusions are one of the most common computed tomography (CT) findings in head-injured patients^[1,2] and common sequel of traumatic brain injury (TBI).^[1] Traumatic parenchymal mass lesions occur in up to 8.2% of all TBI^[3] and 13 to 35% of severe TBI.^[2] Most small contusions do not require surgical evacuation. These contusions tend to show a progressive increase in mass effect on repeated imaging^[4] but progression to subdural hematoma (SDH) in a late aspect is unique, only few case reports had been presented.^[5-7] Here we present a patient with bifrontal contusion, who deteriorated 43 days after initial trauma with sudden onset of acute SDH.

Case Report

A 71-year-old man was involved in a road traffic accident as a passenger in a car and brought to the emergency department. He was initially unconscious, localizing the pain, uttering inappropriate words and spontaneously opening his eyes. Cranial CT revealed bifrontal cerebral contusions with minimal

SDH [Figure 1]. After 12 hours his neurological condition was improved, he became alert and oriented. After 24 hours of trauma he was completely normal. At that time a control CT was performed and revealed no significant change in the volume of the hemorrhagic contusion and SDH. Five days after injury he was discharged home with well being.

Forty-three days after the trauma, he was suddenly collapsed at home and brought to the emergency department. His family denied any history of further head trauma and received no medical treatment during this period. He was unconscious, extending to pain, making incomprehensible sounds and opening eyes in response to painful stimuli. Emergent cranial CT demonstrated typical acute SDH on the left with approximately 2-cm shift of the midline structures to the right [Figure 2]. Digital four vessel cerebral angiography revealed no vascular pathology. At surgery, left frontotemporal craniotomy was performed and acute SDH without any chronic component was evacuated. Intracranial pressure monitor was used to record postoperative intracranial pressure, which rose above 35 mmHg within 2 hours. The patient was changed for the worse despite intensive care and he died 2 days after surgery.

Discussion

Traumatic parenchymal mass lesions are common sequel of traumatic brain injury, occurring in up to 8.2% of all traumatic brain injuries, and 13-35% of severe TBI, and comprising as much as %20 of operative intracranial lesions in representative series. Most small parenchymal lesions do not require surgical evacuation.^[2]

It has been reported that the incidence rate of progressive hemorrhagic injury was 8-67% and is associated with a

Access this article online

Quick Response Code:



Website:

www.asianjns.org

DOI:

10.4103/1793-5482.145115

Address for correspondence:

Dr. Bora Gürer, İrfan Bastug Cad. S.B. Diskapi Yildirim Beyazit Eğitim ve Araştırma Hastanesi 1, Beyin Cerrahi Servisi.
E-mail: boragurer@gmail.com

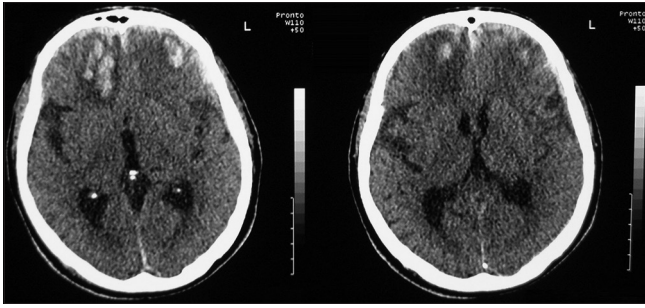


Figure 1: Cranial computed tomography revealed bifrontal cerebral contusions with minimal subdural hematoma

five-fold increase in the risk of clinical worsening and a significant cause of deformity and also death. This progression mostly occurred within the first 48 h postinjury.^[4]

The management of a patient with cerebral contusion can be very difficult. It is not always possible to make decision on which patient will be or not be deteriorated. Although brain contusions are a common neurosurgical condition, surprisingly little has been written about their natural history. There are only few papers about how often deterioration occurs, or about which cases are most at risk. Several factors such as severity of injury, coagulopathy, the need for cardiopulmonary resuscitation in the field, old age, short duration between injury and the first CT scan, multiple hematomas, midline shift, and surgical decompressive procedures have been associated with radiological progression of brain contusions.^[4]

The pathogenesis of delayed intracerebral hematoma is not clear; simply it is thought to be due to a local failure of cerebral blood flow regulation secondary to injury. Relaxation of cerebrovascular resistance leads to transmission of intracerebral pressure to the capillary bed and thus hematoma formation.^[8] Also, other various hypotheses have proposed spontaneous vascular rupture resulting from progressive vascular degeneration,^[9] local metabolic disorders that would injure the vessel wall or increased intracranial venous pressure produced by Valsalva's effect.^[10] In our case, the source of bleeding was most properly to rupture of bridging veins due to brain atrophy as consequences of previous contusion and old age.

Delayed life-threatening SDH may occur in patients on anticoagulation therapy. Also in this situation, very late onset is not common. There was no history of anticoagulation therapy in our case.

There have been well-documented reports of delayed SDH occurred after head injury; the time interval to the second deterioration varies from 15 h to 8 months, and the outcome is mostly poor.^[5-7] The cause of delayed onset was found to be cerebral atrophy and aneurysm. In our presented case, clinical

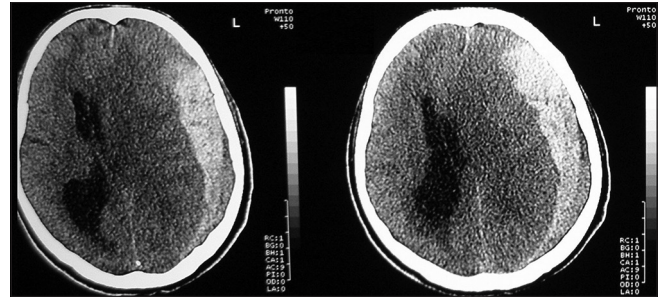


Figure 2: Cranial computed tomography obtained 43 days after initial trauma demonstrated typical acute subdural hematoma on the left with approximately 2-cm shift of the midline structures to the right

history, biochemical and neuroradiological examinations excluded bleeding tendency, vascular abnormalities or tumors.

Conclusion

Deterioration after cerebral contusions may occur almost always in the first 48 h. This unusual case suggests that neurosurgeons should be alert for the possibility of very late onset of acute SDH after bifrontal contusions. Longer clinical follow up is needed in such cases. Patient and family have to be instructed about this condition.

References

1. Becker DP, Miller JD, Ward JD, Greenberg RP, Young HF, Sakalas R. The outcome from severe head injury with early diagnosis and intensive management. *J Neurosurg* 1977;47:491-502.
2. Bullock MR, Chesnut R, Ghajar J, Gordon D, Hartl R, Newell DW, et al. Surgical Management of Traumatic Brain Injury Author Group. Surgical management of traumatic parenchymal lesions. *Neurosurgery* 2006;58:25-46.
3. Mander M, Zralek C, Krawczyk I, Zyciński A, Wencel T, Bazowski P. Surgery or conservative treatment in children with traumatic intracerebral haematoma. *Childs Nerv Syst* 1999;15:267-9.
4. Alahmadi H, Vachhrajani S, Cusimano MD. The natural history of brain contusion: An analysis of radiological and clinical progression. *J Neurosurg* 2010;112:1139-45.
5. Lesoin F, Viaud C, Pruvo J, Redford H, Jomin M. Traumatic and alternating delayed intracranial hematomas. *Neuroradiology* 1984;26:515-6.
6. Matsuda W, Sugimoto K, Sato N, Watanabe T, Fujimoto A, Matsumura A. Delayed onset of posttraumatic acute subdural hematoma after mild head injury with normal computed tomography: A case report and brief review. *J Trauma* 2008;65:461-3.
7. Mlay SM. Delayed intracranial haematomas. *East Afr Med J* 1990;67:717-9.
8. Piepmeier JM, Wagner FC. Delayed post-traumatic extracerebral hematomas. *J Trauma* 1982;22:455-60.
9. Evans JP, Scheinker IM. Histologic studies of the brain following head trauma. *J Neurosurg* 1946;3:101-13.
10. Matsumura A, Shinohara A, Munekata K, Maki Y. Delayed intracerebral hemorrhage after ventriculoperitoneal shunt. *Surg Neurol* 1985;24:503-6.

How to cite this article: Gürer B, Kertmen H, Dolgun H, Sekerci Z. Late onset of subdural hematoma after bifrontal contusion. *Asian J Neurosurg* 2016;11:448.

Source of Support: Nil, **Conflict of Interest:** None declared.