

CASE REPORT

Postoperative seizure following transforaminal percutaneous endoscopic lumbar discectomy

Hayri Kertmen, Bora Gürer, Erdal Resit Yilmaz, Zeki Sekerci

Department of Neurosurgery Clinic, Ministry of Health Diskapi Yildirim Beyazit Education and Research Hospital, Ankara, Turkey

ABSTRACT

Endoscopic surgery for lumbar disc herniation has been available for more than 30 years. Transforaminal percutaneous endoscopic lumbar discectomy is a well-known, safe, and effective method used for the treatment of the lumbar disc herniation. The published complications of the transforaminal percutaneous endoscopic lumbar discectomy consist of infections, thrombophlebitis, dysesthesia, dural tear, vascular injury, and death. Seizure after transforaminal percutaneous endoscopic lumbar discectomy is an extremely rare complication. A 20-year-old patient applied at our department who had undergone transforaminal percutaneous endoscopic lumbar. During the procedure, while performing the discography, non-ionic contrast media was administered into the thecal sac inadvertently. Two hours after surgery, the patient developed generalized tonic-clonic seizure of 5-min duration. Diagnosis of iohexol-induced seizure was made and the patient was treated supportively without anti-epileptics. Here we present the first case of seizure after transforaminal percutaneous endoscopic lumbar discectomy, which was caused by inadvertent administration of the contrast media into the thecal sac.

Key words: Complication, lumbar disc herniation, seizure, transforaminal percutaneous endoscopic lumbar discectomy

Introduction

Endoscopic surgery for lumbar disc herniation (LDH) has been available for more than 30 years. Transforaminal percutaneous endoscopic lumbar discectomy (TPELD) is a well-known, safe, and effective method used for treatment of the patients suffering from LDH. As more patients have undergone this procedure, more postoperative complications start to appear.

Here we present the first case in the literature where TPELD was complicated with postoperative seizure after inadvertent administration of the non-ionic contrast media into the thecal sac.

Case Report

A 20-year-old woman applied to our neurosurgical department with severe low back pain and right sided sciatica. Despite 3 months of conservative treatment, her symptoms

progressively increased. On her neurological examination straight leg rising was positive at 15 degrees on the right and mild weakness of the foot plantar flexion was documented. Magnetic resonance imaging of the spine revealed LDH at the L5-S1 level [Figure 1]. The patient was scheduled for elective TPELD. Her past medical history was unremarkable, and there was no past history of seizure. Because of the patient's choice against local anesthesia, the procedure was performed under intra-tracheal general anesthesia. During the procedure, while performing the discography, about 3 ml of non-ionic contrast media (iohexol) was administered into the thecal sac inadvertently [Figure 2], after that the head of the patient was elevated approximately to 30 degrees. The procedure was performed and accomplished uneventfully.

Two hours after the surgery, the patient developed generalized tonic-clonic seizure of 5-min duration. Computed tomography of the brain revealed a markedly hyper-dense aspect of all intracranial cerebrospinal fluid spaces, including basal cisterns, cortical sulci, and ventricles [Figure 3a]. All biochemical tests were within reference limits. An electroencephalogram performed the next day was also normal. A diagnosis of iohexol induced seizure was made and the patient was treated supportively without anti-epileptics. After 72 h, computed tomography of the brain did not demonstrate any intracranial pathology and reported as normal [Figure 3b]. She subsequently underwent magnetic resonance of the brain, which was also normal. She was discharged home on 4th postoperative day when she was well-being and without any further recurrence of seizure. She remained seizure-free on follow-up 2 months later.

Access this article online

Quick Response Code:



Website:

www.asianjns.org

DOI:

10.4103/1793-5482.145119

Address for correspondence:

Dr. Bora Gürer, İrfan Bastug Cad. S.B. Diskapi Yildirim Beyazit Eğitim ve Araştırma Hastanesi Beyin Cerrahi Servisi, 06110, Ankara/Turkey.
E-mail: boragurer@gmail.com

Discussion

LDH is a common cause of low back pain and sciatica. For patients diagnosed as LDH, who do not achieve satisfactory recovery after conservative treatment, surgical intervention should be considered. TPELD is a minimally invasive, safe,

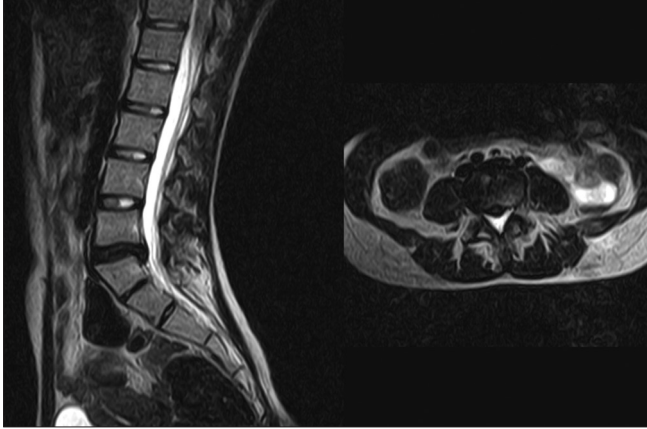


Figure 1: Pre-operative magnetic resonance imaging of the lumbar spine revealed a lumbar disc herniation at the L5-S1 level

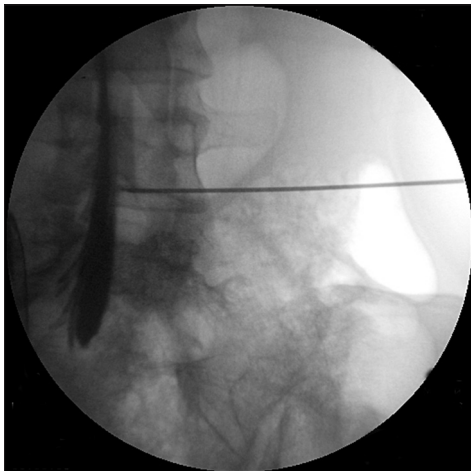


Figure 2: Intra-operative fluoroscopic imaging showed intrathecal administration of the contrast media

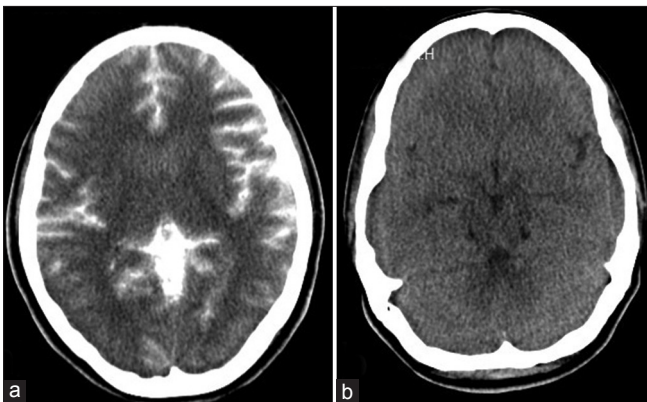


Figure 3: Computed tomography of brain revealed diffuse subarachnoid contrast throughout the brain (a) A repeat computerized tomography scan after 72 h showed complete clearing of the contrast (b)

and effective technique for surgical treatment of LDH.^[1] The published complications of TPELD include infections, thrombophlebitis, dysesthesia, dural tear, vascular injury, and death.^[1-3]

Recently, Choi *et al.*,^[4] reported four patients who developed seizure after percutaneous endoscopic lumbar discectomy. In this report, none of the procedures complicated by inadvertent administration of the contrast media into the thecal sac. They concluded that the mechanism of the seizure is related to increased cervical epidural pressure, and thereby, to increased intracranial pressure owing to increased speed of irrigation fluid or long operative time.

Non-ionic, water-soluble, radiologic contrast media, such as iohexol, have been commonly administered into the thecal sac for myelography. There are few case reports of seizures suspected to be caused by iohexol.^[5-7] The exact mechanism how the contrast media causes seizure is inadequate due to lack of the cases. However, it was hypothesized that the mechanism of seizure induction is either due to neurotoxic effects or an idiosyncratic reaction.^[8] To our knowledge this is the first presented case of seizure after TPELD, which was caused by advertent administration of the non-ionic contrast media into the thecal sac.

The discography is routinely used in TPELD to confirm the approach.^[1,2,9,10] The intra-operative discography procedure is necessary for the selective removal of herniated fragments under fluoroscopic and endoscopic visualization.^[10]

To avoid this complication, care must be given to not to administer the contrast media into the thecal sac. Also, performing this procedure in local anesthesia is more proper because the patient may warn the surgeon with the pain occurred when the dura was punctured.

For patients who developed seizure after TPELD, epileptogenic effects of the contrast media must be suspected. Supportive treatment without anti-epileptics is adequate, but surgeons need to be aware of this rare complication and must inform the patient about the risk of seizure.

References

1. Tzaan WC. Transforaminal percutaneous endoscopic lumbar discectomy. *Chang Gung Med J* 2007;30:226-34.
2. Yeung AT, Tsou PM. Posterolateral endoscopic excision for lumbar disc herniation: Surgical technique, outcome, and complications in 307 consecutive cases. *Spine (Phila Pa 1976)* 2002;27:722-31.
3. Tsou PM, Yeung AT. Transforaminal endoscopic decompression for radiculopathy secondary to intracanal noncontained lumbar disc herniations: Outcome and technique. *Spine J* 2002;2:41-8.
4. Choi G, Kang HY, Modi HN, Prada N, Nicolau RJ, Joh JY, *et al.* Risk of developing seizure after percutaneous endoscopic lumbar discectomy. *J Spinal Disord Tech* 2011;24:83-92.
5. Ahmed I, Pepple R, Jones RP. Absence status epilepticus resulting from amipaque (metrizamide) and omnipaque (iohexol) myelography. *Clin Electroencephalogr* 1988;19:37-42.

6. Dalen K, Kerr HH, Wang AM, Olson RE, Wesolowski DP, Farah J. Seizure activity after iohexol myelography. *Spine (Phila Pa 1976)* 1991;16:384.
7. Altschuler EM, Segal R. Generalized seizures following myelography with iohexol (omnipaque). *J Spinal Disord* 1990;3:59-61.
8. Olsen J. Seizures after myelography with iopamidol. *Am J Emerg Med* 1994;12:329-30.
9. Hirano Y, Mizuno J, Takeda M, Itoh Y, Matsuoka H, Watanabe K. Percutaneous endoscopic lumbar discectomy: Early clinical experience. *Neurol Med Chir (Tokyo)* 2012;52:625-30.
10. Ahn Y. Transforaminal percutaneous endoscopic lumbar discectomy: Technical tips to prevent complications. *Expert Rev Med Devices* 2012;9:361-6.

How to cite this article: Kertmen H, Güler B, Yılmaz ER, Sekerci Z. Postoperative seizure following transforaminal percutaneous endoscopic lumbar discectomy. *Asian J Neurosurg* 2016;11:450.

Source of Support: Nil, **Conflict of Interest:** None declared.

