

## CASE REPORT

# Progression in size of an arterio-venous malformation

Abhidha Shah, Neeraj Patni, Raghvendra Ramdasi, Atul Goel

Department of Neurosurgery, Seth G. S. Medical College and K.E.M Hospital, Parel, Mumbai, Maharashtra, India

## ABSTRACT

We report a case of a young girl who was admitted with history of sudden onset left hemiplegia, when she was 5 years old. Investigations revealed no vascular malformation or abnormality. On conservative treatment, she progressively improved and had residual hemiparesis. She continued to have intermittent episodes of generalized and focal convulsions. For persistent convulsions, she was investigated again with MRI and angiography after 5 years of first presentation. Investigations at this time revealed a large arteriovenous malformation in the left posterior frontal region. The arteriovenous malformation was resected by surgery. Following surgery, the episodes of convulsions reduced. Arteriovenous malformations are generally considered to be congenital lesions and their size and physical architecture generally remains constant. The presented case clearly demonstrated *de novo* appearance or growth of the size of the arteriovenous malformation. Such a pattern of development and growth of a arteriovenous malformation is rare and only infrequently reported.

**Key words:** Arteriovenous malformation, *de novo*, growth

## Introduction

Arteriovenous malformations are shunts between arteries and veins that form a nidus without any intervening capillary bed. Although a number of views have been put forth, the pathogenesis of arteriovenous malformations is largely unknown. Generally, arteriovenous malformations are considered to be congenital lesions that are present at the time of birth. The size, physical characters and nature of vascular feeders and draining vessels have been seen to remain essentially constant throughout life. We present a rare case of arteriovenous malformation in a female child which was not seen on the initial angiogram but formed over the years. Such a rare delayed formation and growth of the size of arteriovenous malformation probably challenges the hypothesis of origin secondary to embryonic dysgenesis.

## Case Report

A 12-year-old female child presented to us initially when she was 5 years old with an episode of generalized convulsion, loss

of consciousness and left sided hemiplegia. A non-contrast CT scan done at this time showed a right posterior frontal hematoma. CT angiography did not show any evidence of a vascular malformation. Digital subtraction angiography did not show any arteriovenous malformation, though an early draining vein was visualized [Figure 1]. The patient was managed conservatively. The patient presented 1 year after the episode. She had improved in power in her left sided limbs which was now Grade 3-4/5. She was able to walk on her own with little support. A MRI was performed that showed resolution of the hematoma and the presence of a gliotic cavity. A contrast image showed the normal vessels in the region, and there was no evidence of any flow voids in the region of the cavity. MR angiogram performed at the same time also did not show any evidence of an arteriovenous malformation or nidus [Figure 2]. The patient was again observed and asked to follow-up. The patient presented after 4 years, at the age of 9 years, with complaints of intermittent episodes of seizures. A MRI was again repeated which showed the gliotic cavity on T1 weighted scan. On T2 weighted image, some abnormal vessels were seen in the region of the gliotic cavity. MR angiography showed the presence of an arteriovenous malformation fed by the branches of the

Access this article online	
<b>Quick Response Code:</b> 	<b>Website:</b> <a href="http://www.asianjns.org">www.asianjns.org</a>
	<b>DOI:</b> 10.4103/1793-5482.145150

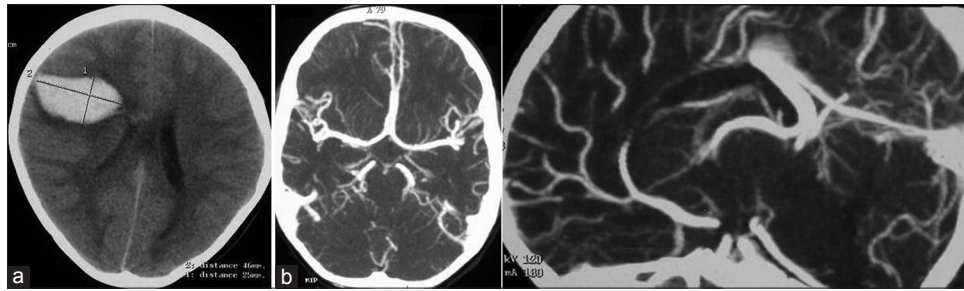
### Address for correspondence:

Prof. Atul Goel, Department of Neurosurgery, K.E.M Hospital and Seth G.S. Medical College, Parel, Mumbai - 400 012, Maharashtra, India.  
E-mail: atulgoel62@hotmail.com

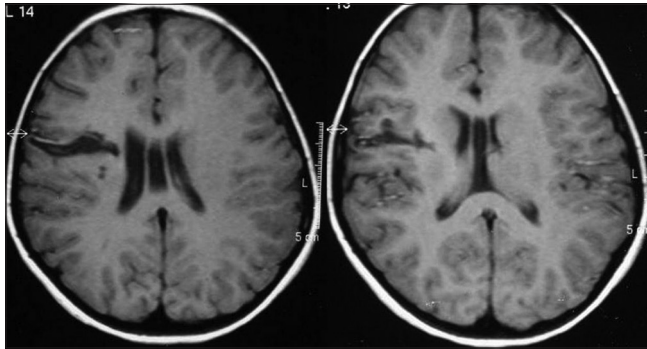
This is an open access article distributed under the terms of the Creative Commons Attribution-NonCommercial-ShareAlike 3.0 License, which allows others to remix, tweak, and build upon the work non-commercially, as long as the author is credited and the new creations are licensed under the identical terms.

**For reprints contact:** [reprints@medknow.com](mailto:reprints@medknow.com)

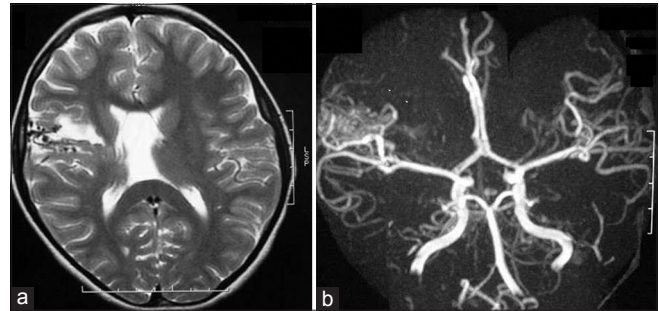
**How to cite this article:** Shah A, Patni N, Ramdasi R, Goel A. Progression in size of an arterio-venous malformation. *Asian J Neurosurg* 2017;12:207-10.



**Figure 1:** Investigations at the age of 5 years (a) CT scan showed a relatively large intraparenchymal haematoma. No abnormal blood vessel was seen, (b) CT angiography does not show any arteriovenous malformation



**Figure 2:** Investigations at the age of 6 years, Plain and contrast enhanced MRI does not show any abnormal vessels or evidence of arteriovenous malformation



**Figure 3:** Investigations at the age of 9 years (a) MRI shows presence of multiple flow-voids in the posterior frontal region, (b) MR angiography shows the presence of arteriovenous malformation in the posterior frontal region fed by branches of middle cerebral artery

middle cerebral artery [Figure 3]. A four vessel angiogram was performed which showed an arteriovenous malformation fed by multiple anterior branches of the middle cerebral artery and drained via multiple veins in the superior sagittal sinus. The patient was advised surgery at this time, but since she only had intermittent episodes of seizures the parents were not willing for surgery. One year after this the patient again presented with complaints of intractable seizures. Digital subtraction angiography showed the arteriovenous malformation, similar in size and configuration as was seen earlier [Figure 4]. The patient was now operated. The arteriovenous malformation was resected with routine surgical steps and considerations. The arteriovenous malformation was of significantly high-flow, but could be safely dissected and resected. Post-operatively the patient did well and she did not have any added neurological deficit. Post-operative angiogram showed excision of the arteriovenous malformation. At a follow-up after 1 year of surgery, she was well and was free from convulsions. Her hemiparesis persisted.

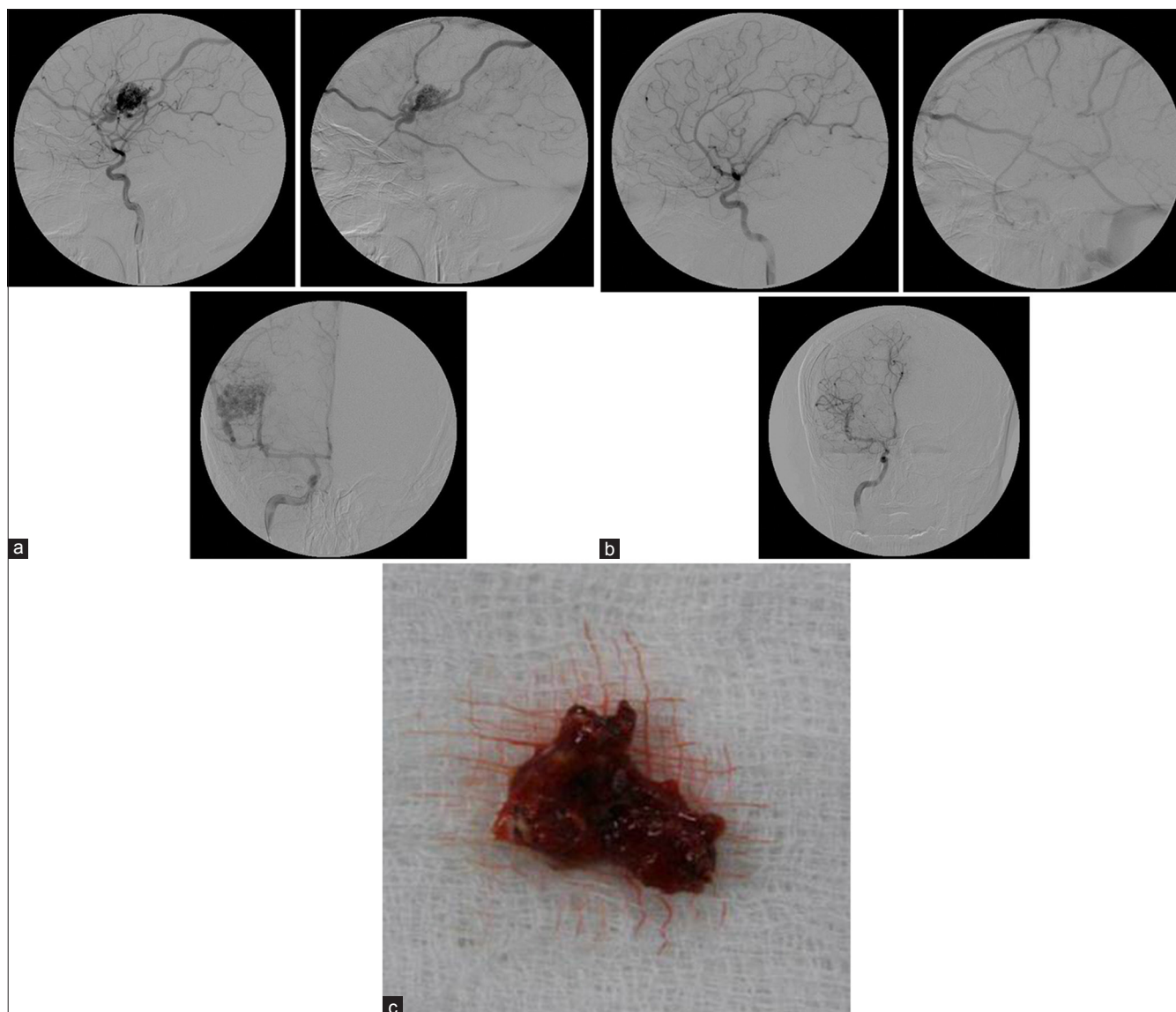
## Discussion

Arteriovenous malformations are thought to be congenital lesions that develop due to abnormal development or failure of normal maturation of primitive vascular channels. Though arteriovenous malformations have been thought to have a congenital origin, there have not been any antenatal or neonatal

reports of these vascular abnormalities.<sup>[1]</sup> Embryologically, in the 4<sup>th</sup> week of intrauterine life, the primordial vascular plexus within the embryonic brain differentiates into arterial, venous and capillary components.<sup>[2]</sup> Arteriovenous malformations result from abnormal persistence of direct arteriovenous connections without an intervening capillary bed. Symptomatic arteriovenous malformations are more commonly seen in adults around the 3<sup>rd</sup> or 4<sup>th</sup> decade of life.<sup>[3]</sup> Conversely very few reports of *de novo* arteriovenous malformations have been documented.<sup>[1,3-8]</sup> Hence the origin of these lesions is largely conjectural. Many authors believe that they are not static congenital lesions but have the ability to grow, regress, disappear and even reappear after total surgical excision or radiosurgery.

Many theories have been proposed to explain the growth of arteriovenous malformation's such as hemodynamic stresses causing gradual dilatation of congenitally formed abnormal vessels, increase mediated by growth factors, a decrease in supporting brain tissue due to multiple silent hemorrhages or a reserve nidus which becomes visible after a change in hemodynamics.

Abnormalities in the venous drainage are thought to play a large role in the pathogenesis of arteriovenous malformations. There is increasing evidence to suggest that postnatal cerebral vessels have angiogenic capacity. The role of venous hypertension in the genesis of arteriovenous malformations is largely speculative. Venous hypertension by increasing



**Figure 4:** (a) DSA shows the arteriovenous malformation, (b) Postoperative angiography showed resection of the arteriovenous malformation, (c) Photograph showing the specimen of resected arteriovenous malformation

intraluminal pressure leads to tissue hypoxia due to decreased perfusion. The hypoxia causes release of angiogenic factors which can cause development and growth of the arteriovenous malformation. The resulting venous hypertension may also open pre-existing vascular channels that can result in the appearance of a full blown arteriovenous malformation.

Failure to identify arteriovenous malformations on initial angiography is well-known. Initial failure of angiography to detect an arteriovenous malformation may be due to the small size of the arteriovenous malformation, occlusion/thrombosis of the arteriovenous malformation due to pressure from the hematoma, and vessel spasm or regressive changes of the vessel wall.<sup>[9]</sup>

In our patient two scenarios can probably explain the development of the arteriovenous malformation. One

possibility is that the arteriovenous malformation was small and got thrombosed or obliterated by pressure of the hematoma and hence was not detectable on initial angiography. This view is supported by the presence of early draining veins that matched in location and to an extent in size to the subsequently seen draining veins of arteriovenous malformation. The other possibility is that the arteriovenous malformation developed *de novo*. This possibility is supported by the fact that follow-up MRI and MRA did not show any evidence of abnormal flow voids in the gliotic bed. The sequence of events that probably occurred was related to a combination of both the possibilities.

Fuse *et al.* reported a similar case which was angiographically occult but later was found to have grown on MRI. They postulated that hemodynamic stresses led to growth of the arteriovenous malformation. A few cases of *de novo*

arterio-venous malformations have been reported.<sup>[9]</sup> Spetzler *et al.* reported a case of an arteriovenous malformation which was detected in a girl with intractable epilepsy following trauma.<sup>[3]</sup> Akimoto *et al.* reported a patient who developed a symptomatic corpus callosal *de novo* arteriovenous malformation 17 years after resection of prior splenial and occipital arteriovenous malformations.<sup>[5]</sup> They recommend a long term follow-up with MRI for patients who have undergone resection of an arteriovenous malformation in childhood. *De novo* arteriovenous malformation formation has also been seen in a patient who was operated for a giant cavernous malformation with a developmental venous anomaly.<sup>[4]</sup> A two-hit hypothesis has been proposed by some authors for development of a full-blown arteriovenous malformation, where the first hit is genetic and the second hit maybe acquired post-natally. The nature of the second hit is not always clear and environmental factors have been postulated to play a role. Mullan *et al.* proposed that cerebral arteriovenous malformations are lesions which were already present at birth but were mostly undetectable but had a postnatal growth potential presenting as full-blown arteriovenous malformations a little later in life.<sup>[10]</sup> Stevens *et al.* reported a *de novo* arteriovenous malformation in a patient with a neuronal migrational disorder. The authors point out that the concepts of pathogenesis of arteriovenous malformation focus on the temporal vulnerability of susceptible vascular elements to a physiologic trigger. This trigger may be hormonal, thrombotic, hypoxic, mechanical, hemodynamic or inflammatory in nature.<sup>[8]</sup>

## Conclusions

Arteriovenous malformations may not always be congenital lesions. Their natural history is probably dynamic. A long term follow-up is essential especially in children.

## Financial support and sponsorship

Nil.

## Conflicts of interest

There are no conflicts of interest.

## References

1. Bulsara KR, Alexander MJ, Villavicencio AT, Graffagnino C. De Novo cerebral arteriovenous malformation: Case report. *Neurosurgery* 2002;50:1137-41.
2. Friedman JA, Pollock BE, Nichols DA. Development of a cerebral arteriovenous malformation documented in an adult by serial angiography: Case report. *J Neurosurg* 2000;93:1058-61.
3. Gonzalez LF, Bristol RE, Porter RW, Spetzler RF. De novo presentation of an arteriovenous malformation. Case report and review of the literature. *J Neurosurg* 2005;102:726-9.
4. Alvarez H, Perry V, Solle M, Castillo M. De novo cerebral arteriovenous malformation in a child with previous cavernous malformation and developmental venous anomaly Case report. *J Neurosurg Pediatrics* 2012;9:327-30.
5. Akimoto H, Komatsu K, Kubota Y. Symptomatic de novo arteriovenous malformation appearing 17 years after the resection of two other arteriovenous malformations in childhood. Case report. *Neurosurgery* 2003;52:228-32.
6. Mahajan A, Manchandia TC, Gould G, Bulsara KR. De novo arteriovenous malformations: Case report and review of the literature. *Neurosurg Rev* 2010;33:115-9.
7. O'Shaughnessy BA, DiPatri AJ Jr, Parkinson RJ, Batjer HH. Development of a de novo cerebral arteriovenous malformation in a child with sickle cell disease and moyamoya arteriopathy. Case report. *J Neurosurg* 2005;102 Suppl 2:238-43.
8. Stevens J, Leach JL, Abruzzo T, Jones BV. De Novo cerebral arteriovenous malformation: Case report and literature review *AJNR Am J Neuroradiol* 2009;30:111-2.
9. Fuse T, Niwa Y, Umezu M, Yamada K. Growth of occult arteriovenous malformation after cerebral hemorrhage demonstrated by serial magnetic resonance imaging. Case Report. *Neurol Med Chir (Tokyo)* 2001;41:83-6.
10. Mullan S, Mojtahedi S, Johnson DL, Macdonald RL. Cerebral venous malformation-arteriovenous malformation transition forms. *J Neurosurg* 1996;85:9-13.