

## CASE REPORT

# Osteoblastic meningioma with turtle shell: Different entity from calcified meningioma

Pravin Salunke, Ashish Aggarwal, Sameer Futane, Ritambhara Nada<sup>1</sup>, Debasis Gochhait<sup>1</sup>

Departments of Neurosurgery, <sup>1</sup>Histopathology, PGIMER, Chandigarh, India

## ABSTRACT

Bone formation within meningioma is secondary to metaplasia of the meningotheial cells into osteoblastic cells. This needs to be differentiated from the commonly seen calcification. We describe a rare case of osteoblastic meningioma in which bony trabeculae were seen within meningotheial cells.

**Key words:** Metaplastic meningioma, osteoblastic meningioma

## Introduction

Osseous tissue is seen in various tumors such as choroid plexus papilloma, gliomas, and pituitary adenoma.<sup>[1]</sup> Presence of bone in meningiomas has been occasionally described and is considered a part of metaplasia that needs to be differentiated from the commonly encountered calcification.<sup>[1-3]</sup> The bone in meningiomas may vary from mature trabeculated to immature one.<sup>[1]</sup> Besides this, meningiomas with mature bone formation need to be differentiated from hyperostosis of adjacent skull bone, intra-osseous meningioma, periosteal osteoblastoma, and most importantly from calcified meningiomas. We describe a case of anterior parasagittal meningioma with an “ossified” shell.

## Case Report

A 47-year-old lady presented with seizures and progressively worsening headache for 1 year. Computerized tomography (CT) scan showed an anterior one-third parasagittal extraxial dural-based lesion with circumferential hyper-densities [Figure 1]. Intra-operatively, the overlying bone was normal, although hyperostosis was apparent on imaging. The tumor was well demarcated, vascular, and rubbery with bony spicules interspersed. There were thin layers of

bone within tumor tissue, especially at the periphery and it appeared as if the “bone chips from the calvaria had broken and were embedded within the meningioma”. Histopathology showed two distinct areas. One area showed tumor cells containing abundant eosinophilic cytoplasm with oval nuclei and inconspicuous nucleoli forming whorls and small syncytia. The other area showed mature trabeculated osteoid tissue [Figure 2]. The patient is doing well at 1-year follow-up.

## Discussion

Mesenchymal differentiation in the form of osseous, lipomatous, or cartilaginous tissue may be demonstrated occasionally in meningiomas.<sup>[1]</sup> Meningiomas with bony spicules or osseous differentiation have been named as osteoblastic or osteomatous meningiomas and these are regarded as metaplastic meningiomas.<sup>[1-3]</sup> These constitute about 1% of all meningiomas and are usually seen over the cerebral convexities or sylvian fissure. Rarely, spinal or intra-ventricular location has been described.<sup>[2,4]</sup> The hard consistency may make resection from vital structures difficult and the rarity makes it difficult to determine the biological behavior of these tumors.<sup>[1]</sup>

Bone formation needs to be differentiated from the calcification, which is commonly seen in the psammomatous variety, although it has been suggested that calcified meningiomas are the precursor lesions to ossified meningioma.<sup>[1,2]</sup> This new bone formation within the tumor tissue is intriguing. The basic cell of origin of meningioma is neural crest cell that is also responsible for skull bones. It is speculated that meningioma cells undergo metaplasia to form osteoblasts giving rise to osteomatous changes in the tumor. A strong enzyme reaction of alkaline phosphatase has been noticed in all cells comprising a meningotheial meningiomas and the cells around the psammoma bodies in the other variety.<sup>[5]</sup> Bone morphogenetic protein-2, a cytokine involved

### Access this article online

#### Quick Response Code:



#### Website:

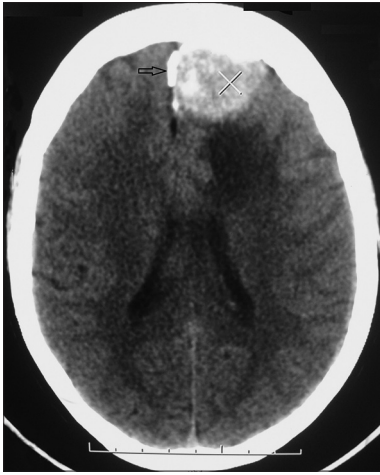www.asianjns.org

#### DOI:

10.4103/1793-5482.145151

### Address for correspondence:

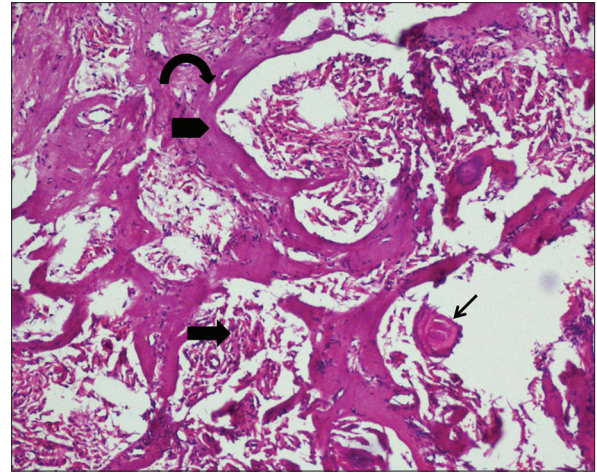
Dr. Pravin Salunke, Department of Neurosurgery, PGIMER, Chandigarh - 160 012, India. E-mail: drpravin\_salunke@yahoo.co.uk



**Figure 1:** Non contrast computed tomogram head axial image showing a left anterior third parasagittal meningioma with turtle shell-like hyper-density (open arrow). There are hyper-dense areas within the tumor too

in osteogenesis, was expressed in ossified meningiomas of psammomatous variety.<sup>[4]</sup> However, immunochemical studies have suggested two different pathways for bone formation.<sup>[1]</sup> In most cases bone tissue arises in tumors with calcification or psammoma bodies. The bone seen in these cases is mature one as confirmed by presence of osteocalcin expression, a marker for terminal osteoblastic differentiation involved in bone maturation.<sup>[1]</sup> The remaining few cases show immature bony trabeculae with interspersed mineralizing chondroid matrix suggesting enchondral ossification. These cases were characterized by the absence of psammoma bodies (metaplastic mechanism) and expressed osteopontin, a marker of early bone formation and usually seen on precursor osteoblast cells and osteoblasts.<sup>[1]</sup> Although the ossification suggests metaplasia, osteoblastic meningiomas are considered to be grade-1 as most of the cases described in the past have shown a good outcome.

In the above case the areas containing psammoma bodies did not show any trabecular bone formation. The area with bone formation was distinct from the psammomatous areas,



**Figure 2:** Hematoxylin and eosin (H and E) (x20) sections showing meningothelial cells in syncytia (block thick arrow) formation with psammoma bodies (marked by a thin arrow). Distinct areas of mature bony trabeculae (arrowhead) are visible. Osteocytes are seen within lacunae in these bony trabeculae (curved arrow)

thus suggesting a direct metaplastic transformation of the meningioma cells to osteoblastic cells.

## References

1. Barresi V, Caffo M, Ieni A, Alafaci C, Tuccari G. Osteoblastic meningiomas: Clinico-pathological and immunohistochemical features of an uncommon variant. *J Neurooncol* 2011;105:225-32.
2. Alafaci C, Salpietro FM, Grasso G, Montemagno G, Lucerna S, Matalone D, *et al.* Osteoblastic meningioma of the lateral ventricle. Case illustration. *J Neurosurg* 1999;91:1058.
3. Huang J, Petersson F. Intracerebral metaplastic meningioma with prominent ossification and extensive calcification. *Rare Tumors* 2011;3:e20.
4. Uchida K, Nakajima H, Yayama T, Sato R, Kobayashi S, Mwaka ES, *et al.* Immunohistochemical findings of multiple ossified en plaque meningiomas in the thoracic spine. *J Clin Neurosci* 2009;16:1660-2.
5. Pepler WJ. Alkaline phosphatase in the meninges and in meningiomas. *Nature* 1960;186:979.

**How to cite this article:** Salunke P, Aggarwal A, Futane S, Nada R, Gochhait D. Osteoblastic meningioma with turtle shell: Different entity from calcified meningioma. *Asian J Neurosurg* 2016;11:450-1.

**Source of Support:** Nil, **Conflict of Interest:** None declared.