

## CASE REPORT

# Solitary fibrous tumor of the sellar region treated with adjuvant radiation therapy

Puja Sahai, Geetika Singh<sup>1</sup>, Dodul Mondal, Vaishali Suri<sup>1</sup>, Pramod Kumar Julka

Department of Radiation Oncology, <sup>1</sup>Department of Pathology, All India Institute of Medical Sciences, New Delhi, India

## ABSTRACT

The solitary fibrous tumor of central nervous system is rare. Herein, a case of solitary fibrous tumor arising from sellar region is described. A 60-year-old man underwent subtotal excision of the tumor because of extensive infiltration of optical and vascular structures. In view of the presence of residual tumor, he was treated with adjuvant radiation therapy. After a follow-up period of 1 year, there was no progression of the lesion evident on magnetic resonance imaging of the brain. Solitary fibrous tumor should be considered as one of the differential diagnosis of a mass lesion arising in sellar region. Immunohistochemistry with CD34 is valuable for discerning the diagnosis. Complete surgery should be the goal of treatment and adjuvant radiation therapy may be considered for residual or recurrent disease.

**Key words:** Adjuvant radiotherapy, intracranial neoplasms, sella turcica, solitary fibrous tumor.

## Introduction

The solitary fibrous tumor (SFT) of central nervous system is rare. It is recently being reported more frequently because of effective diagnostic pathological and radiological modalities. The presentation of SFTs is in adults between the fourth and seventh decades. Herein, a case of SFT arising from sellar region is described. This is a fifth case of sellar SFT being reported to our knowledge.

## Case Report

A 60-year-old man presented with a 5-month history of progressive diminution of vision in both eyes. His visual examination showed bilateral temporal hemianopia. He did not have any neurological deficit. Considering the clinical picture, magnetic resonance imaging (MRI) of the brain was performed. It revealed an intensely enhancing lesion measuring  $3.0 \times 2.5 \times 2.0$  cm in the sellar and suprasellar region seen

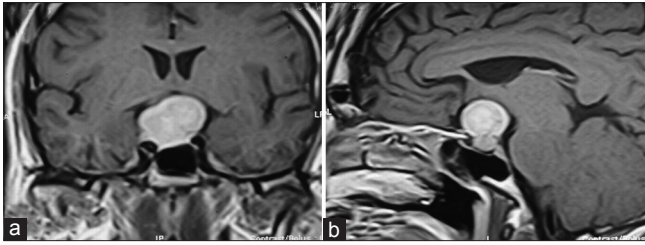
inseparable from pituitary with indentation on optic chiasma [Figure 1]. The lesion appeared isointense on T1- and T2-weighted images (T1WI and T2WI). It was seen encasing right internal carotid artery; however, the flow voids in bilateral internal carotid arteries appeared normal. His endocrine profile parameters were as follows: serum T3 = 2.06 pg/ml (normal range, 2.30-4.20), serum T4 = 1.24 ng/dl (0.70-1.51), serum TSH = 0.15 IU/ml (0.35-5.50), and serum Prolactin = 9.53 ng/ml (2.10-17.70). Excision of the sellar tumor was attempted through endonasal trans-sphenoidal approach. There was excessive bleeding during the procedure and thus only biopsy could be taken. The examination of frozen section of the biopsy revealed features of meningioma. Two days later, he underwent right pterional craniotomy. During the operative period, dura was seen densely adherent to the bone and a tumor was visualized arising from sella extending to suprasellar region and interpenduncular fossa. The consistency of the tumor was fibrous. It was seen adherent to optic chiasma and both optic nerves with encasement of right internal carotid artery. Hence, nearly 50-60% of tumor decompression could be achieved. A post-operative computed tomography (CT) scan of the brain was performed. It showed a residual mass lesion in the sellar region.

Histopathological examination of the resected specimen showed a cellular spindle cell tumor with the cells arranged in short intersecting fascicles displaying mild pleomorphism [Figure 2]. Further microscopic examination showed focal collagenization, “staghorn” blood vessels and an occasional mitotic figure. No whorling of tumor cells or psammoma bodies were noted. On immunohistochemistry, tumor cells showed diffuse positivity for CD34, MIC2, vimentin and focal positivity

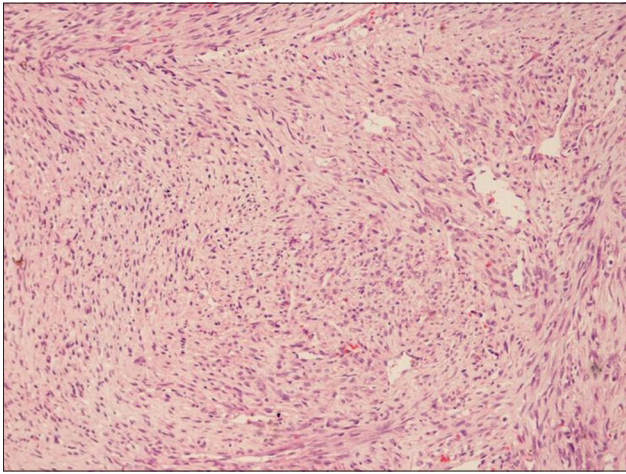
Access this article online	
Quick Response Code:	Website: www.asianjns.org
	DOI: 10.4103/1793-5482.145186

### Address for correspondence:

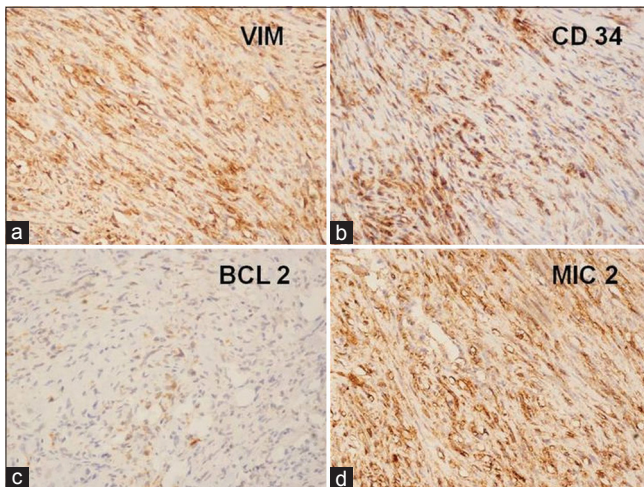
Dr. Puja Sahai, Department of Radiation Oncology,  
Dr. B.R. Ambedkar Institute Rotary Cancer Hospital, All India  
Institute of Medical Sciences, Ansari Nagar, New Delhi - 110 029,  
India. E-mail: pujarpi7@gmail.com



**Figure 1:** Coronal (a) and sagittal (b) T1-weighted MRI images of brain show an intensely enhancing lesion in the sellar and suprasellar region



**Figure 2:** Hematoxylin and eosin-stained section shows a tumor composed of intersecting fascicles of spindle-shaped cells with intervening areas of collagenization (x10)



**Figure 3:** Immunohistochemical panel shows diffuse cytoplasmic reactivity for vimentin (a, x20); CD34 (b, x20); and MIC2 (d, x20) with focal reactivity for BCL 2 (c, x20)

for BCL2 [Figure 3]. Based on the aforementioned findings, a pathological diagnosis of SFT was made. The tumor showed an MIB-1 labeling index of 5%.

After the surgery, his visual examination showed improvement in the right eye vision. MRI of the brain was performed after 5 weeks of the surgery. It showed an enhancing lesion of

2.6 × 2.5 × 2.0 cm dimension in the sellar region. In view of the presence of residual tumor, post-operative radiotherapy was planned for the patient. Consequently, a dose of 50 Gy in 25 fractions over 5 weeks was delivered. The three-dimensional conformal radiation therapy (3-DCRT) technique using 6 MV X-rays was employed for the treatment. After a follow-up period of 1 year, there was no progression of the lesion evident on MRI of brain. In addition, he had improvement in bilateral vision.

## Discussion

The SFTs are solitary, localized, firm and benign mesenchymal tumors. They may originate from perivascular connective tissue, the pia-arachnoid or dural fibrocytes. The important histological characteristics<sup>[1]</sup> are alternating hypercellular and hypocellular sclerotic foci with short, spindle or ovoid cells in a haphazard, storiform or fascicular arrangement. There is close intertwining of thin or thick collagen fibrils with the spindle cells. Immunohistochemical studies reveal strong diffuse positivity for vimentin and CD34.<sup>[2]</sup> Dural-based SFT may mimic fibrous meningioma and should be differentiated from the same.<sup>[3]</sup> The SFT is negative for EMA, S100 and muscle markers. In addition, the staining for p53, MIB-1 and cyclin D1 may be of interest in assessing the biological potential of this tumor.<sup>[4]</sup> On MRI scan, the SFT is visualised as isointense to adjacent brain on T1WI and iso- or hyperintense on T2WI with homogenous enhancement.<sup>[5,6]</sup> With regard to the present case study, the tumor showed isointensity on T1WI and T2WI with enhancement.

Bisceglia *et al*<sup>[7]</sup> reviewed the world literature on SFTs of the central nervous system from August 1996 to July 2011. The clinico-pathological features were assessed. The anatomical distribution of the reported 220 cases revealed that the majority of tumors were intracranial, and just over one-fifth were intraspinal. The sites of involvement were as follows in decreasing frequency: supratentorial and infratentorial compartments, ponto-cerebellar angle, sellar and parasellar regions, and cranial nerves. Although most SFTs of the central nervous system were dural based, a small subset presented in subpial, intraparenchymal, or intraventricular location. Some tumors involved the nerve rootlets with no dural connection. Immunohistochemistry clinched the diagnosis, distinguishing the tumor from meningioma, schwannoma, neurofibroma, or hemangiopericytoma. The MIB-1 labeling index proved to be of prognostic significance.

Although SFT is a benign tumor, metastases and recurrences have been reported. In the case series of SFT published by Chen *et al.*,<sup>[8]</sup> the patients treated with subtotal tumor resection (STR) experienced tumor recurrence or progression. However, the patients treated with adjuvant radiosurgery after STR did not recur or progress. The optimal treatment of SFT is complete surgical excision, which was not possible in the present case

because of extensive tumor infiltration of optical and vascular structures. Since the patient had residual tumor, adjuvant radiation therapy was given. He did not show any evidence of tumor progression on the imaging performed after one year of therapy.

SFT should be considered as one of the differential diagnosis of a mass lesion arising in sellar region. Immunohistochemistry with CD34 is valuable for discerning the diagnosis. Complete surgery should be the goal of treatment and adjuvant radiation therapy may be employed for residual or recurrent disease.

## References

1. Chan JK. Solitary fibrous tumour—everywhere, and a diagnosis in vogue. *Histopathology* 1997;31:568-76.
2. Prayson RA, McMahon JT, Barnett GH. Solitary fibrous tumor of the meninges. Case report and review of the literature. *J Neurosurg* 1997;86:1049-52.
3. Martin AJ, Fisher C, Igbasimokumo U, Jarosz JM, Dean AF. Solitary fibrous tumours of the meninges: Case series and literature review. *J Neurooncol* 2001;54:57-69.
4. Cassarino DS, Auerbach A, Rushing EJ. Widely invasive solitary fibrous tumor of the sphenoid sinus, cavernous sinus, and pituitary fossa. *Ann Diagn Pathol* 2003;17:169-73.
5. Brunori A, Cerasoli S, Donati R, Giangaspero F, Chiappetta F. Solitary fibrous tumor of the meninges: Two new cases and review of the literature. *Surg Neurol* 1999;51:636-40.
6. Challa VR, Kilpatrick SE, Ricci P, Wilson JA, Kelly DL Jr. Solitary fibrous tumor of the meninges. *Clin Neuropathol* 1998;17:73-8.
7. Bisceglia M, Gialliani C, Giannatempo G, et al. Solitary fibrous tumor of the central nervous system: a 15-year literature survey of 220 cases (August 1996-July 2011). *Adv Anat Pathol* 2011;18:356-92.
8. Chen H, Zeng XW, Wu JS, Dou YF, Wang Y, Zhong P, *et al.* Solitary fibrous tumor of the central nervous system: a clinicopathologic study of 24 cases. *Acta Neurochir* 2012;154:237-48.

**How to cite this article:** Sahai P, Singh G, Mondal D, Suri V, Julka PK. Solitary fibrous tumor of the sellar region treated with adjuvant radiation therapy. *Asian J Neurosurg* 2016;11:449.

**Source of Support:** Nil, **Conflict of Interest:** None declared.