

## CASE REPORT

# Calvarial tubercular osteomyelitic abscess in an elderly

Bhavanam Hanuma Srinivas, Megha Shantveer Uppin<sup>1</sup>, Sateesh Killi<sup>2</sup>,  
Malladi Venkata Surya Subbalaxmi<sup>2</sup>, Madhusudan Patil<sup>3</sup>, Alugolu Rajesh

Departments of Neurosurgery, <sup>1</sup>Pathology, <sup>2</sup>General Medicine, <sup>3</sup>Microbiology, Nizam's Institute of Medical Sciences, Punjagutta, Hyderabad, Andhra Pradesh, India

## ABSTRACT

Tuberculous osteomyelitis of skull is very rare, even in areas where tuberculosis is endemic. We herein describe an elderly woman who was apparently immunocompetent and presented with left frontal scalp swelling and right cervical lymphadenopathy. CT scan showed irregular bony destruction of the frontal bone. MRI revealed a large extradural, multiseptate, solid-cystic lesion with peripheral enhancement. FNAC from the lesion showed granulomas with caseation suggestive of tuberculosis. The lesion was debrided and she was started on anti-tubercular therapy. Deterioration of liver parameters led to change from primary drugs to liver-friendly, anti-tubercular agents. Though anti-tubercular therapy is the mainstay of calvarial tuberculosis, surgical debridement reduces the bacterial burden and probably hastens recovery.

**Key words:** Abscess, calvarium, osteomyelitis, scalp, tuberculosis

## Introduction

Osseous involvement by tuberculosis is usually secondary to hematogenous seeding, but can occur by lymphatic or contiguous local spread. It has a predilection for metaphysis of long bones, cancellous bones, or articular cartilages with relative sparing of flat bones like ribs, scapula, pubis and calvarium. Calvarial tuberculosis occurs in 0.2 to 1.3% of all types of skeletal tuberculosis.<sup>[1]</sup> The reasons for delayed presentation of such grossly visible and apparent lesions could well be attributed to the initial painless nature of the lesion and absence of systemic symptoms apart from cosmesis. We herein report a case of calvarial tuberculosis in an elderly immunocompetent woman.

## Case Report

A 74-year-old female presented to the outpatient department of neurosurgery with painless, gradually progressive scalp

swelling over left frontal region and weight loss for past 1 month. There was no history of trauma or fever. On examination, she was emaciated and had a 6 × 4 cm solitary, tender, soft to firm, fluctuant, non pulsatile swelling in the left frontal region. A 2 × 2 cm solitary lymph node in right posterior cervical region was noted. ESR was 64 mm at first hour. Mantoux was reactive with 18 mm at 72 hours. Chest radiograph was normal. Sputum for AFB was negative. Her immunological status was assessed by serology for HIV, serum albumin levels, fasting blood glucose (FBS), and glycosylated hemoglobin (Hb<sub>1c</sub>). HIV was nonreactive, serum albumin - 4 g/dl, FBS - 80 mg/dl, and Hb<sub>1c</sub> - 5%. She had uncontrolled hypertension with a systolic murmur and diastolic dysfunction. CT scan brain showed a bony defect in the left frontal region with soft tissue collection in left subfrontal region with irregular bony destruction [Figure 1]. MRI showed 6 × 4 × 4 cm lobular, heterogenous, multiseptated, mixed signal intensity extradural lesion with thick peripheral enhancement in left frontal bone [Figure 2]. The differential diagnosis included metastasis to the frontal bone, and intraosseous meningioma. Fine needle aspiration cytology (FNAC) of the scalp swelling was performed which on analysis showed epithelioid cell granulomas surrounded by lymphocytes with areas of caseous necrosis suggestive of tuberculosis [Figure 3]. Assuming it as a primarily medical disease, a non-surgical management was planned. The lesion was tapped with 20-gauge needle and around 50 cc of thin, straw-colored fluid was withdrawn; she was started on anti-tubercular treatment for attempted conservative treatment in view of uncontrolled hypertension and cardiac dysfunction. However, the fluid reaccumulated within 24 hours and the plan was changed in favor of surgical debridement under scalp block anesthesia,

### Access this article online

#### Quick Response Code:



#### Website:

www.asianjns.org

#### DOI:

10.4103/1793-5482.145334

### Address for correspondence:

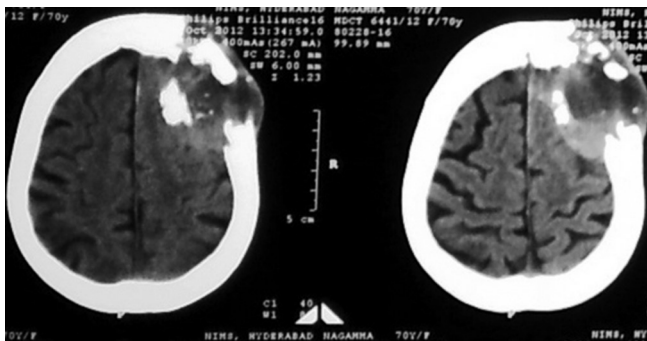
Dr. Malladi Venkata Surya Subbalaxmi,  
Department of General Medicine, Nizam's Institute of Medical Sciences,  
Punjagutta, Hyderabad - 500 082, Andhra Pradesh, India.  
E-mail: subbalaxmi@hotmail.com

with a left frontal curvilinear incision over the swelling. The bone margins were nibbled off and the lesion along with sequestrum cleared till the dura mater. The specimen was also sent for cultures (including aerobic, anaerobic, fungal, and TB culture). The Gram's staining showed plenty of polymorphs, with no organisms. The smear for Acid Fast Bacilli was negative both by Ziehl-Neelsen and fluorescent staining using Rhodamine- Auramine stains. Based on the histopathological report, the patient was started on anti-tubercular treatment from second postoperative day, which included isoniazid (5 mg/kg body weight/day), rifampicin (10 mg/kg body weight/day), pyrazinamide (30 mg/kg body weight/day), and ethambutol (15 mg/kg body weight/day). Patient was well for about a week's time when she developed vomiting and her liver function tests showed elevated serum alkaline phosphatase, SGOT, and SGPT. Anti-tubercular drugs were modified and she was started on Tab. Levofloxacin 500 mg, Ethambutol 600 mg, and Inj. streptomycin 750 mg daily. The patient improved with a well-healed scar and no swelling of the scalp. Culture for tuberculosis was positive after 6 weeks of incubation by radiometric BACTEC 460 TB system. After liver function tests returned to normal values, first line anti-tuberculosis drugs

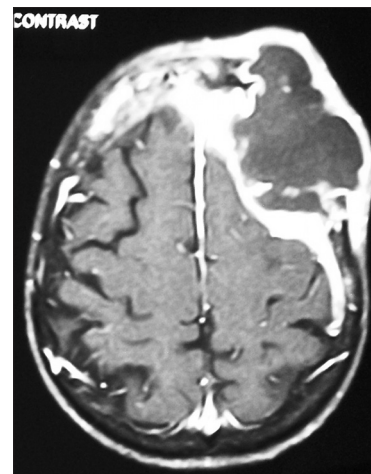
were reintroduced which were tolerated by the patient. The isolate was identified as *Mycobacterium tuberculosis* complex by NAP test (r-nitro-a-acetylamino-b-hydroxypropiophenone) and was sensitive to all first-line anti-tubercular drugs. At the end of one-year follow up, the patient was doing fine with no recurrence of the swelling. Imaging at 1 year following the institution of treatment showed calvarial defect on the left side, with a sunken skin flap. No lesion or abnormal enhancement was noted [Figure 4a-c].

## Discussion

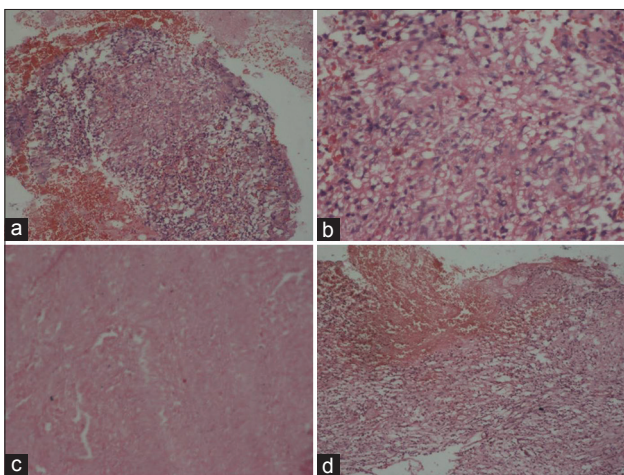
Tuberculosis poses a major health problem in developing countries. Skeletal tuberculosis accounts for 1% of tuberculous infection, but only 0.2 to 1.3% of these are estimated to suffer from calvarial tuberculosis.<sup>[1,2]</sup> The incidence of extra pulmonary TB is 70% in HIV-infected patients, as compared to 15% in non-infected patients.<sup>[3]</sup> The first case of calvarial



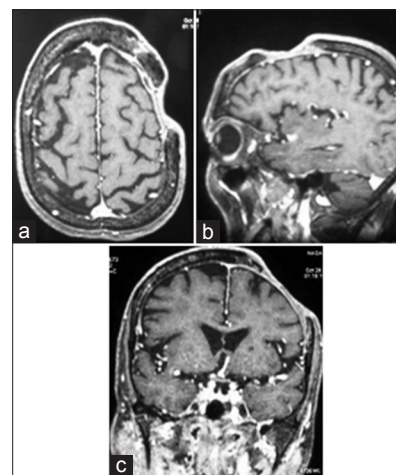
**Figure 1:** CT scan brain showed a bony defect in the left frontal region with soft tissue collection noted in left subfrontal region with irregular bony destruction



**Figure 2:** MRI showed 6 × 4 × 4 cm lobular, heterogenous multiseptated mixed signal intensity extradural lesion with thick peripheral enhancement in left frontal bone



**Figure 3:** (a) Presence of epithelioid cell granuloma surrounded by lymphocytes (b) the same granuloma on higher magnification. (c) Areas of caseous necrosis (d) Sparse lymphocytic infiltrate



**Figure 4:** MRI brain Gd - contrast imaging showing left frontal calvarial defect with no evidence of any lesion at 1 year following treatment (a - axial, b - sagittal, c - coronal views)

tuberculosis was reported in 1842 by Reid from Germany. Tubercular osteomyelitis is spread by hematogenous route from primary focus, usually lungs with other sources being lymph nodes.<sup>[4,5]</sup> Direct spread from face, paranasal sinuses, orbit, and nasal mucosa has also been reported in literature. In our case, cervical lymph nodes showed evidence of granulomas on fine needle biopsy; however, whether they were the primary source or were reactionary in the draining area of the scalp could not be ascertained.

Calvarial tuberculosis takes its origin with the deposition of tubercular bacilli in the diploic space during its hematogenous spread. Further course of events depend upon the critical balance between the virulence of bacteria and host immunity. A highly virulent bacterium in the presence of altered host immunity leads to proliferation of bacteria, granulation tissue/abscess formation with subsequent destruction of the bone. Involvement and destruction of the outer table is followed by relative resistant inner table and dura.<sup>[6]</sup> Trauma has also been implicated as an associative/causative factor for calvarial tuberculosis.

The calvarial tuberculosis is most common in young age with 50% of patients being less than 10 years, and 75 to 90% being younger than 20 years.<sup>[7]</sup> The most common presentation is painless, soft, fluctuant swelling over scalp with or without discharging sinus. As seen in our patient, occasionally patients may present with focal headache. Rarely, they may present with seizures and motor deficits. Frontal, parietal bones with large cancellous diploic spaces are the common sites as compared to temporal and sphenoid bones.<sup>[8]</sup> Dura mater generally acts as a strong barrier. However, intracranial spread of infection breaching the dura has also been reported in literature.

Radiologically, 3 types of calvarial tuberculosis are reported in literature: (1) Perforating tuberculosis of skull involving both inner and outer tables with granulation tissue covering either side; (2) Diffuse tuberculosis of skull characterized by wide-spread involvement in diploe with destruction of inner table of skull and epidural granulations in form of pachy meningitis externa; (3) Circumscribed sclerotic type characterized by marked thinning of bone because of lack of blood supply to diseased bone. The present case was a diffuse type of calvarial tuberculosis.

A raised erythrocyte sedimentation rate and positive Mantoux test may give a clue for diagnosis of tuberculosis. Mantoux may not be positive in 10% of calvarial tuberculosis patients. Plain radiographs of skull might be helpful in finding the bony changes though CT scan would be more useful in identifying

the extent of damage to skull bone, involvement and breach of dura, and size of the swelling. Differential diagnosis includes osteomyelitis, metastasis, eosinophilia granulomas, haemangiomas, and aneurysmal bone cyst. Demonstration of Acid Fast bacilli in pus smear by Ziehl-Neelsen stain and culture for *Mycobacterium tuberculosis* are diagnostic but may not be positive in all cases.<sup>[9]</sup> FNAC/FNAB are useful adjuncts for reaching a diagnosis.

The mainstay of treatment is surgical curettage to reduce the bulk of disease followed by antitubercular therapy for 12 months.<sup>[10,11]</sup> However, lesions without mass effect or involvement of sinuses can be managed with chemotherapy alone.

## Conclusion

Tubercular osteomyelitis of skull is very rare, even in countries with endemic tuberculosis. Delay in diagnosis is a rule for absent systemic symptoms and signs. Suspicion, early diagnosis (confirmative cultures or Cytology or histopathological evidence anti-tubercular chemotherapy with or without surgical debridement (depending upon the bacterial load) are the mainstay of treatment.

## References

1. LeRoux PD, Griffin GE, Marsh HT, Winn HR. Tuberculosis of the skull—A rare condition: Case report and review of the literature. *Neurosurgery* 1990;26:851-5.
2. Agarwal N, Jain SK. Tuberculous osteitis of skull: A case report. *Indian J Tub* 2002;49:105-6.
3. Mukherjee KK, Kaushik R, Nada R, Khosla VK, Khandelwal N. Calvarial tuberculosis. *Surg Neurol* 2002;57:195-203.
4. Mohanty S, Rao CJ, Mukherjee KC. Tuberculosis of the skull. *Int Surg* 1981;66:81-3.
5. Mishra SK, Nigam P. Tuberculosis of flat bones. *Indian J Chest Dis Allied Sci* 1984;26:174-6.
6. Malhotra R, Dinda AK, Bhan S. Tuberculous osteitis of the skull. *Indian Pediatr* 1993;30:1119-23.
7. Diyora B, Kumar R, Modgi R, Sharma A. Calvarial tuberculosis: A report of eleven patients. *Neurol India* 2009;57:607-12.
8. Meng CM, Wu YK. Tuberculosis of the flat bones of the vault of the skull. *J Bone Joint Surg* 1942;34:341-53.
9. Gupta PK, Kolluri VR, Chandramouli BA, Venkataramana NK, Das B. Calvarial tuberculosis: A report of two cases. *Neurosurgery* 1989;25:830-3.
10. Miles J, Hughes B. Tuberculosis osteitis of the skull. *Br J Surg* 1970;57:673-9.
11. Rajesh A, Purohit AK, Lakshmi V. Calvarial tubercular osteomyelitic abscess. *Indian J Med Microbiol* 2009;27:380-1.

**How to cite this article:** Srinivas BH, Uppin MS, Killi S, Subbalaxmi MV, Patil M, Rajesh A. Calvarial tubercular osteomyelitic abscess in an elderly. *Asian J Neurosurg* 2016;11:445.

**Source of Support:** Nil, **Conflict of Interest:** None declared.