

CASE REPORT

Papillary tumor of pineal region: A rare entity

Meena Patil, Manjiri Karandikar

Department of Pathology, B. V. D. U. Medical College, Pune, Maharashtra, India

ABSTRACT

Pineal tumors comprise 0.4 - 1.0% of intracranial space-occupying lesions in adults. Papillary tumor of pineal region (PTPR) is a very rare entity. It has been newly described in WHO 2007 classification of brain tumors. Only a few case reports are available in the literature. We report a case of a 60 year-old female presenting with headache, giddiness and reduced vision. Imaging studies showed a pineal mass with areas of hemorrhage. All ventricles were normal. There was a past history of a pineal gland tumor excised 2 years ago. This case is being reported for its rarity and aggressiveness in the form of recurrence. Limited/available immunohistochemistry workup has been done.

Key words: Intracranial space-occupying lesions, papillary tumor of pineal region, pineal region tumors, WHO classification of brain tumors

Introduction

Papillary tumor of pineal region (PTPR) arises exclusively in the pineal region and occurs most commonly in adults with slight preponderance in females. Headache of short duration is the common presenting symptom. This occurs due to increased intracranial tension as a result of compression of the aqueduct. Various other names, like papillary pineocytoma, pineal parenchymal tumor, choroid plexus tumor, ependymoma and papillary meningioma have been given to these tumors in earlier reports.^[1]

Case Report

A 60 year-old female presented with headache, giddiness and reduced vision in both eyes for 2 months. There was a past history of a pineal gland tumor compressing third ventricle and presenting with hydrocephalus, excised 2 years back. Histopathology of the previous resection for pineal gland tumor was not available, but patient had not taken any adjuvant therapy after surgery. Magnetic Resonance Imaging (MRI) brain showed a pineal mass 4 × 3.3 cm, with hemorrhage, and

hyperintensity on precontrast T1-weighted image. Ventricles were normal and there was a shunt *in situ* [Figure 1].

Histopathology revealed a cellular neoplasm characterized by eosinophilic cells with indistinct cell borders, with columnar and cuboidal morphology. They were arranged in perivascular pseudorosettes and in a distinctive papillary growth pattern. Blood vessels appeared to be covered by multiple layers of tumor cells with pleomorphic nuclei.

Immunohistochemistry (IHC) study showed strong reactivity for vimentin, S-100 protein, focal positivity for p53, and low MIB-1 index. Epithelial Membrane Antigen (EMA), CK 8-18, Glial Fibrillary Acidic Protein (GFAP), synaptophysin were negative.

A thorough retrospective search for any primary tumor outside the CNS was done and no tumor was found anywhere. In view of the past history of pineal gland tumor excision, a final diagnosis of PTPR-grade II was offered. Incomplete resection may be the cause of recurrence in our case as the mitotic index was less than one mitotic figure per 10 high-power fields. The case is being followed up for the last 2 years and does not have any symptoms related to the tumor.

Discussion

PTPR is a rare entity, newly described in WHO 2007 classification of brain tumors and assigned a provisional code (ICD-O code of 9395/3).^[1] In 2003, Jouvett and colleagues reported six cases and called it "Papillary Tumor of Pineal region." The tumor's clinicopathological characteristics as described and illustrated in that series were very similar to the description of some entities reported by neuropathologists from different parts of the world. Many more independent case reports were published after Jouvett *et al.*'s initial report.^[2] Till now, about 64 cases of PTPR have been reported.^[3]

Access this article online

Quick Response Code:



Website:

www.asianjns.org

DOI:

10.4103/1793-5482.145373

Address for correspondence:

Dr. Meena Patil, Flat No. 8, Surya Appt., Kohinoor Colony, Sahakarnagar No. 2, Pune, Maharashtra, India.
E-mail: meenipatil@yahoo.co.in

The WHO 2007 definition of PTPR is as follows: - “A rare neuroepithelial tumor of the pineal region in adults, characterized by papillary architecture and epithelial cytology, immunopositivity for cytokeratin and ultra structural features suggesting ependymal differentiation.”^[4]

They are well circumscribed and the size may vary from 2.5 to 4 cm. The age ranges from 5 to 66 years, while the mean age is 31.5 years.^[1] They may also have a cystic component. CT imaging shows their hypodense nature and enhancement with contrast. MRI demonstrates hypointensity in T1-weighted (T1W) sequence and hyperintensity in T2-weighted (T2W) sequence and enhance with contrast.^[5]

Symptoms are typically related to obstructive hydrocephalus secondary to compression of cerebral aqueduct. Progression occurs in almost 75% of patients. Incomplete resection and increased mitotic activity are negative prognostic factors.^[1]

Although the cell of origin is not definitely known, it is thought to be arising from the specialized ependymal cells of the subcommissural organ. The subcommissural organ present in animals, is present in the humans only during embryonic life and loses its function in adult life.^[1]

A lot of effort has been taken to decide the IHC profile of the tumor. The immunophenotype of PTPR has been extensively investigated. It shows immunoreactivity for a broad spectrum of cytokeratins, For example, KL1, AE1/AE3, and CAM5.2. Papillary areas are more consistently and strongly positive for CK18 than the solid areas.^[1] However some authors have reported negativity for CK, EMA, synaptophysin, and GFAP.^[6] PTPRs have also been reported to express vimentin, S-100 protein, Neuron specific enolase (NSE), Microtubule Associated Protein 2 (MAP2), Neural cell adhesion molecule (N-CAM) and transthyretin [Figure 2]. Reactivity for GFAP has been reported in approximately 12% of tumors, typically restricted to focal perivascular areas of the tumor. Surface EMA expression is seen in most cases. No immunolabeling for neurofilament proteins has been reported.^[1] In few cases, NSE and synaptophysin were reported positive.^[7] All pineal region lesions known to exhibit papillary architecture come in the differential diagnosis of PTPR. These include pineal parenchymal tumors, papillary ependymoma, choroid plexus tumors, papillary meningioma, and metastases. Strong immunoeexpression of neuronal markers help in differentiating PTPR from pineal parenchymal tumors. Very low or absent expression of CK7/CK20 and low MIB-1 labeling indices are characteristic of PTPR and differentiates it from metastatic papillary carcinomas of unknown primary [Figure 3]. Both PTPR and choroid plexus papilloma express cytokeratins and transthyretin; however most PTPRs show MAP-2 staining and do not express Kir7.1, which is a marker of choroid plexus tumors. General lack of cytokeratin expression, differentiates papillary meningioma from PTPR. Papillary tumors of pineal region are characterized by frequent local

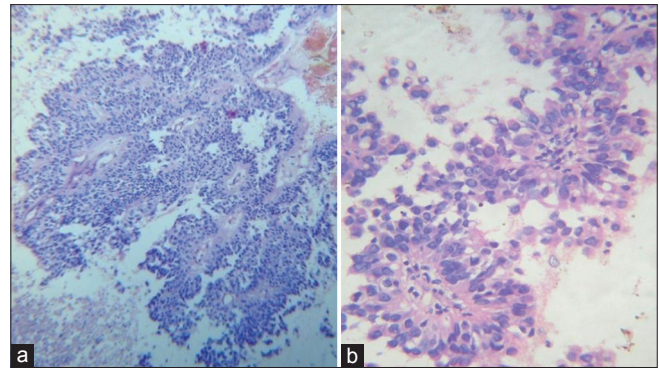


Figure 1: (a) PTPR- H and E $\times 100$ (b) PTPR- H and E $\times 400$

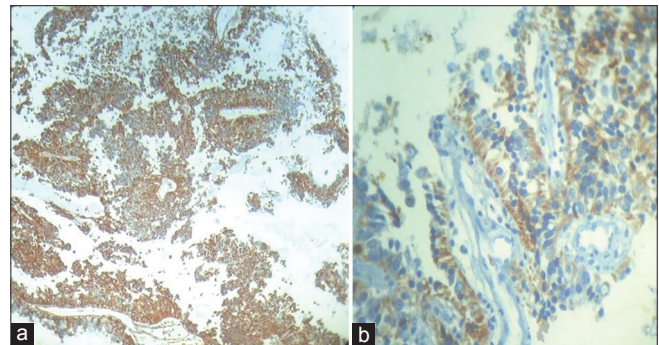


Figure 2: (a) PTPR- vimentin positive $\times 100$ (b) PTPR- S-100 protein positive $\times 400$

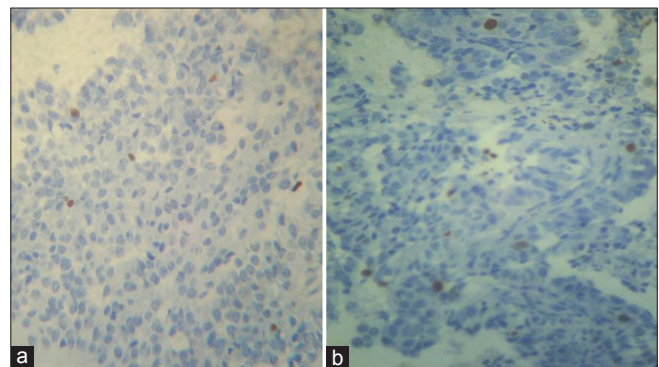


Figure 3: (a) PTPR- p53 focal positive $\times 400$ (b) PTPR- low MIB-1 index $\times 400$

recurrence, but only occasional spinal dissemination. Therefore, the WHO panel has put them in grades II or III category.^[1]

References

1. Roncaroli F, Scheithauer BW. Papillary tumor of pineal region: New tumor entity in the 2007 WHO classification. *Brain Pathol* 2007;17:314-8.
2. Jouvret A, Fauchon F, Liberski P, Saint-Pierre G, Didier-Bazes M, Heitzmann A, *et al.* Papillary Tumor of the Pineal Region. *Am J Surg Pathol* 2003;27:505-12.
3. Fuller GN. The increasing diversity of Pineal and Sellar region tumors, American Association Of Neuropathologists USCAP Companion Society Inaugural Meeting Denver, CO. 2008.
4. Kleihues P, Cavenee WK, editors. World Health Organization Classification of Tumors. Pathology and Genetics of Tumours of

Nervous System, No. 21. Geneva: World health Organization; 1979. Lyon: IARC Press; 2000.

5. Epari S, Bashyal R, Malick S, Gupta T, Movadi A, Kane SV, *et al.* Papillary tumor of pineal region: Report of three cases and review of literature. *Neurol India* 2011;59:455-60.
6. Kim YH, Kim JW, Park CK, Kim DG, Sohn CH, Chang KH, *et al.* Papillary tumor of pineal region presenting with leptomeningeal seeding. *Neuropathology* 2010;30:654-60.
7. Sharma MC, Jain D, Sarkar C, Suri V, Garg A, Sharma BS, *et al.*

Papillary tumour of the pineal region-a recently described entity: A report of three cases and review of the literature. *Clin Neuropathol* 2009;28:295-302.

How to cite this article: Patil M, Karandikar M. Papillary tumor of pineal region: A rare entity. *Asian J Neurosurg* 2016;11:453.

Source of Support: Nil, **Conflict of Interest:** None declared.